

## Evaluation of objective vitritis grading method using optical coherence tomography

Zarranz-Ventura, Javier; Keane, Pearse A; Sim, Dawn A; Llorens, Victor; Tufail, Adnan; Sadda, Srinivas R; Dick, Andrew D; Lee, Richard W; Pavesio, Carlos; Denniston, Alastair K; Adan, Alfredo; EQUATOR Study Group

DOI:  
[10.1016/j.ajo.2015.10.009](https://doi.org/10.1016/j.ajo.2015.10.009)

License:  
None: All rights reserved

*Document Version*  
Peer reviewed version

*Citation for published version (Harvard):*  
Zarranz-Ventura, J, Keane, PA, Sim, DA, Llorens, V, Tufail, A, Sadda, SR, Dick, AD, Lee, RW, Pavesio, C, Denniston, AK, Adan, A & EQUATOR Study Group 2016, 'Evaluation of objective vitritis grading method using optical coherence tomography: influence of phakic status and previous vitrectomy', *American Journal of Ophthalmology*, vol. 161, pp. 172–180.e4. <https://doi.org/10.1016/j.ajo.2015.10.009>

[Link to publication on Research at Birmingham portal](#)

**Publisher Rights Statement:**  
Eligibility for repository: Checked on 5/2/2016

### General rights

Unless a licence is specified above, all rights (including copyright and moral rights) in this document are retained by the authors and/or the copyright holders. The express permission of the copyright holder must be obtained for any use of this material other than for purposes permitted by law.

- Users may freely distribute the URL that is used to identify this publication.
- Users may download and/or print one copy of the publication from the University of Birmingham research portal for the purpose of private study or non-commercial research.
- User may use extracts from the document in line with the concept of 'fair dealing' under the Copyright, Designs and Patents Act 1988 (?)
- Users may not further distribute the material nor use it for the purposes of commercial gain.

Where a licence is displayed above, please note the terms and conditions of the licence govern your use of this document.

When citing, please reference the published version.

### Take down policy

While the University of Birmingham exercises care and attention in making items available there are rare occasions when an item has been uploaded in error or has been deemed to be commercially or otherwise sensitive.

If you believe that this is the case for this document, please contact [UBIRA@lists.bham.ac.uk](mailto:UBIRA@lists.bham.ac.uk) providing details and we will remove access to the work immediately and investigate.

Manuscript Number: AJO-15-786R2

Title: Evaluation of objective vitritis grading method using optical coherence tomography: influence of phakic status and previous vitrectomy

Article Type: Original Article

Keywords: uveitis; vitritis; vitreous inflammation; vitreous haze; intensity ratio; optical density ratio; optical coherence tomography; spectral domain; objective; measurement; phakic status; pars plana vitrectomy

Corresponding Author: Mr. Javier Zarranz-Ventura, MD PhD FEBO

Corresponding Author's Institution: Institut Clínic d'Oftalmologia (ICOF), Hospital Clínic Barcelona

First Author: Javier Zarranz-Ventura, MD PhD FEBO

Order of Authors: Javier Zarranz-Ventura, MD PhD FEBO; Pearse A Keane, MD FRCOphth; Dawn A Sim, MD FRCOphth; Victor Llorens, MD PhD; Adnan Tufail, MD FRCOphth; Srinivas R Sadda, MD; Andrew D Dick, MD FmedSci; Richard W Lee, MRCOphth PhD; Carlos Pavesio, MD FRCOphth; Alastair K Denniston, PhD FRCOphth; Alfredo Adan, MD PhD

## Abstract

**Purpose:** To evaluate a proposed method for objective measurement of vitreous inflammation using an spectral domain optical coherence tomography (SD-OCT) device in a large cohort of uveitis eyes, including pseudophakic eyes and vitrectomized eyes.

**Design:** Retrospective, observational, cohort study.

**Methods:** One-hundred five uveitis eyes (105 patients) with different vitreous haze score grades according to standardized protocols and corresponding SD-OCT images (Cirrus HD-OCT, Carl Zeiss Meditec) were included. Clinical data recorded included phakic status, previous vitreo-retinal surgery and anterior chamber (AC) cells and flare. SD-OCT images were analyzed using custom software which provided absolute measurements of vitreous (VIT) and retinal pigment epithelium (RPE) signal intensities, that were compared to generate a relative optical density ratio with arbitrary units (VIT/RPE-Relative intensity) and compared to VHS.

**Results:** VIT/RPE-relative intensity showed a significant positive correlation with vitreous haze score ( $r = 0.535$ ,  $p < 0.001$ ) that remained significant after adjusting for factors governing media clarity such as AC cells, AC flare and phakic status ( $R^2$ -adjusted = 0.424,  $p < 0.001$ ). Significant differences were also observed between the different vitreous haze score groups ( $p < 0.001$ ). Preliminary observation did not observe differences in VIT/RPE-relative intensity values between phakic and pseudophakic eyes (0.3522 vs 0.3577,  $p = 0.48$ ) and non-vitrectomized and vitrectomized eyes (0.3540 vs 0.3580,  $p = 0.52$ ) overall and respectively for each vitreous haze score subgroups.

**Conclusions:** VIT/RPE-relative intensity values provide objective measurements of vitreous inflammation employing an SD-OCT device. Phakic status and previous vitrectomy surgery do not appear to influence these values, although these preliminary findings need validation in future studies.

## Evaluation of objective vitritis grading method using optical coherence tomography: influence of phakic status and previous vitrectomy

Javier Zarranz-Ventura, MD PhD,<sup>1,2,3</sup> Pearse A. Keane, MD FRCOphth,<sup>2</sup> Dawn A. Sim, MD FRCOphth,<sup>2</sup> Victor Llorens, MD PhD,<sup>1</sup> Adnan Tufail, MD FRCOphth,<sup>2</sup> Srinivas R. Sadda, MD,<sup>4</sup> Andrew D. Dick, MD FmedSci,<sup>2,3</sup> Richard W. Lee, MRCOphth, PhD,<sup>2,3</sup> Carlos Pavesio, MD FRCOphth,<sup>2</sup> Alastair K. Denniston, PhD FRCOphth,<sup>5,6,7</sup> and Alfredo Adán, MD PhD<sup>1</sup> for the EQUATOR Study Group\*

<sup>1</sup>*Institut Clínic d'Oftalmologia, Hospital Clinic, Barcelona, Spain*

<sup>2</sup>*National Institute for Health Research Biomedical Research Centre for Ophthalmology, Moorfields Eye Hospital National Health Service Foundation Trust and University College London Institute of Ophthalmology, London, United Kingdom*

<sup>3</sup>*School of Clinical Sciences, Bristol Eye Hospital, University of Bristol, Bristol, United Kingdom*

<sup>4</sup>*Doheny Eye Institute, University of California Los Angeles, California, United States*

<sup>5</sup>*Queen Elizabeth Hospital Birmingham, University Hospitals Birmingham National Health Service Foundation Trust, Birmingham, United Kingdom*

<sup>6</sup>*Academic Unit of Ophthalmology, University of Birmingham, Birmingham, United Kingdom*

<sup>7</sup>*Birmingham & Midland Eye Centre, Sandwell and West Birmingham National Health Service Trust, Birmingham, United Kingdom*

\*Extended Optical Coherence Tomography-Quantification of Uveitis Activity for Trial Outcomes and Reporting (EQUATOR). For full list of contributing authors and affiliations of authors from the EQUATOR Consortium please see Appendix.

### Corresponding author and study coordinator:

Javier Zarranz-Ventura  
Institut Clínic d'Oftalmologia (ICOF), Hospital Clinic, Barcelona  
C/ Sabino Arana 1  
Barcelona, 08028  
Email: jzarranz@hotmail.com

### Short title:

Vitritis grading method using optical coherence tomography

### Keywords:

uveitis; vitritis; vitreous inflammation; vitreous haze; intensity ratio; optical density ratio; optical coherence tomography; spectral domain; objective; measurement; phakic status; pars plana vitrectomy.

- Supplemental material available at AJO.com: Supplemental Figures 1 and 2

## Introduction

The current method for assessment of the inflammatory status in eyes with uveitis is almost entirely based on subjective clinical estimates according to standardized scales for both anterior and posterior segment.<sup>1, 2</sup> In the case of vitreous inflammation, the gold standard has been the National Eye Institute system for grading of vitreous haze, often known as the Nussenblatt scale.<sup>2</sup> This classification is based on estimation of the clarity of the fundus when viewed with the indirect ophthalmoscope and a 20D lens in comparison to a set of reference photographs. The National Eye Institute vitreous haze score has been approved as a surrogate endpoint by the United States Food and Drug Administration and is used as a primary outcome measure in the majority of clinical trials in uveitis. Vitreous haze score does, however, have a number of limitations: it is subjective, with only moderate interobserver agreement<sup>3, 4</sup>; it is non-continuous, grading disease activity in large steps between vitreous haze score categories; it is poorly discriminatory at the lower levels of vitreous inflammation that represents the majority of patients with active vitreous inflammation (i.e. +0.5, +1 vitreous haze score) and therefore arguably a challenge for clinical assessment, particularly in clinical trial scenarios.

There is consensus in the uveitis community for the need of objective measures of inflammatory activity in sight-threatening uveitis. With this aim, a recent proof-of-concept study demonstrated that spectral domain optical coherence tomography (OCT) images could be processed to obtain objective measurements of vitreous inflammation in eyes with intermediate, posterior and panuveitis.<sup>5</sup> This method was based on the determination of the signal intensity of the vitreous compartment, which was then compared to that of the retinal pigment epithelium (RPE) to generate an optical density ratio with arbitrary units that showed good correlation with vitreous haze score, but further validation was required. First, the original study was too small to allow subgroup analysis of common patient factors that might render the technique unreliable, notably phakic status or previous vitreoretinal surgery. Second, the original study employed an OCT device from a single vendor (Spectralis OCT, Heidelberg Engineering, Germany), raising the possibility that the method might not be applicable across other medical systems. Third, these preliminary findings needed to be confirmed in a different patient cohort, using a different team of OCT technicians and independent analysers to ascertain whether the method has applicability to and may be adopted by multiple end-users.

To these ends this study aims to evaluate the previously proposed OCT-derived vitritis quantification method in a larger series of intermediate, posterior and panuveitis eyes, using an alternative spectral domain OCT platform in a geographically and demographically distinct study population. Such data would deliver an independent evaluation of an ability to obtain objective, continuous and reproducible measurements of vitreous inflammation. A further aim is to determine the influence of phakic status or previous vitreo-retinal surgery on these objective measurements.

## Methods

All OCT image sets were obtained from patients attending a tertiary referral uveitis clinic (AA) at Institut Clínic d'Oftalmologia (ICOF), Hospital Clinic, Barcelona, Spain. Patients included in the study had intermediate, posterior or panuveitis of different etiologies, with varying degrees of vitreous inflammation, and corresponding OCT image sets captured during routine clinical care, from a 6 year-period (November 2009-June 2014). This study was approved by the Ethics Committee of the Hospital Clinic, Barcelona and was conducted in accordance with the Declaration of Helsinki.

## Clinical Data

Demographic data collected from patients in the study included age, gender, uveitis anatomical location, uveitis etiology, current treatment, and any history of previous intraocular surgery. Clinical characteristics of study eyes collected include: 1) best measured visual acuity (BMVA); 2) presence of keratic precipitates; 3) presence of posterior synechiae; 4) phakic status, classified as: a) phakic; b) pseudophakic; and c) aphakic; 5) anterior chamber (AC) activity and 6) vitreous haze score using standardized protocols according to the NEI and SUN guidelines.<sup>1,2</sup> All clinical data were collected during routine clinical care in an electronic medical records system and extracted for analysis. Only eyes with complete information of the above fields and corresponding OCT images were included in the analysis (Supplemental figure 1, available online at [www.aaojournal.org](http://www.aaojournal.org)).

## Optical Coherence Tomography Image Acquisition Protocol

All SD-OCT image sets included in this study were acquired using a spectral-domain OCT system (Cirrus HD-OCT, Carl Zeiss Meditec, Dublin, California) with the standard 'Macular Cube' protocol. The Macular Cube protocol consists of 128 horizontally oriented B-scans acquired in a continuous, automated sequence and covers a 6 mm × 6 mm area. Each B scan is 6 mm in length and composed of 512 equally spaced transverse sampled locations. The enhanced depth imaging mode was not used in any case, and the point of maximum sensitivity or zero delay line was maintained in the vitreous side.<sup>6</sup> For the purposes of this study, only scans centered in the fovea were analyzed.

## Qualitative Analysis of Optical Coherence Tomography images

SD-OCT images were qualitatively analyzed to assess the presence of 1) hyperreflective dots, larger and with greater density than background speckle noise as surrogate marker of cellular infiltrates into the vitreous;<sup>7</sup> 2) presence of epiretinal membrane preventing adequate transmission of light to the retinal pigment epithelium; and 3) severe anatomical disruption of retinal integrity and outer retinal layers/RPE status, preventing adequate delineation of the retinal pigment epithelium compartment of interest for the quantitative analysis. All cases with 2) and 3) were excluded from the subsequent quantitative analysis. Examples of clinical cases excluded are described in Supplemental Figure 2 (available online at [www.aaojournal.org](http://www.aaojournal.org)).

## Quantitative Analysis of Optical Coherence Tomography images

Raw SD-OCT images were exported from the Cirrus HD-OCT system and imported into OCTOR (Doheny Eye Institute, Los Angeles, California), custom grading software that allows manual delineation of boundaries that define the compartments of interest.<sup>8-10</sup> In each case, boundaries were manually segmented as per a previously described protocol for 3 B-scans passing through the foveal central subfield (central subfield of the Early Treatment Diabetic Retinopathy Study chart) by an experienced grader (JZV) masked to clinical vitreous haze score values.<sup>5</sup> The boundaries were: a) Vitreous top, the uppermost extent of vitreous space included in the OCT image; b) internal limiting membrane (ILM), the inner boundary of the neurosensory retina; c) RPE-inner limit, the inner boundary of the RPE; and d) RPE-outer limit, the outer boundary of the RPE. These boundaries delineate the following spaces: 1) vitreous, defined as the space between the vitreous top and ILM (except cases with incomplete posterior vitreous detachment, where the innermost limit of the vitreous hyaloid was chosen, as including this retrohyaloid space filled with optically hyporeflexive aqueous may infraestimate the absolute intensity of the compartment); and 2) RPE, defined as the space between the RPE-inner and the RPE-outer boundaries (Figure 1). The intensity of all pixels included in each of these compartments was summed to generate a corresponding mean OCT intensity value for the total scanned area, described as “VIT-absolute intensity” and “RPE-absolute intensity”, respectively. Finally, an arbitrary ratio was generated with these two values and expressed as “VIT/RPE relative intensity” (“VIT-absolute intensity”/“RPE-absolute intensity”).

## Statistical methods

Descriptive and frequency statistics were used to assess qualitative variables. Normality of quantitative variables (i.e. VIT/RPE intensity ratios) was examined using histograms. To assess differences in VIT/RPE mean intensity between study groups, non-parametric Mann-Whitney U-test and Kruskal-Wallis test were employed for 2-to-2 and  $\geq 3$  groups comparisons, respectively. Correlation between VIT/RPE intensity ratios and vitreous haze score was analyzed using non-parametric Spearman test, and a multivariable regression model was applied to assess the effects of clinical characteristics on SD-OCT intensity values. Visual acuity measured in Snellen notation was converted to logMAR (logarithm of the minimum angle of resolution) equivalents for the purposes of statistical analysis. VA values recorded as counting fingers (CF), hand movements (HM), and perception of light (PL) were converted to 2.1, 2.4, and 2.7 LogMAR, respectively.<sup>11</sup> A *p* value of less than 0.05 was considered statistically significant. All statistical analysis was performed using SPSS 15.0 software (SPSS Inc., Chicago, Illinois).

## Results

### Baseline Characteristics

Among the cohort of patients seen in the uveitis unit in the study period, 105 eyes with intermediate, posterior or pan-uveitis had complete clinical data with corresponding OCT images and were included in the study (Supplemental figure 1, available online at [www.aajournal.org](http://www.aajournal.org)). Demographics and baseline

characteristics of study eyes are summarized in Table 1, disclosed by total eyes and eyes with and without vitritis (vitritis defined as vitreous haze score  $\geq +0.5$ ) for comparison purposes.

### **Optical Coherence Tomography-derived Measurements of Vitreous Intensity**

The OCT-derived VIT/RPE relative intensity measurements for each vitreous haze score grade are represented in Figures 2 and 3 and Table 2. Significant differences were observed between eyes without vitritis (Vitreous haze score = 0, median 0.3456, interquartile range 0.024) and eyes with vitritis (Vitreous haze score  $\geq +0.5$ , median 0.3670, interquartile range 0.040) ( $p < 0.001$ ). Differences in VIT/RPE relative intensity values were also significant between study eyes disclosed by vitreous haze score clinical grade ( $p < 0.001$ ) (Figure 3). A significant correlation was observed between VIT/RPE relative intensity measurements and vitreous haze score clinical grade ( $r = 0.535$ ,  $p < 0.001$ ), AC cells ( $r = 0.246$ ,  $p = 0.01$ ) and AC flare ( $r = 0.215$ ,  $p = 0.02$ ). No significant differences were observed for VA ( $r = 0.182$ ,  $p = 0.06$ ), however, once eyes with very poor VA were excluded from analysis (3 eyes excluded, “counting fingers”,  $n = 2$ , and “hand movements”,  $n = 1$ ) this correlation was also significant ( $r = 0.198$ ,  $p = 0.04$ ). Figure 4 represents the correlation between VIT/RPE relative intensity values and vitreous haze score clinical grades. After adjusting for factors governing media clarity (such as AC cells, AC flare and phakic status) in a stepwise multivariable model, VIT/RPE relative intensity values remained independently associated with vitreous haze score clinical grades ( $R^2$ -adjusted = 0.424,  $p < 0.001$ ).

### **Influence of Phakic Status**

Among the 105 eyes included in the study, 69 were phakic (65.7%), 32 were pseudophakic (30.5%) and four were aphakic (3.8%). No significant differences were observed in VIT/RPE relative intensity values between phakic (median = 0.3522, interquartile range = 0.028) and pseudophakic eyes (median = 0.3577, interquartile range = 0.027) ( $p = 0.48$ ). When eyes were categorised by vitreous haze score clinical grades, no significant differences were observed in the VIT/RPE relative intensity values between phakic and pseudophakic eyes (Figure 5) with a vitreous haze score of 0 (median = 0.3461, interquartile range = 0.021, median = 0.3483, interquartile range = 0.025,  $p = 0.91$ ), + 0.5 (median = 0.3595, interquartile range 0.027, median = 0.3646, interquartile range = 0.031,  $p = 0.91$ ), or + 1 (median = 0.3642, interquartile range = 0.037, median = 0.3658, interquartile range = 0.029,  $p = 0.87$ ), respectively (Table 3). For purposes of clarity, aphakic eyes ( $n = 4$ ) and eyes with vitreous haze score  $\geq 2$  ( $n = 12$ ) have not been included in Figure 5.

### **Influence of Previous Pars plana Vitrectomy**

At the time of OCT scanning, 92 eyes were non-vitreotomized (87.6%) and 13 eyes had undergone previous pars plana vitrectomy (12.4%). VIT/RPE relative intensity values were not significantly different between non-vitreotomized eyes (median = 0.3540, interquartile range = 0.032) and vitrectomized eyes (median = 0.3580, interquartile range = 0.021) ( $p = 0.52$ ). In the subgroup analysis by vitreous haze score clinical grades, no significant differences were observed between non-



1  
2  
3  
4 vitrectomized and vitrectomized eyes for vitreous haze score of 0 (median =  
5 0.3459, interquartile range = 0.024, median = 0.3461, interquartile range = 0.014, p  
6 = 0.21), + 0.5 (median = 0.3595, interquartile range 0.028, median = 0.3670,  
7 interquartile range = 0.001, p = 0.61), or + 1 (median = 0.3667, interquartile range  
8 = 0.034, median = 0.3568, interquartile range = 0.001, p = 0.91), respectively  
9 (Figure 6). For purposes of clarity, eyes with vitreous haze score  $\geq +2$  (n = 12)  
10 have not been included in Figure 6.  
11  
12  
13

## 14 **Discussion:**

15 Data from this current feasibility, early validation cohort supports the findings of the  
16 previous proof-of-concept study.<sup>5</sup> The data extends previous findings and delivers  
17 a rationale for and adoption of objective, continuous and reproducible OCT-derived  
18 measurements of vitreous inflammation in the clinical and trials setting. We show  
19 that the technique is reproducible with a different spectral domain OCT device and  
20 in a different cohort of uveitis patients. Importantly, the data also gives evidence  
21 that the method may be valid regardless of phakic status or previous pars plana  
22 vitrectomy.  
23  
24  
25

26 In recent years the rapid advancement of OCT acquisition speed and its  
27 ability to image through ocular media has enabled visualisation of some aspects of  
28 inflammation within the eye, opening the door to correlate OCT-derived images  
29 with clinical assessments.<sup>5, 10, 12</sup> The method employed in this study is based in the  
30 determination of absolute measurements of vitreous and RPE signal intensities,  
31 reflecting the mean intensity value for all image pixels contained within these  
32 compartments. Then, to reduce the effects of OCT signal strength and media  
33 opacities, both values are combined to obtain a ratio with arbitrary units, which can  
34 then be compared to clinical vitreous haze score. The use of optical density ratios  
35 has also previously been evaluated in subretinal and intraretinal fluid as a  
36 biomarker of different retinal diseases, such as age-macular degeneration, central  
37 serous chorioretinopathy, or diabetic retinopathy.<sup>13, 14</sup>  
38  
39  
40  
41

42 The findings reported in this study further corroborate the method proposed  
43 by Keane et al<sup>5</sup>, testing the resilience of this technique against a number of  
44 technical and clinical challenges. A key finding is that we have shown that this is  
45 not device specific. There is a difference in the relative intensity values for the  
46 same level of vitreous haze score between the studies (i.e. for vitreous haze score  
47 = +1, this study = 0.3663, and for Keane et al = 0.2222). Assuming that this is not  
48 due to variability in grading between different sets of clinicians across the two  
49 studies, then the data would imply that the absolute measurements are device-  
50 specific, and may be related to technical differences in the laser source and/or  
51 optical lens system of each OCT platform. Nevertheless significance of correlation  
52 to clinical scores is maintained. Differences between OCT devices have been  
53 demonstrated for a variety of OCT-derived measurements such as retinal and  
54 choroidal thickness or volume.<sup>15-17</sup> Whether this apparent difference is a device  
55 effect or arises due to variability of clinical practice needs further clarification  
56  
57  
58  
59  
60  
61  
62  
63  
64  
65

through performing sequential scans on the same patient on the same day across devices, and this work is ongoing.

If there is shown to be a real difference in absolute values between devices then our recommendations would be that (1) longitudinal assessments in clinical studies should all be made using the same OCT machine (as is indeed current practice); (2) all OCT machines that are to be used in this way need head-to-head studies vs a gold-standard to enable comparison between platforms, and the development of correction factors. In the future such correction factors can be incorporated into each OCT platform so that the clinician is provided with a corrected OCT-measured Vitreous/RPE relative intensity score (cVIT/RPE) that is directly comparable across platforms. It is worth noting that the value of the technique is best highlighted by its potential role in measuring response to treatment, similar to the use of central macular thickness (CMT) in assessing improvement in cystoid macular edema (CME). In both scenarios it is the direction of change, the relative magnitude and the return to normality that are the criteria by which treatment success is measured, and as such the absolute values are less important.

Another important finding of the study was the demonstration that the technique does not appear to be affected by phakic status or previous vitrectomy. Both pseudophakia and previous vitrectomy surgery are common scenarios in the uveitic population (30% and 12% respectively in this study cohort) and thus alterations in the VIT/RPE relative intensity arising from these surgical interventions would have been a significant challenge to the utility of the technique in daily practice. The use of a ratio relating the absolute values of optical reflectivity in the vitreous to the RPE layer was chosen so as to compensate for potential differences in laser beam transmission through the media of the anterior segment (including phakic status), and this is further justified by the results of this study.

We recognise that this was a retrospective cohort study, with the inherent challenges that brings. Of relevance is that the vitreous haze score was assessed as part of routine care by a single clinician, rather than by two independent clinicians as was done in the Keane et al. paper.<sup>5</sup> It should be noted however that this is common practice in clinical trials, even those in which vitreous haze score is the primary endpoint. One advantage of the retrospective design is that it demonstrates the utility of this technique in unselected scans taken as part of routine practice with no additional special measures, and that if this technique became widely used it could also be applied to historical scans providing a huge resource both for further research and to inform decision making in the clinic. Although not supported by the current data, a potential bias remains when analysing and comparing non-vitrectomized versus vitrectomized eyes with respect to a potential over-estimate of optical density in non-vitrectomized eyes. The major limitation highlighted by this study was the burden of performing this technique manually. On average each scan took 5-10 mins when conducted by an experienced grader. This would be prohibitive for routine clinical use. In light of this we have recently developed custom VITreous ANALYSIS software (termed 'VITAN'), which is fully automated and avoids the need for manual segmentation.<sup>18</sup> This has

1  
2  
3  
4 been validated on the original cohort described in the Keane et al paper, and was  
5 shown to perform accurate segmentation in 100% scans. Results were comparable  
6 to those with the manual technique, with a slightly higher correlation with clinical  
7 vitreous haze scores than that reported using manual segmentation in our previous  
8 study. Critically VITAN analyses each scan in < 2 seconds, enabling immediate  
9 assessment at the point-of-contact, ideal for routine clinical use.  
10  
11

12  
13 In summary, we have demonstrated that SD-OCT measurement of VIT/RPE  
14 relative intensity using the Cirrus instrument is a robust measure of vitreous haze  
15 which correlates with the clinical vitreous haze score, and which is not limited by  
16 phakic state or previous vitrectomy. Such measures hold immense promise but  
17 require further validation, a key part of which will be in their use as exploratory  
18 endpoints in prospective multicentre interventional studies. This study forms part of  
19 the Extended OCT-Quantification of Uveitis Activity for Trial Outcomes and  
20 Reporting (EQUATOR) programme, the purpose of which is to develop and  
21 validate objective imaging-based measures of ocular inflammation for use in  
22 clinical trials and routine clinical practise and which would in time replace the  
23 current subjective clinical measures we depend on. In this area, it is encouraging to  
24 see progress being made by groups around the world regarding the assessment of  
25 other such variables notably AC cells<sup>12, 19, 20</sup> and retinovascular leakage.<sup>21</sup> The  
26 development and validation of such techniques supported by increasingly sensitive  
27 OCT instruments capable of imaging larger volumes of the eye will revolutionise  
28 both clinical practice and the ability of clinical trials to demonstrate treatment  
29 efficacy.  
30  
31  
32  
33  
34  
35  
36  
37  
38  
39  
40  
41  
42  
43  
44  
45  
46  
47  
48  
49  
50  
51  
52  
53  
54  
55  
56  
57  
58  
59  
60  
61  
62  
63  
64  
65

## **Acknowledgements/Disclosure**

### **A. Funding / Support**

Javier Zarranz-Ventura is a grant recipient of the Spanish Retina & Vitreous Society (Sociedad Española de Retina y Vítreo, Santiago de Compostela, Spain). This work was partly supported by the National Institute for Health Research Biomedical Research Centre based at Moorfields Eye Hospital National Health Service Foundation Trust and University College London Institute of Ophthalmology (London, United Kingdom). The views expressed are those of the authors (Pearse A. Keane, Dawn A. Sim, Adnan Tufail, Richard W. Lee, Andrew D. Dick, Carlos Pavesio) and not necessarily those of the National Health Service, the National Institutes for Health Research or the Department of Health.

### **B. Financial disclosures**

Javier Zarranz-Ventura has received travel grants from Allergan (Irvine, CA, USA), Bayer (Leverkusen, Germany) and Novartis (Basel, Switzerland) and is a member of the Allergan European Retina Panel; Pearse A. Keane has given lectures for Novartis and is a member of the Allergan European Retina Panel; Dawn A. Sim is a member of the Allergan European Retina Panel; Adnan Tufail; has been in advisory boards and has given lectures for Allergan, Alimera Science (Alpharetta, GA, USA), Bayer, Novartis and Roche (Basel, Switzerland), and has received grants from Medisoft Ltd (Leeds, United Kingdom), Notal Vision (Tel Aviv, Israel) and Novartis; Srinivas R. Sadda has been in advisory boards and has received grants from Carl Zeiss Meditec (Dublin, CA, USA) and Optos (Edinburgh, Scotland, United Kingdom); Andrew D. Dick has been in advisory boards for Novartis, Abbvie (Chicago, IL, USA), LuxBio (Jersey City, NJ, USA), Qchip (Cardiff, Wales, United Kingdom), Exonate (Cambridge, United Kingdom) and Sanofi (Paris, France), has received grants from Novartis, Varleigh Ltd (London, United Kingdom) and Glaxo-Smith-Kline (Middlesex, United Kingdom), and has given lectures for Genentech (South San Francisco, CA, USA); Richard W. Lee has served as consultant for Roche and Genentech and has been in advisory boards for EMD Serono (Darmstadt, Germany); Alfredo Adan has been in advisory boards for Abbvie and Novartis.

### **C. Other acknowledgments**

None.

## References

1. Jabs DA, Nussenblatt RB, Rosenbaum JT. Standardization of uveitis nomenclature for reporting clinical data. Results of the First International Workshop. *Am J Ophthalmol* 2005;140(3):509-16.
2. Nussenblatt RB, Palestine AG, Chan CC, Roberge F. Standardization of vitreal inflammatory activity in intermediate and posterior uveitis. *Ophthalmology* 1985;92(4):467-71.
3. Kempen JH, Ganesh SK, Sangwan VS, Rathinam SR. Interobserver agreement in grading activity and site of inflammation in eyes of patients with uveitis. *Am J Ophthalmol* 2008;146(6):813-8 e1.
4. Hornbeak DM, Payal A, Pistilli M, et al. Interobserver agreement in clinical grading of vitreous haze using alternative grading scales. *Ophthalmology* 2014;121(8):1643-8.
5. Keane PA, Karampelas M, Sim DA, et al. Objective measurement of vitreous inflammation using optical coherence tomography. *Ophthalmology* 2014;121(9):1706-14.
6. Spaide RF, Koizumi H, Pozzoni MC. Enhanced depth imaging spectral-domain optical coherence tomography. *Am J Ophthalmol* 2008;146(4):496-500.
7. Saito M, Barbazetto IA, Spaide RF. Intravitreal cellular infiltrate imaged as punctate spots by spectral-domain optical coherence tomography in eyes with posterior segment inflammatory disease. *Retina* 2013;33(3):559-65.
8. Sadda SR, Keane PA, Ouyang Y, Updike JF, Walsh AC. Impact of scanning density on measurements from spectral domain optical coherence tomography. *Invest Ophthalmol Vis Sci* 2010;51(2):1071-8.
9. Karampelas M, Sim DA, Keane PA, et al. Choroidal assessment in idiopathic panuveitis using optical coherence tomography. *Graefes Arch Clin Exp Ophthalmol* 2013;251(8):2029-36.
10. Zarranz-Ventura J, Sim DA, Keane PA, et al. Characterization of punctate inner choroidopathy using enhanced depth imaging optical coherence tomography. *Ophthalmology* 2014;121(9):1790-7.
11. Sparrow JM, Taylor H, Qureshi K, Smith R, Birnie K, Johnston RL. The Cataract National Dataset electronic multi-centre audit of 55,567 operations: risk indicators for monocular visual acuity outcomes. *Eye (Lond)* 2012;26(6):821-6.

12. Sharma S, Lowder CY, VasANJI A, Baynes K, Kaiser PK, Srivastava SK. Automated Analysis of Anterior Chamber Inflammation by Spectral-Domain Optical Coherence Tomography. *Ophthalmology* 2015; (April 4<sup>th</sup>, e-Pub ahead of print).
13. Barthelmes D, Sutter FK, Gillies MC. Differential optical densities of intraretinal spaces. *Invest Ophthalmol Vis Sci* 2008;49(8):3529-34.
14. Ahlers C, Golbaz I, Einwallner E, et al. Identification of optical density ratios in subretinal fluid as a clinically relevant biomarker in exudative macular disease. *Invest Ophthalmol Vis Sci* 2009;50(7):3417-24.
15. Yamashita T, Yamashita T, Shirasawa M, Arimura N, Terasaki H, Sakamoto T. Repeatability and reproducibility of subfoveal choroidal thickness in normal eyes of Japanese using different SD-OCT devices. *Invest Ophthalmol Vis Sci* 2012;53(3):1102-7.
16. Branchini L, Regatieri CV, Flores-Moreno I, Baumann B, Fujimoto JG, Duker JS. Reproducibility of choroidal thickness measurements across three spectral domain optical coherence tomography systems. *Ophthalmology* 2012;119(1):119-23.
17. Chin EK, Sedeek RW, Li Y, et al. Reproducibility of macular thickness measurement among five OCT instruments: effects of image resolution, image registration, and eye tracking. *Ophthalmic Surg Lasers Imaging* 2012;43(2):97-108.
18. Keane PA, Balaskas K, Sim DA, et al. Automated analysis of vitreous inflammation using spectral domain optical coherence tomography. *Translational Vision Science and Technology* 2015;(In press).
19. Li Y, Lowder C, Zhang X, Huang D. Anterior chamber cell grading by optical coherence tomography. *Invest Ophthalmol Vis Sci* 2013;54(1):258-65.
20. Agarwal A, Ashokkumar D, Jacob S, Agarwal A, Saravanan Y. High-speed optical coherence tomography for imaging anterior chamber inflammatory reaction in uveitis: clinical correlation and grading. *Am J Ophthalmol* 2009;147(3):413-416 e3.
21. Karampelas M, Sim DA, Chu C, et al. Quantitative analysis of peripheral vasculitis, ischemia, and vascular leakage in uveitis using ultra-widefield fluorescein angiography. *Am J Ophthalmol* 2015;159(6):1161-1168 e1.

**Figure Captions:**

**Figure 1.** Segmentation protocol for quantitative analysis of the vitreous with OCTOR (Doheny Image Reading Center, Los Angeles, CA). Spectral domain optical coherence tomography (SD-OCT) (Cirrus HD-OCT, Carl Zeiss Meditec, Dublin, CA) B-scan obtained from a 54-year-old patient with Vogt-Koyanagi-Harada disease-related panuveitis and moderate vitreous haze (clinical vitreous haze score +2). **[Top]:** Raw SD-OCT B-scan. **[Middle]:** Boundaries segmented manually with OCTOR (top white line, arrowhead=vitreous top; pink line, asterisk=internal limiting membrane (ILM); superior white arrow, white line=retinal pigment epithelium (RPE)-inner boundary; inferior white arrow, white line=RPE-outer boundary). **[Bottom]:** Segmentation of the vitreous and the RPE compartments defined by the above boundaries (vitreous=grey, retina=pink, RPE=brown). Vitreous signal intensity/RPE (VIT/RPE)-relative intensity of 0.4146.

**Figure 2.** Visualization of inflammatory changes in the vitreous using spectral-domain optical coherence tomography (SD-OCT) (Cirrus HD-OCT, Carl Zeiss Meditec, Dublin, CA). **[Top]**, SD-OCT B-scan obtained from a 32 year-old patient with quiescent intermediate uveitis related to systemic lupus erythematosus and no signs of vitritis (clinical vitreous haze score 0, vitreous signal intensity/retinal pigment epithelium (VIT/RPE)-relative intensity 0.3292). **[Middle-Top]**, SD-OCT B-scan of a 45-year-old patient with sarcoid-related panuveitis demonstrating minimal vitreous haze (clinical vitreous haze score +0.5, VIT/RPE-relative intensity 0.3522). **[Middle]**, SD-OCT B-scan obtained from a 39 year-old patient with sympathetic ophthalmia demonstrating moderate vitreous haze (clinical vitreous haze score +1, VIT/RPE-relative intensity 0.3652). **[Middle-Bottom]**, SD-OCT B-scan obtained from a 26 year-old patient with posterior uveitis related to Behçet's disease demonstrating moderate to severe vitreous haze (clinical vitreous haze score +2, VIT/RPE-relative intensity 0.4328). **[Bottom]**, SD-OCT B-scan obtained from a 44-year-old patient with intermediate uveitis related to multiple sclerosis demonstrating severe vitreous haze (clinical vitreous haze score +3, VIT/RPE-relative intensity 0.5652).

**Figure 3.** Box-plots showing vitreous signal intensity/retinal pigment epithelium (VIT/RPE)-Relative intensity measurements for each clinical grade of vitreous haze. The horizontal lines within each box represent the median for each group, the ends of the boxes are the upper and lower quartiles and the whiskers represent minimum and maximum values.

**Figure 4.** Scatter plot comparing clinical vitreous haze scores with vitreous signal intensity/retinal pigment epithelium (VIT/RPE)-relative intensity values. The solid line represents the regression line.

**Figure 5.** Subgroup analysis of vitreous signal intensity/retinal pigment epithelium (VIT/RPE)-relative intensity measurements by phakic status. Box-plots showing VIT/RPE-relative intensity measurements for each clinical grade of vitreous haze in phakic (dark grey) and pseudophakic (light grey) eyes. The horizontal lines within

each box represent the median for each group, the ends of the boxes are the upper and lower quartiles and the whiskers represent minimum and maximum values.

**Figure 6.** Subgroup analysis of vitreous signal intensity/retinal pigment epithelium (VIT/RPE)-relative intensity measurements by previous vitreo-retinal surgery. Box-plots showing VIT/RPE-relative intensity measurements for each clinical grade of vitreous haze in non-vitreotomized (dark grey) and vitreotomized (light grey) eyes. The horizontal lines within each box represent the median for each group, the ends of the boxes are the upper and lower quartiles and the whiskers represent minimum and maximum values.

**Supplemental Figure 1.** Consolidated standards of reporting trials-style diagram showing the number of excluded and included eyes in the study which underwent assessment with the optical coherence tomography vitritis grading method (*supplemental material available at AJO.com*).

**Supplemental Figure 2.** Examples of cases in which the proposed vitritis grading method with optical coherence tomography cannot be applied. **[Top]**, B-scan obtained from a 50-year-old patient with sympathetic ophthalmia and extensive retinal pigment epithelium (RPE) atrophy. **[Middle-Top]**, B-scan from an 85 year-old patient with sarcoid-related panuveitis with thick epiretinal membrane preventing adequate penetrance of light up to the RPE. **[Middle-Bottom]**, B-scan obtained from a 71 year-old patient with non-differentiated panuveitis showing severe anatomical distortion preventing adequate identification of RPE inner and outer boundaries. **[Bottom]**, B-scan obtained from a 42 year-old patient with Vogt-Koyanagi-Harada disease demonstrating serous retinal detachments, with severe architectural damage at the outer retinal layers preventing adequate delineation of the RPE boundaries (*supplemental material available at AJO.com*).



## Appendix:

---

EQUATOR Consortium members who contributed to this study comprise (in alphabetical order):

Alfredo Adán MD, PhD<sup>1</sup>, Tariq Aslam PhD, FRCOphth<sup>2,3,4</sup>, Alastair K. Denniston PhD FRCOphth<sup>5,6,7</sup>, Andrew D. Dick MD, FMedSci,<sup>8,9</sup> Michael Karampelas MD, FEBO,<sup>8,10</sup> Pearse A. Keane MD, FRCOphth,<sup>8</sup> Richard W. Lee MRCOphth, PhD,<sup>8,9</sup> Philip I. Murray PhD, FRCOphth,<sup>6,7</sup> Robert B. Nussenblatt MD, MPH,<sup>11</sup> Carlos E. Pavesio MD, FRCOphth,<sup>8</sup> Srinivas R. Sadda MD,<sup>12</sup> H. Nida Sen MD, MHSc,<sup>11</sup> Dawn A. Sim FRCOphth,<sup>8</sup> Adnan Tufail MD, FRCOphth,<sup>8</sup> Javier Zarranz-Ventura MD, PhD, FEBO<sup>1,8,9</sup>

<sup>1</sup>Institut Clínic d'Oftalmologia, Hospital Clinic, Barcelona, Spain

<sup>2</sup>Manchester Royal Eye Hospital, Central Manchester University Hospitals National Health Service Foundation Trust, Manchester Academic Health Science Centre, Manchester, United Kingdom

<sup>3</sup>Faculty of Medical and Human Sciences, University of Manchester, United Kingdom

<sup>4</sup>School of Built Environment, Herriot-Watt University, United Kingdom

<sup>5</sup>Queen Elizabeth Hospital Birmingham, University Hospitals Birmingham National Health Service Foundation Trust, Birmingham, United Kingdom

<sup>6</sup>Academic Unit of Ophthalmology, University of Birmingham, Birmingham, United Kingdom

<sup>7</sup>Birmingham & Midland Eye Centre, Sandwell and West Birmingham National Health Service Trust, Birmingham, United Kingdom

<sup>8</sup>National Institute of Health Research Biomedical Research Centre for Ophthalmology, Moorfields Eye Hospital National Health Service Foundation Trust and University College London Institute of Ophthalmology, United Kingdom

<sup>9</sup>Academic Unit of Ophthalmology, University of Bristol, Bristol, United Kingdom

<sup>10</sup>Hinchingbrooke Hospital, Hinchingbrooke Health Care National Health Service Trust, United Kingdom

<sup>11</sup>National Eye Institute, National Institutes of Health, Bethesda, Maryland, United States

<sup>12</sup>Doheny Eye Institute, University of California Los Angeles, California, United States

**Table 1.** Demographics and baseline clinical characteristics of study eyes analysed with the optical coherence tomography vitritis grading method and subgroup analysis by no vitritis and vitritis eyes.

	<b>Total Uveitis eyes</b>	<b>Uveitis eyes No Vitritis</b>	<b>Uveitis eyes Vitritis</b>
Age, mean $\pm$ SD	45.3 $\pm$ 16.4	46.6 $\pm$ 14.8	44.0 $\pm$ 17.9
VA, mean $\pm$ SD (logMAR)	0.30 $\pm$ 0.38	0.28 $\pm$ 0.4	0.33 $\pm$ 0.35
<b>Phenotypic diagnosis, no. (%)</b>			
- Behçet's	24 (22.8)	14 (25.9)	10 (19.6)
- Birdshot	22 (20.9)	10 (18.5)	12 (23.5)
- Sarcoid	14 (13.3)	9 (16.6)	5 (9.8)
- Non-differentiated	11 (10.4)	3 (5.5)	8 (15.6)
- Pars planitis	8 (7.6)	5 (9.2)	3 (5.8)
- VKH	6 (5.7)	2 (3.7)	4 (7.8)
- Multiple sclerosis	4 (3.8)	1 (1.8)	3 (5.8)
- Other	16 (15.2)	10 (18.5)	6 (11.7)
<b>Uveitis anatomic classification, no. (%)</b>			
- Intermediate	34 (32.3)	14 (25.9)	20 (39.2)
- Posterior	36 (34.2)	19 (35.1)	17 (33.3)
- Panuveitis	35 (33.3)	21 (38.8)	14 (27.4)
Keratic precipitates, no. (%)	11 (10.4)	4 (7.4)	7 (13.7)
Posterior synechiae, no. (%)	7 (6.6)	5 (9.2)	2 (3.9)
<b>Phakic status, no. (%)</b>			
a. Phakic	71 (67.5)	35 (64.7)	36 (70.5)
- Clear lens	47 (44.7)	22 (40.7)	25 (49.0)
- Cataract	24 (22.8)	13 (24.0)	11 (21.5)
b. Pseudophakic	30 (28.5)	16 (29.6)	14 (27.4)
c. Aphakic	4 (3.8)	3 (5.5)	1 (1.9)
d. Posterior capsular opacification, no. (%)	6 (5.7)	3 (5.5)	3 (5.8)
<b>AC cells, no. (%)</b>			
0	85 (80.9)	52 (96.2)	33 (64.7)
0.5+	8 (7.6)	2 (3.7)	6 (11.7)
1+	8 (7.6)	0 (0)	8 (15.6)
2+	3 (2.8)	0 (0)	3 (5.8)

3+	0 (0)	0 (0)	0 (0)
4+	1 (0.9)	0 (0)	1 (1.9)
<b>AC flare, no. (%)</b>			
0	96 (91.4)	54 (100)	42 (82.3)
1+	6 (5.7)	0 (0)	6 (11.7)
2+	2 (1.9)	0 (0)	2 (3.9)
3+	1 (0.9)	0 (0)	1 (1.9)
4+	0 (0)	0 (0)	0 (0)
<b>Vitreous Haze Score, no. (%)</b>			
0	54 (51.4)	54 (100)	0 (0)
0.5+	21 (20)	0 (0)	21 (41.1)
1+	18 (17.1)	0 (0)	18 (35.2)
2+	9 (8.5)	0 (0)	9 (17.6)
3+	3 (2.8)	0 (0)	3 (5.8)
4+	0 (0)	0 (0)	0 (0)

(AC = Anterior chamber; logMAR = logarithm of the minimum angle of resolution; SD = standard deviation; VA = visual acuity; VKH = Vogt-Koyanagi-Harada disease).

**Table 2.** Comparison of vitreous / retinal pigment epithelium (VIT/RPE) relative intensity values between vitreous haze score subgroups, considering vitreous haze score = 0 as reference group.

Vitreous Haze Score	VIT/RPE Relative intensity (median)	P value
0	0.3456 IQR 0.022 (n=54)	(reference)
0.5+	0.3623 IQR 0.027 (n=21)	0.009*
1+	0.3663 IQR 0.036 (n=18)	<0.001*
2+	0.3884 IQR 0.063 (n=9)	0.002*
3+	0.3915 IQR n/a (n=3)	<0.001*
4+	n/a (n=0)	n/a
Total (n)	105	

(\* p<0.05 = significant; IQR = interquartile range; n/a = not applicable).

**Table 3.** Comparison of vitreous / retinal pigment epithelium (VIT/RPE) relative intensity values between study eyes disclosed by phakic status and previous pars plana vitrectomy at different levels of vitreous haze score.

Vitreous Haze Score	Phakic status			Previous Pars Plana Vitrectomy		
	Phakic	Pseudophakic	P value	No PPV	PPV	P value
0	0.3461 IQR 0.3461 (n=35)	0.3483 IQR 0.025 (n=16)	0.91	0.3459 IQR 0.024 (n=46)	0.3461 IQR 0.014 (n=8)	0.21
0.5+	0.3595 IQR 0.027 (n=13)	0.3646 IQR 0.031 (n=8)	0.91	0.3595 IQR 0.028 (n=19)	0.3670 IQR n/a (n=2)	0.61
1+	0.3642 IQR 0.037 (n=12)	0.3658 IQR 0.029 (n=5)	0.87	0.3667 IQR 0.034 (n=15)	0.3568 IQR n/a (n=3)	0.91
2+	0.3959 IQR 0.075 (n=8)	0.3756 IQR n/a (n=1)	0.66	0.3900 IQR 0.052 (n=9)	n/a (n=0)	n/a
3+	0.3776 IQR n/a (n=1)	0.4784 IQR n/a (n=2)	0.66	0.3915 IQR n/a (n=3)	n/a (n=0)	n/a
4+	n/a (n=0)	n/a (n=0)	n/a	n/a (n=0)	n/a (n=0)	n/a
Total (n)	69	32		92	13	

(\*  $p < 0.05$  = significant; IQR = interquartile range; PPV = pars plana vitrectomy; n/a = not applicable).

Figure 1  
[Click here to download high resolution image](#)

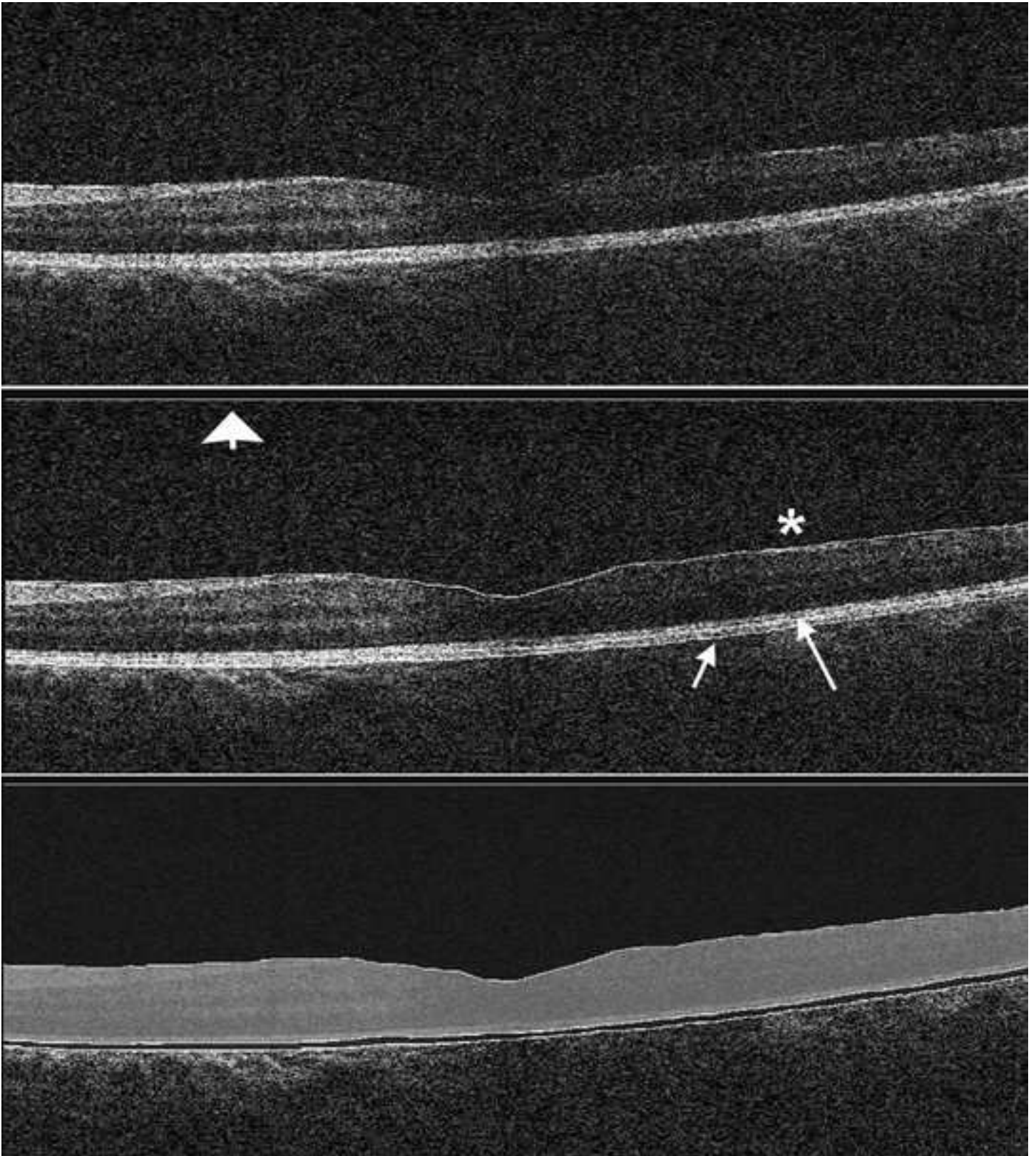


Figure 2  
[Click here to download high resolution image](#)

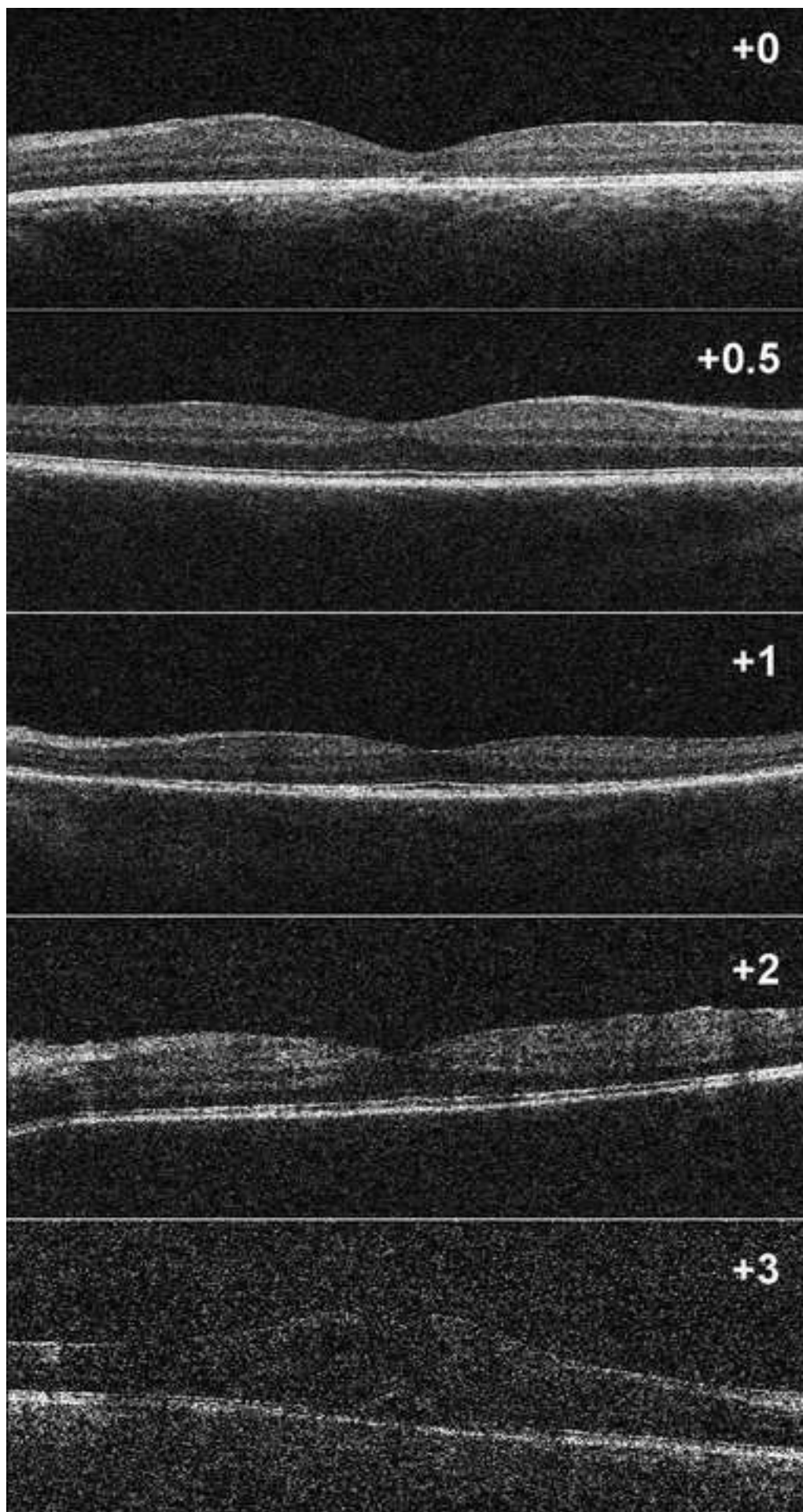


Figure 3  
[Click here to download high resolution image](#)

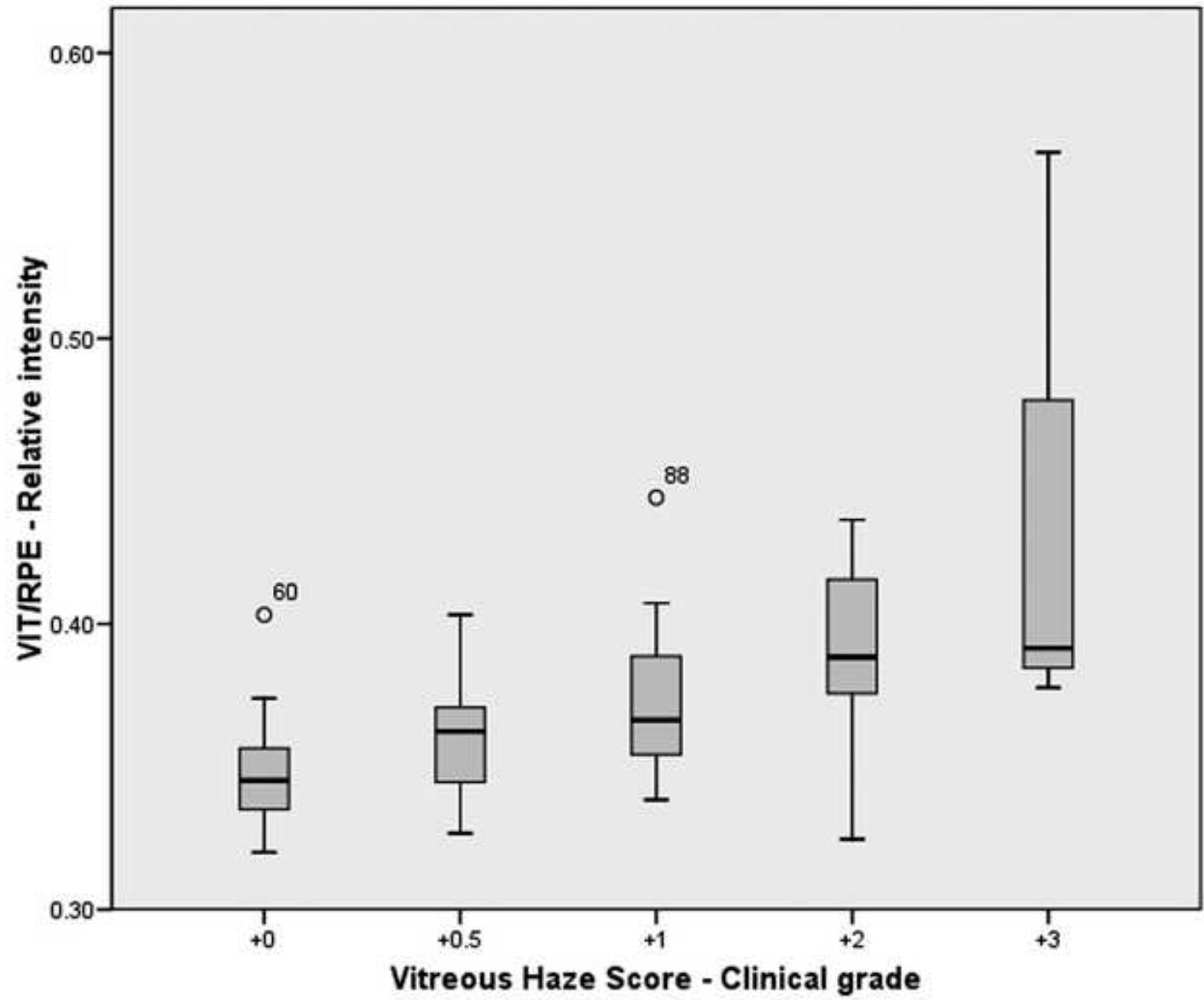




Figure 4  
[Click here to download high resolution image](#)

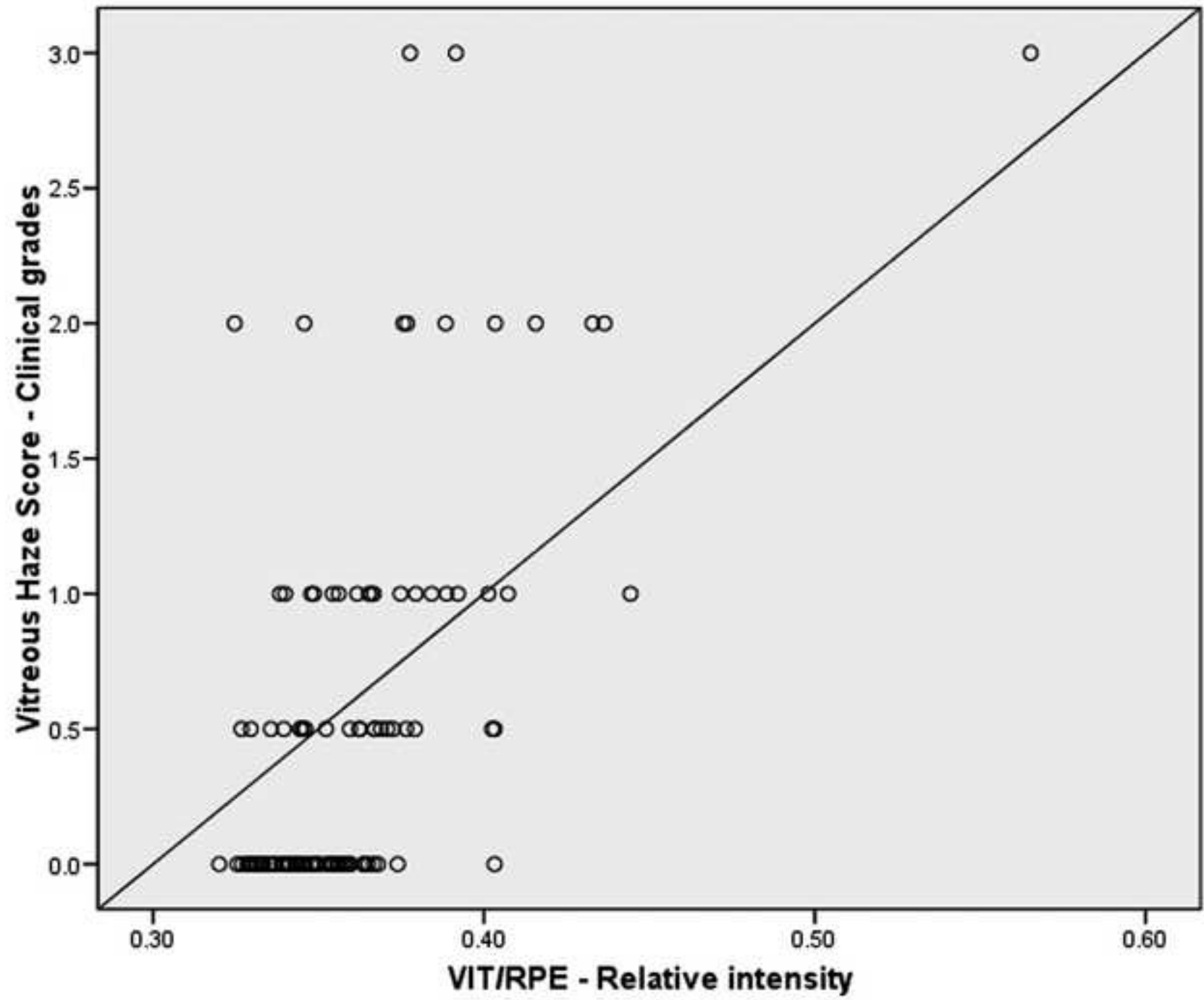


Figure 5  
[Click here to download high resolution image](#)

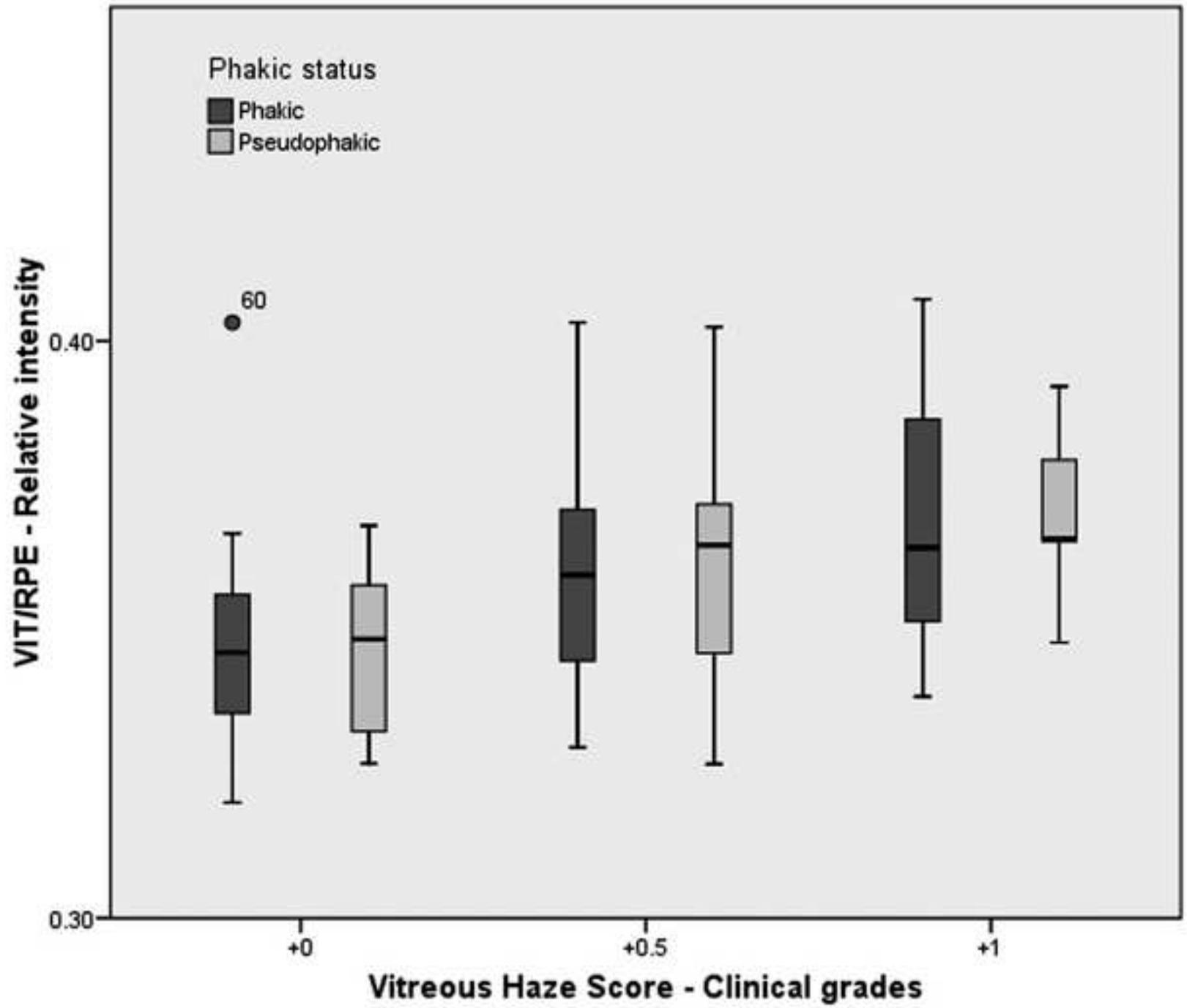
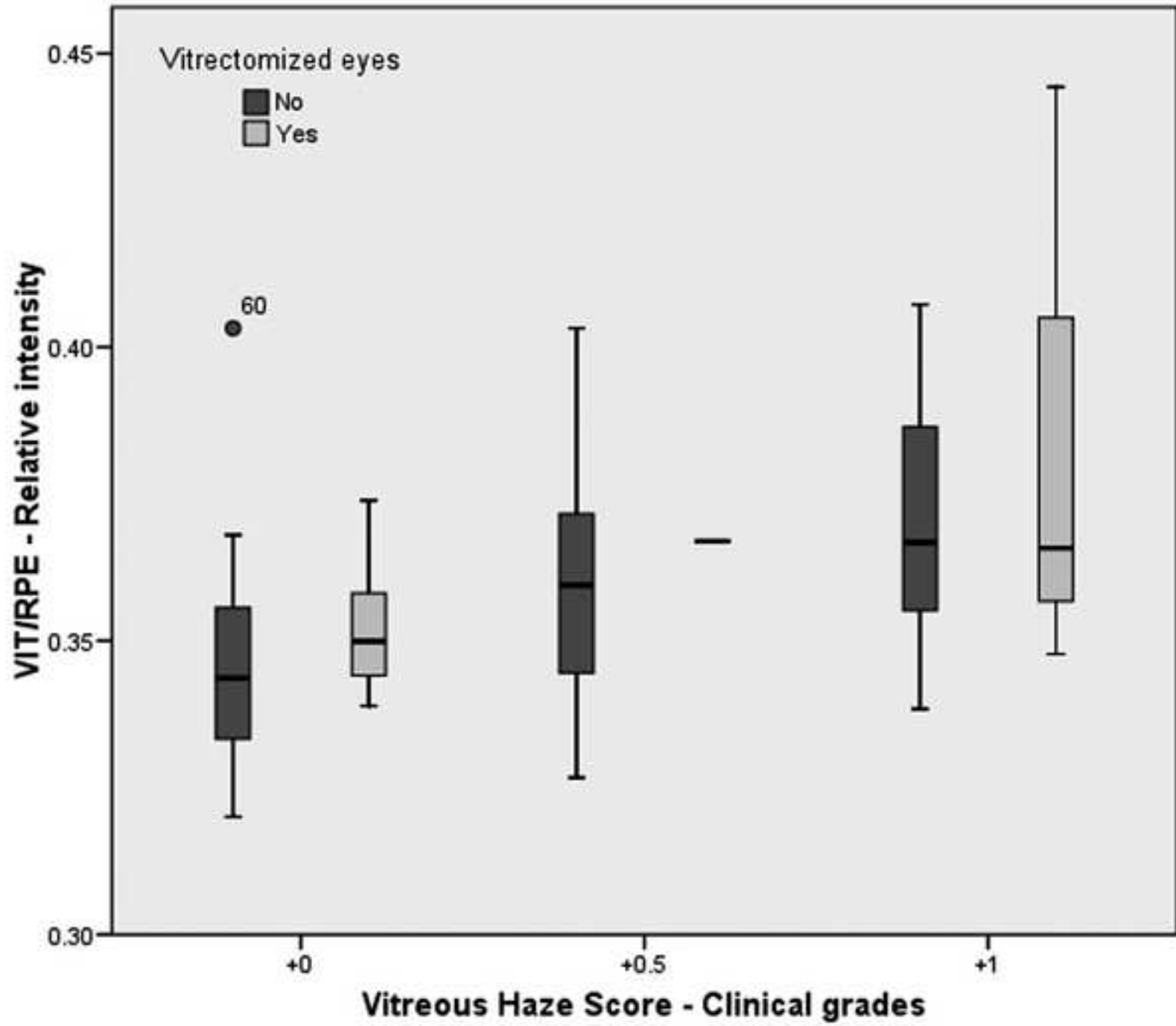


Figure 6  
[Click here to download high resolution image](#)



**Manuscript title:**

**“Evaluation of objective vitritis grading method using optical coherence tomography: influence of phakic status and previous vitrectomy”**

**Manuscript number:**

AJO-S-15-00957-R2

**Table of contents statement:**

This study evaluates a recently proposed novel optical coherence tomography (OCT)-derived vitritis quantification method in a large series of uveitis eyes using an spectral domain OCT platform. Based on the large number of evaluated eyes, it also examines the influence of phakic status or previous vitreo-retinal surgery on these objective, quantifiable, and reproducible vitreous/retinal pigment epithelium optical density relative intensity measurements.

## AJO Contributions of Authors and Sponsors

### Manuscript Title Evaluation of objective vitritis grading method using optical coherence tomography: influence of phakic status and previous vitrectomy

#### Authorship Responsibility and Contributions to Authorship

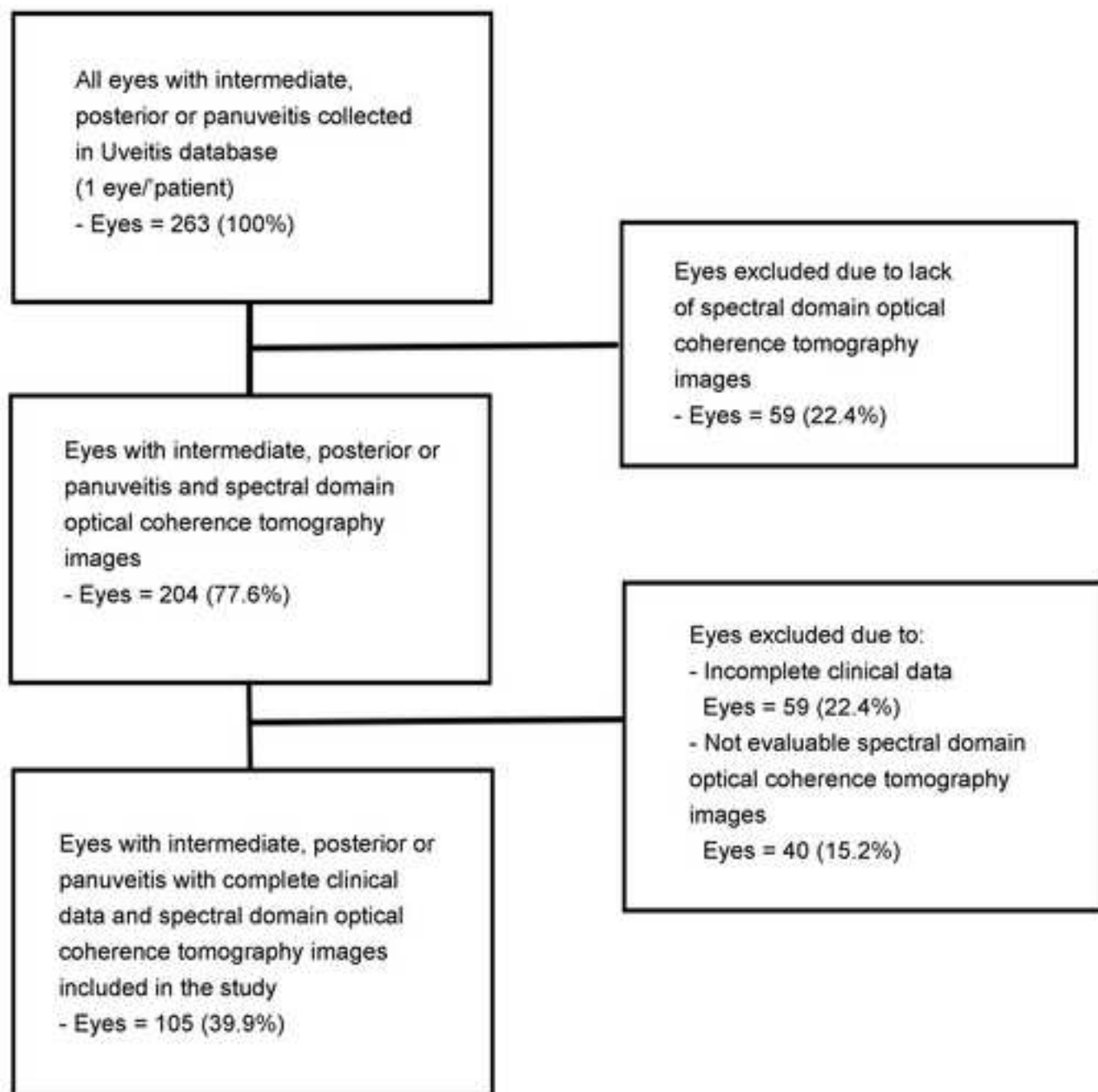
The author byline should accurately reflect those that did the research and wrote the manuscript. Honorary or guest authors are not permitted. Medical writers or industry writers or statisticians may reach the level of authorship but at least should be listed in the Acknowledgement Section. There should be no ghost (hidden) authors. By submitting this manuscript, each author certifies that they have made a direct and substantial contribution to the work reported in the manuscript by participating in *at least* the following three areas: (1) conceiving and designing the study or analyzing and interpreting the data; (2) writing the manuscript or providing critical revisions that are important for the intellectual content; and (3) approving the final version of the manuscript. They have participated to a sufficient degree to take public responsibility for the work and believe that the manuscript describes truthful facts. They declare that they shall produce the data on which the manuscript is based for examination by the editors or their assignees, should it be requested. Each author also agrees to permit the corresponding author to make decisions regarding submission of the manuscript to the Journal, changes to galley proofs, and prepublication release of information in the manuscript to the media, federal agencies, or both. Galley proofs are to be approved by the corresponding author only.

By submitting this form, the corresponding author acknowledges that each author has read and completed 1) the statement on authorship responsibility and contribution to authorship and 2) the statement on sponsor involvement.

In the table below, please designate the substantive contribution(s) of each author. Any contribution not described in the box should be indicated in the space for "Other contributions." For a multicenter or group study, the authors listed on the title page should attest to this information but other members of the study group do not need to attest. However, they should be listed by name in an appendix. If the article is accepted, this information will appear as supplemental material at [www.ajo.com](http://www.ajo.com).

Author Name	Conception and design	Analysis and interpretation	Writing the article	Critical revision of the article	Final approval of the article	Data Collection	Provision of materials, patients, or resources	Statistical expertise	Obtaining funding	Literature search	Administrative, technical, or logistic support
Javier Zarranz-Ventura	<input checked="" type="checkbox"/>	<input checked="" type="checkbox"/>	<input checked="" type="checkbox"/>	<input checked="" type="checkbox"/>	<input checked="" type="checkbox"/>	<input checked="" type="checkbox"/>	<input type="checkbox"/>	<input checked="" type="checkbox"/>	<input type="checkbox"/>	<input checked="" type="checkbox"/>	<input checked="" type="checkbox"/>
Pearse A. Keane	<input checked="" type="checkbox"/>	<input checked="" type="checkbox"/>	<input checked="" type="checkbox"/>	<input checked="" type="checkbox"/>	<input checked="" type="checkbox"/>	<input type="checkbox"/>	<input type="checkbox"/>	<input type="checkbox"/>	<input type="checkbox"/>	<input checked="" type="checkbox"/>	<input type="checkbox"/>
Dawn A. Sim	<input checked="" type="checkbox"/>	<input checked="" type="checkbox"/>	<input type="checkbox"/>	<input checked="" type="checkbox"/>	<input checked="" type="checkbox"/>	<input type="checkbox"/>	<input type="checkbox"/>	<input type="checkbox"/>	<input type="checkbox"/>	<input checked="" type="checkbox"/>	<input type="checkbox"/>
Victor Llorens	<input type="checkbox"/>	<input type="checkbox"/>	<input type="checkbox"/>	<input type="checkbox"/>	<input checked="" type="checkbox"/>	<input checked="" type="checkbox"/>	<input type="checkbox"/>	<input type="checkbox"/>	<input type="checkbox"/>	<input type="checkbox"/>	<input type="checkbox"/>
Adnan Tufail	<input type="checkbox"/>	<input type="checkbox"/>	<input type="checkbox"/>	<input type="checkbox"/>	<input checked="" type="checkbox"/>	<input type="checkbox"/>	<input type="checkbox"/>	<input type="checkbox"/>	<input type="checkbox"/>	<input type="checkbox"/>	<input type="checkbox"/>
Srinivas R. Sadda	<input type="checkbox"/>	<input type="checkbox"/>	<input type="checkbox"/>	<input type="checkbox"/>	<input checked="" type="checkbox"/>	<input type="checkbox"/>	<input type="checkbox"/>	<input type="checkbox"/>	<input type="checkbox"/>	<input type="checkbox"/>	<input type="checkbox"/>
Andrew D. Dick	<input type="checkbox"/>	<input checked="" type="checkbox"/>	<input type="checkbox"/>	<input checked="" type="checkbox"/>	<input checked="" type="checkbox"/>	<input type="checkbox"/>	<input type="checkbox"/>	<input type="checkbox"/>	<input type="checkbox"/>	<input type="checkbox"/>	<input type="checkbox"/>
Richard W. Lee	<input type="checkbox"/>	<input type="checkbox"/>	<input type="checkbox"/>	<input type="checkbox"/>	<input checked="" type="checkbox"/>	<input type="checkbox"/>	<input type="checkbox"/>	<input type="checkbox"/>	<input type="checkbox"/>	<input type="checkbox"/>	<input type="checkbox"/>
Carlos Pavesio	<input type="checkbox"/>	<input type="checkbox"/>	<input type="checkbox"/>	<input type="checkbox"/>	<input checked="" type="checkbox"/>	<input type="checkbox"/>	<input type="checkbox"/>	<input type="checkbox"/>	<input type="checkbox"/>	<input type="checkbox"/>	<input type="checkbox"/>
Alastair K. Denniston	<input checked="" type="checkbox"/>	<input checked="" type="checkbox"/>	<input checked="" type="checkbox"/>	<input checked="" type="checkbox"/>	<input checked="" type="checkbox"/>	<input type="checkbox"/>	<input type="checkbox"/>	<input type="checkbox"/>	<input type="checkbox"/>	<input checked="" type="checkbox"/>	<input type="checkbox"/>

Other contributions:



Supplementary Figure 2

