Synchrotron X-ray diffraction and scanning electron microscopy to understand enamel affected by metabolic disorder mucopolysaccharidosis

Khan, Malik Arshman; Addison, Owen; James, Alison; Hendriksz, Christian J.; Al-jawad, Maisoon

DOI:
10.1016/j.micron.2016.01.001



Title: Synchrotron X-ray Diffraction And Scanning Electron Microscopy To Understand Enamel Affected By Metabolic Disorder Mucopolysaccharidosis

Author: Malik Arshman Khan Owen Addison Alison James Christian J. Hendriksz Maisoon Al-Jawad

PII: S0968-4328(16)30001-4
DOI: http://dx.doi.org/doi:10.1016/j.micron.2016.01.001
Reference: JMIC 2269

To appear in: *Micron*

Received date: 20-10-2015
Revised date: 5-1-2016
Accepted date: 5-1-2016

Please cite this article as: Khan, Malik Arshman, Addison, Owen, James, Alison, Hendriksz, Christian J., Al-Jawad, Maisoon, Synchrotron X-ray Diffraction And Scanning Electron Microscopy To Understand Enamel Affected By Metabolic Disorder Mucopolysaccharidosis.Micron http://dx.doi.org/10.1016/j.micron.2016.01.001

Synchrotron X-ray Diffraction And Scanning Electron Microscopy To Understand Enamel Affected By Metabolic Disorder Mucopolysaccharidosis

Malik Arshman Khan[a*] arshman.khan86@gmail.com, Owen Addison[b], Alison James[c], Christian J. Hendriksz[d], Maisoon Al-Jawad[a]

[a]Queen Mary University of London, Barts and the London School of Medicine and Dentistry, Institute of Dentistry, London E1 4NS, UK

[b]University of Birmingham, School of Dentistry, Birmingham B4 6NN, UK

[c]Birmingham Children's Hospital NHS Foundation Trust, Birmingham, B4 6NH, UK

[d]Manchester Academic Health Science Centre, The Mark Holland Metabolic Unit, Salford Royal Foundation NHS Trust, Ladywell NW2-2nd Floor Room 112, Salford, Manchester. M6 8HD, UK

[*]Corresponding author at: Abbottabad International Medical College (Dental Section), Mansehra Road, P.O Public School, Abbottabad, Pakistan. Contact Number: +923335117505.

Highlights

- Mucopolysaccharidosis (MPS) is an inherited metabolic disorder.
- Synchrotron X-ray Diffraction and Scanning Electron Microscopy have been used to study normal dental enamel and dental enamel affected by Mucopolysaccharidosis (MPS).
- Presence of a partially calcified layer between the enamel and dentine at the EDJ (Enamel Dentine Junction) in a MPS affected tooth can cause the tooth to become weak and fracture whereas scalloping of EDJ seen in a normal tooth allows the tooth structure to become more stable and resist fracture.

Abstract

Mucopolysaccharidosis (MPS) is an inherited metabolic disorder that can affect the tooth structure leading to defects. Synchrotron x-ray diffraction being a state of the art technique has been used to determine the enamel crystallite orientation in deciduous enamel affected by Mucopolysaccharidosis Type I and Mucopolysaccharidosis Type IVA and comparing these with that of healthy deciduous enamel. Using this technique it was observed that there is a loss of texture in deciduous enamel affected by Mucopolysaccharidosis Type I and Mucopolysaccharidosis Type IVA when compared to the healthy deciduous enamel. Generally it was observed that the incisal surface of the deciduous teeth possessed a higher texture or preferred orientation of enamel crystallites and on progression towards the cervical region there was a decrease in the texture or preferred orientation of enamel crystallites. Scanning electron microscopy showed that the presence of a poorly calcified layer between the enamel and dentine at the enamel-dentine junction (EDJ) in MPS affected samples was likely to be responsible for rendering the tooth structure weak and prone to fracture as is often the case in MPS affected deciduous enamel.

Keywords: Synchrotron X-ray diffraction; Scanning electron microscopy; Enamel; Mucopolysaccharidosis; Preferred orientation; Morquio syndrome.

1. Introduction

Enamel being a hard and mineralized tissue can undergo metabolic disturbances during developmental stages of the tooth that can lead to the disorientation of enamel crystallites and cause defects in the structure of enamel. One of the rare metabolic disorders affecting the enamel structure is mucopolysaccharidosis (MPS) which has been classified into seven types(James et al., 2011). This study focuses on two types of MPS known as MPS I (Hurler syndrome)and MPS IVA also known as Morquio's syndrome. In both of these types of MPS, deficiency of an enzyme responsible for the breakdown of glyscosaminoglycans (GAGs) results in a build up GAGs that affects the crystallite structure of enamel.

MPS I (Hurler syndrome) has a prevalence of 1 in 100,000 and is characterized by the deficiency of an enzyme known as Alpha L Iduronidase which is responsible for the degradation of GAGs such as heparin sulphate and dermatan sulphate. The accumulation of GAGs due to the enzyme deficiency leads to among other things intellectual disability, joint disease and cardiomyopathy (Neufeld and Muenzer, 1995). On the other hand MPS IVA (Morquio A syndrome) is an autosomal recessive disorder with a prevalence of 1 in 170,000 live births (Meikle et al., 1999) and is caused by the deficiency of N-Acetylgalactosamine 6 Sulphatase (GALNS) (Baker et al., 1993,Masuno et al., 1993,Hendriksz et al., 2014,Leadley et al., 2014). MPS IVA is the only type of MPS that is known to be associated with defects in the enamel structure (Witkop and Sauk, 1976) although there is accumulation of GAGs in the dental follicle of developing teeth in the cases of MPS I (Hurler syndrome) and MPS II (Hunter syndrome)(Worth, 1966, Gardner, 1971). In MPS IVA significant malformations in the enamel structure are seen. The enamel is thin, pitted, dull gray in colour and has the tendency to flake off from the underlying dentine. The enamel being hypoplastic in nature has a normal radiodensity and hardness (Garn and Hurme, 1952,Rølling et al., 1999). This study, by making use of a combination of synchrotron X-ray diffraction and scanning electron microscopy, aims to determine the structure at multiple length-scales (from the crystallographic to the microstructure of the enamel deciduous teeth affected by the MPS I and MPS IVA and to compare these with healthy deciduous enamel.

2. Materials and Methods

2.1 Specimen preparation

The samples used in this study were deciduous maxillary central incisors which were collected from individuals affected by different types of mucopolysaccharidosis specifically MPS I and MPS IVA, and from healthy type-matched control individuals. The specimens were collected following ethical approval (UK National Research Ethics Service Reference 08/H1202/119) and consent at the Birmingham Children's Hospital NHS Foundation Trust, Birmingham, United Kingdom. The extracted teeth were stored in 4% thymol-saline solution in order to preserve hydration and prevent bacterial growth. The tooth samples were cut labio-lingually into longitudinal sections of 0.5mm thickness using a diamond blade cutter (Accutom-5, Struers A/S, Ballerup, Denmark) in order to carry out the synchrotron x-ray diffraction experiment. The scanning electron microscope used was field emission analytical SEM, Inspect F (FEI, Eindhoven, The Netherlands), operated at 10 kV with a 10 mm working distance.

Furthermore the same samples were prepared to be observed under scanning electron microscope (SEM). Firstly the samples were polished using wet silicon carbide paper at 600, 1200, 2400 and 4000 grit-sizes to remove the cutting marks. The samples were then etched in 35% orthophosphoric acid for 15 seconds in order to remove the smear layer and then rinsed in distilled water. Dehydration of the samples was carried out in graded ethanol 30-90% with a 30 minutes change for each concentration, further dehydration was carried out in 3 changes of absolute ethanol with 30 minutes each change. The samples were left to dry in a dessicator under vacuum overnight and later coated with carbon to prevent electrostatic charging when seen under the scanning electron microscope.

2.2 Experimental Procedure

2D X-ray diffraction patterns were collected on the XMaS beamline (BM28) at the European Synchrotron Radiation Facility (ESRF) situated in Grenoble, France. The prepared samples were mounted onto the travelling platform in order to attain a perpendicular direction to the beam. The sample to detector distance was 170mm and an X-ray wavelength of 0.82 Å was used. A beam spot size of 150 μm was used with a run time of 5 seconds to collect images using the MAR CCD detector.

2.3 Data Analysis

The diffraction images of enamel collected from all the samples were processed by the Fit2d software (Hammersley., 1994). The azimuthal variation in intensity around the Debeye ring of the 002 Bragg reflection present in the diffraction image was used to determine the degree of texture in enamel. A Gaussian peak shape and the values of full width half maximum (FWHM) were determined. This indicates the level of preferred orientation in enamel where low values of FWHM represent high preferred orientation and vice versa. The (FWHM) values for all the diffraction images were assembled to create 2D spatial texture maps.

3. Results

Figure 1 shows two scanning electron micrographs and a texture map taken from a healthy deciduous maxillary central incisor. Figure 1a shows the texture map with a colour-scale for the FWHM values and schematic of the outline shape of the healthy maxillary central incisor. The incisal surface and the labial aspect are represented by the two red arrows. The colour-scale for the FWHM values indicates the degree of preferred orientation or the texture of enamel. A high value of FWHM suggests that there is low enamel texture or low degree of preferred orientation in the enamel crystallites whereas a low value of FWHM suggests that there is high enamel texture or high degree of preferred orientation in the enamel crystallites. In Figure 1a there is a high degree of preferred orientation of enamel crystallites at the incisal surface compared to the cervical region which is marked by a red box. These findings were confirmed by the scanning electron micrograph in Figure 1b which showed that the enamel prisms were almost parallel to the long axis of tooth compared to the enamel prisms in the cervical region (marked by a red box in the texture map) in the scanning electron micrograph in Figure 1c,the enamel prisms being not parallel to the long axis of tooth. Figure 1.1 shows the scanning electron micrograph of healthy deciduous maxillary central incisor at a lower magnification.

Figure 2 shows two scanning electron micrographs and a texture map taken from a MPS IVA affected maxillary central deciduous incisor. Figure 2a shows a texture map showing the incisal surface, labial aspect and lingual aspect marked by red arrows and the cervical region marked by a red box. Figure 2b shows the scanning electron micrograph of the cervical region marked by a red box in the texture map as well as in the scanning electron micrograph.

Figure 2c shows the scanning electron micrograph of the same cervical region at a higher magnification . Figure 2.1 shows the scanning electron micrograph of MPS IVA affected maxillary central deciduous incisor at a lower magnification.

Figure 3 shows two texture maps and two scanning electron micrographs taken from a MPS I affected deciduous maxillary central incisor. Figure 3a shows a texture map showing the incisal and labial surface whereas Figure 3b shows a texture map showing the lingual surface of MPS I affected deciduous maxillary central incisor. Figure 3c shows a scanning electron micrograph of the incisal surface whereas Figure 3d shows a scanning electron micrograph of the lingual surface of MPS I affected deciduous maxillary central incisor. Figure 3.1 shows the scanning electron micrograph of MPS I affected deciduous maxillary central incisor at a lower magnification.

Figure 4 shows three scanning electron micrographs, Figure 4a showing the EDJ of a healthy maxillary deciduous incisor, Figure 4b showing the EDJ of a MPS IVA affected deciduous maxillary central incisor and Figure 4c showing the EDJ of a MPS I affected deciduous maxillary central incisor. The white arrows indicate the integration between the enamel and dentine at the EDJ.

4. Discussion

Our study shows that the incisal enamel surface of the healthy deciduous maxillary central incisor has higher texture or preferred orientation of enamel crystallites compared to the cervical region marked by a red box as shown in Figure 1a, this finding is supported by the scanning electron micrographs as Figure 1b shows that the enamel prisms at the incisal surface are well oriented and aligned indicative of a high enamel texture or preferred orientation whereas in Figure 1c the cervical region has a low enamel texture or preferred orientation compared to the incisal surface as the enamel prisms are not parallel to the long axis of the tooth unlike the enamel prisms at the incisal surface. The results for the healthy deciduous enamel are supported by a previous study conducted on permanent dentition which suggests that the enamel crystallites present in the cuspal regions are well aligned but as there is progression deeper in to the enamel away from the surface the enamel crystallites become less ordered (Al-Jawad et al., 2007).

Figure 2a shows the area of interest being the cervical region marked by a red box which shows immense loss of enamel texture in MPS IVA affected deciduous maxillary central incisor and furthermore this finding is confirmed by Figure 2b showing a scanning electron micrograph of the same cervical region at 5000x and Figure 2c showing a scanning electron micrograph of the same cervical region at a higher magnification of 20000x. The loss of prismatic structure with few enamel crystallites is quite evident at the cervical region as shown by Figure 2c. The loss of prismatic structure allows the enamel to be hypoplastic which means that the enamel is hard but thin. A thin layer of enamel indicates that there is a disturbance in the process of development during the secretory stage of amelogenesis (enamel formation) when the elongation of the enamel crystallites increase the thickness of the enamel layer as a whole. In case of maturation stage of amelogenesis in which the enamel crystallites grow in width and thickness, any disturbance in this stage will result in the formation of soft enamel with normal thickness and reduced radiopacity. As the radiodensity and hardness of enamel affected by MPS IVA appears to be normal, this indicates that the maturation stage of amelogenesis is not affected. Apart from this a partial or incomplete defect occurring in the secretory stage of amelogenesis may still achieve enamel of normal hardness due to the ease with which the maturation of a thin enamel layer takes place in comparison to a thicker layer. Hence it is believed that the pathogenesis leading to enamel defects in MPS IVA occurs in the secretory stage of amelogenesis (Yamakoshi et al., 2002, Smith, 1998).

Figure 3a shows that the labial surface of the MPS I affected deciduous maxillary central incisor tends to have a consistent enamel texture which is confirmed by the scanning electron micrograph in Figure 3c whereas in Figure 3b the lingual surface shows varying texture with a higher texture present at the cingulum area and this finding is supported by Figure 4d which shows aligned enamel prisms in the cingulum area. We believe that the cingulum area must have had a better enamel texture or preferred orientation of enamel crystallites as it is a region of high stress which bears load or occlusal forces the moment the deciduous mandibular central incisor comes in contact with the deciduous maxillary central incisor.

Figure 4a shows the healthy deciduous enamel in which there is a close integration of enamel and dentine at the EDJ (Enamel-Dentine Junction) as indicated by the two white arrows and a scalloped EDJ can also be seen which allows the enamel to properly adhere to the dentine surface leading to the stability of the tooth structure. In case of MPS IVA and MPS I affected deciduous enamel as shown in Figure 4b and Figure 4c respectively there are microgaps present between the enamel and dentine at the EDJ as indicated by the two white arrows and a layer can be seen between the enamel and dentine at the EDJ and no scalloping is seen

which suggests that the enamel is prone to detach from the underlying dentine rendering the tooth structure unstable. These findings are supported by Lustmann's study which suggests that a thin layer of amorphous material rich in organic matrix separates the enamel and dentine surfaces from each other and due to the defective metabolism of mucopolysaccharides in mucopolysaccharidosis this layer contains amorphous material and is partially calcified (Lustmann, 1978, Meckel et al., 1965).

5. Conclusion

Our study suggests that in health the enamel texture or preferred orientation of enamel crystallites in the incisal region is higher than in the cervical region and the regions away from the enamel surface. When it comes to comparison, healthy deciduous enamel has the highest enamel texture or preferred orientation overall whereas MPS I and MPS IVA affected deciduous enamel show low enamel texture or preferred orientation overall indicating that the GAGs play an important role in causing loss of enamel texture, leading to defects in the enamel texture.

Acknowledgements

This work was performed on the ESPRC-funded XMaS beamline at the ESRF, directed by M.J. Cooper, C.A Lucas and T.P.A Hase. We are grateful to the beamline team of S.D. Brown, O. Bikondoa, D. Wermeille, L. Bouchenoire and P. Thompson for their invaluable assistance and to S. Beaufoy and J. Kervin for additional support.

References

Al-Jawad, M., Streuwer, A., Kilcoyne, S.H., Shore, R.C., Cywinski, R.,2007. 2D mapping of texture and lattice parameters of dental enamel. Biomaterials 28, 2908-2914.

Baker, E., Guo, X. H., Orsborn, A. M., Sutherland, G. R., Callen, D. F., Hopwood, J. J. & Morris, C. P. 1993. The morquio A syndrome (mucopolysaccharidosis IVA) gene maps to 16q24.3. Am J Hum Genet, 52**,** 96-98.

Gardner, D. G. 1971. The oral manifestations of Hurler's syndrome. Oral Surg Oral Med Oral Pathol, 32**,** 46-57.

Garn, S. & Hurme, V. 1952. Dental defects in three siblings afflicted with Morquio's disease., 93,210-212.

Hammersley AP, 1994. FIT2D: an introduction and overview. ESRF Internal Report; ESRF97HA02T.

Hendriksz CJ, Berger KI, Giugliani R, Harmatz P, Kampmann C, Mackenzie WG, Raiman J, Villarreal MS, Savarirayan R. 2014. International guidelines for the management and treatment of Morquio A syndrome. Am J Med Genet Part A 9999A:1–15.

James, A., Hendriksz, C., Addison, O., 2011. The oral health needs of children, adolescents and young adults affected by a mucopolysaccharide (MPS) disorder. J. Inherit. Metab. Dis. (in press).

Leadley RM, Lang S, Misso K, Bekkering T, Ross J, Akiyama T, Fietz M, Giugliani R, Hendriksz CJ, Hock NL, Mcgill J, Olaye A, Jain M, Kleijnen J. 2014. A systematic review of the prevalence of Morquio A syndrome: challenges for study reporting in rare diseases. Orphanet Journal of Rare Diseases, 9:173.

Lustmann, J. 1978. Dentinoenamel junction area in primary teeth affected by Morquio's syndrome. J Dent Res, 57**,** 475-479.

Meikle, P. J., Hopwood, J. J., Clague, A. E. & Carey, W. F. 1999. Prevalence of lysosomal storage disorders. JAMA, 281**,** 249-254.

Masuno, M., Tomatsu, S., Nakashima, Y., Hori, T., Fukuda, S., Masue, M., Sukegawa, K. & Orii, T. 1993. Mucopolysaccharidosis IV A: assignment of the human N-

acetylgalactosamine-6-sulfate sulfatase (GALNS) gene to chromosome 16q24. Genomics, 16**,** 777-778.

Meckel, A. H., Griebstein, W. J. & Neal, R. J. 1965. Structure of mature human dental enamel as observed by electron microscopy. Arch Oral Biol, 10**,** 775-783.

Neufeld & Muenzer., 1995. The mucopolysaccharidoses.In: Scriver CR, Beaudet AL, Sly WS, Valle D, eds. The metabolic and molecular basis of inherited disease,2465-2494.

Rølling, I., Clausen, N., Nyvad, B. & Sindet-Pedersen, S. 1999. Dental findings in three siblings with Morquio's syndrome. Int J Paediatr Dent, 9**,** 219-24.

Smith, C. E. 1998. Cellular and chemical events during enamel maturation. Crit Rev Oral Biol Med, 9**,** 128-161.

Witkop, C. J. & Sauk, J. J. 1976. Heritable defects of enamel.In: Oral Facial Genetics, R.E. Stewart, and G.H. Prescott.*C.V.* Mosby,151-226.

Worth, H. M. 1966. Hurler's syndrome. A study of radiologic appearances in the jaws. Oral Surg Oral Med Oral Pathol, 22**,** 21-35.

Yamakoshi, Y., Hu, J. C., Liu, S., Sun, X., Zhang, C., Oida, S., Fukae, M. & Simmer, J. P. 2002. Porcine N-acetylgalactosamine 6-sulfatase (GALNS) cDNA sequence and expression in developing teeth. Connect Tissue Res, 43**,** 167-175.

Figure Captions

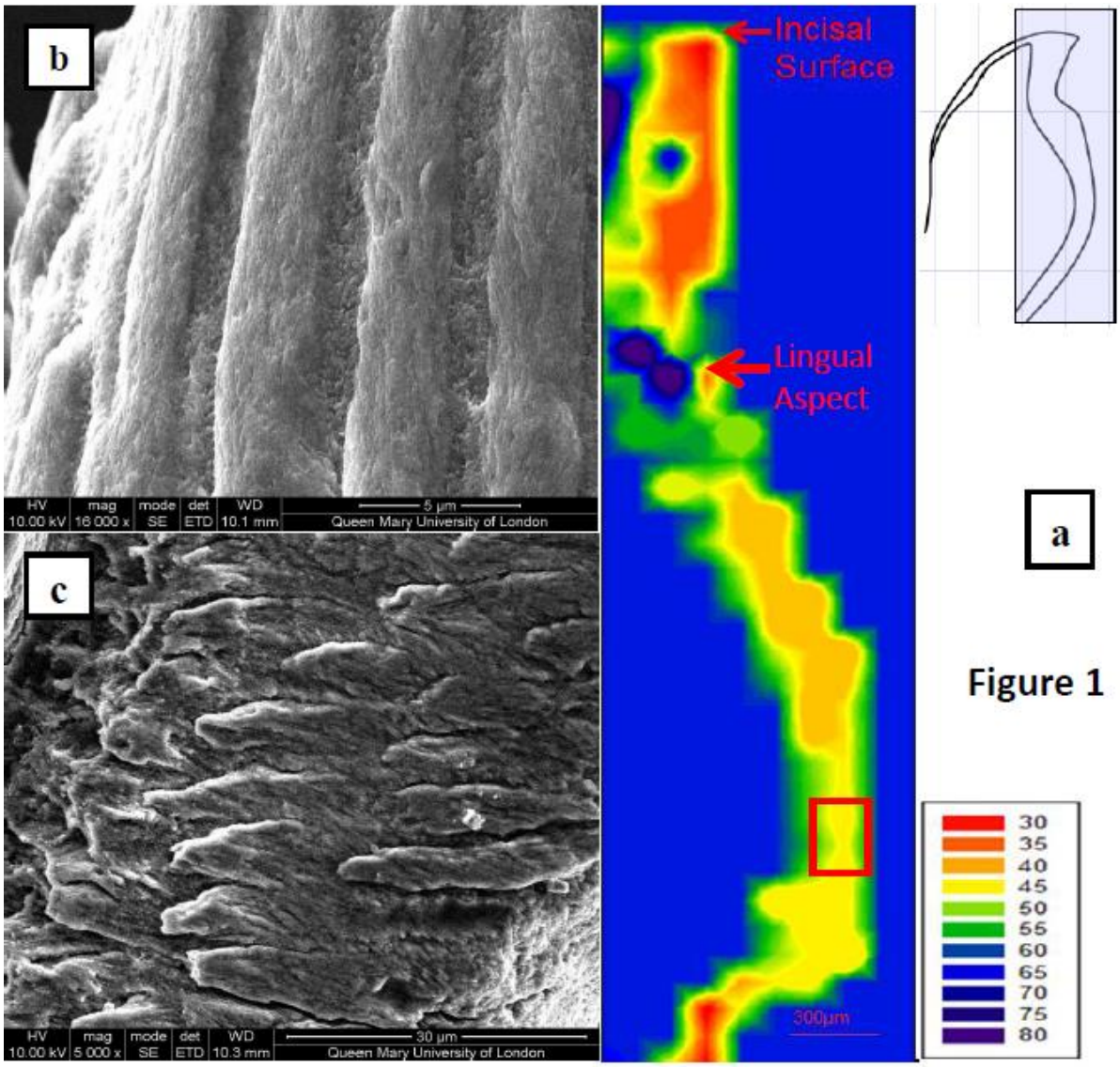

Figure 1: showing two scanning electron micrographs and a texture map of a healthy deciduous maxillary central incisor. Figure 1a showing the incisal and lingual surface marked by red arrows and a specific part of cervical region marked by a red box. Figure 1b showing the enamel prisms orientation at the incisal surface for the same tooth whereas Figure 1c shows the enamel prisms orientation in the specific part of cervical region marked by a red box in the texture map.



Figure 1.1: showing a scanning electron micrograph of deciduous maxillary central incisor at a lower magnification.



Figure 2: showing two scanning electron micrographs and a texture map of a MPS IVA affected deciduous maxillary central incisor. Figure 2a showing the incisal, lingual and labial surfaces marked by red arrows and a specific part of cervical region marked by a red box.



Figure 2.1: showing a scanning electron micrograph of MPS IVA affected deciduous maxillary central incisor at a lower magnification.

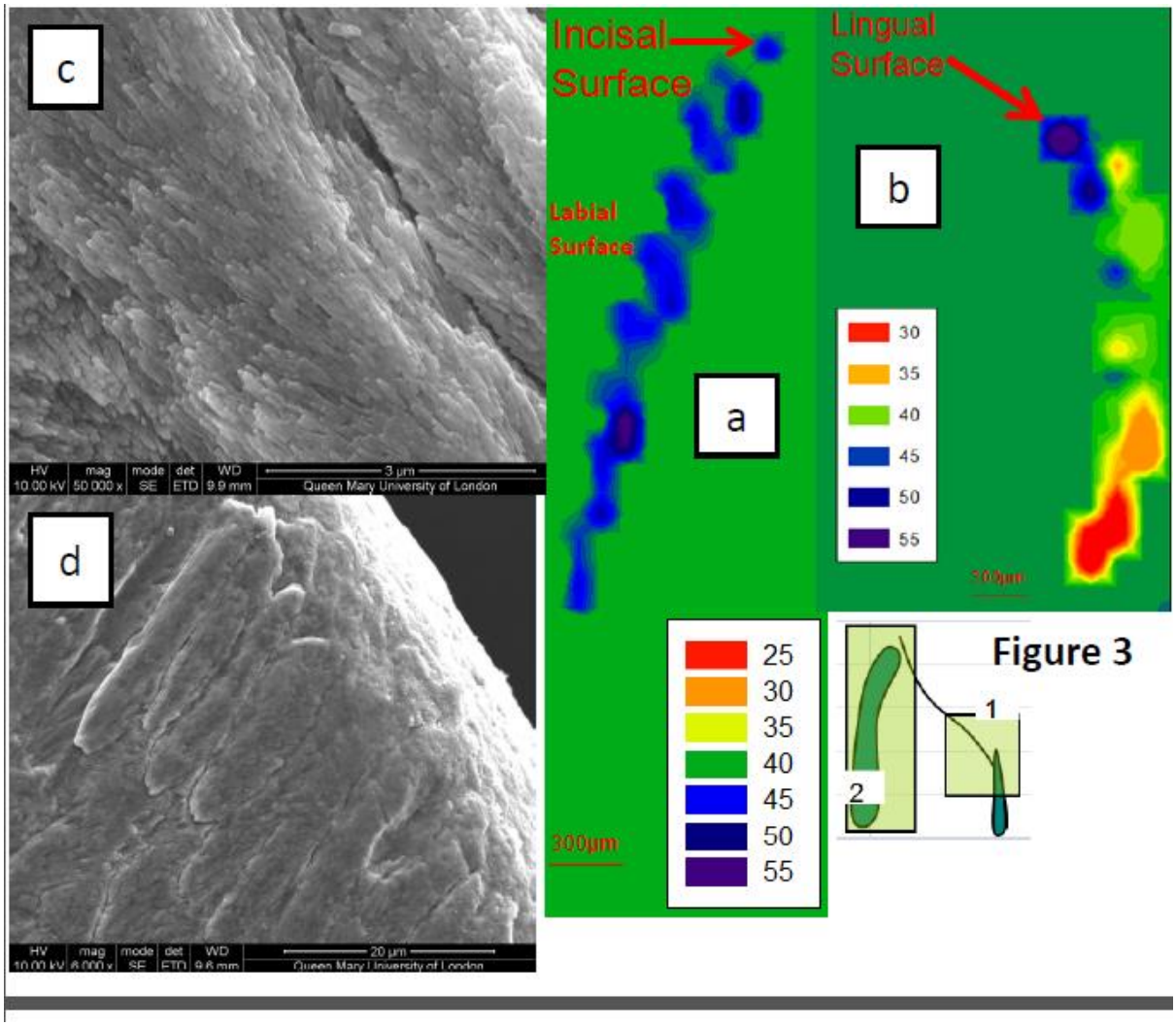

Figure 3: showing two scanning electron micrographs and two texture maps of MPS I affected deciduous maxillary central incisor. Figure 3a showing the incisal and labial surfaces marked by red arrows whereas Figure 3b shows the lingual surface of the same tooth. Figure 3c shows the enamel prisms orientation in the incisal and labial surface whereas Figure 3d shows the enamel prisms orientation in the cingulum area of the lingual surface.



Figure 3.1: showing a scanning electron micrograph of MPS I affected deciduous maxillary central incisor at a lower magnification.

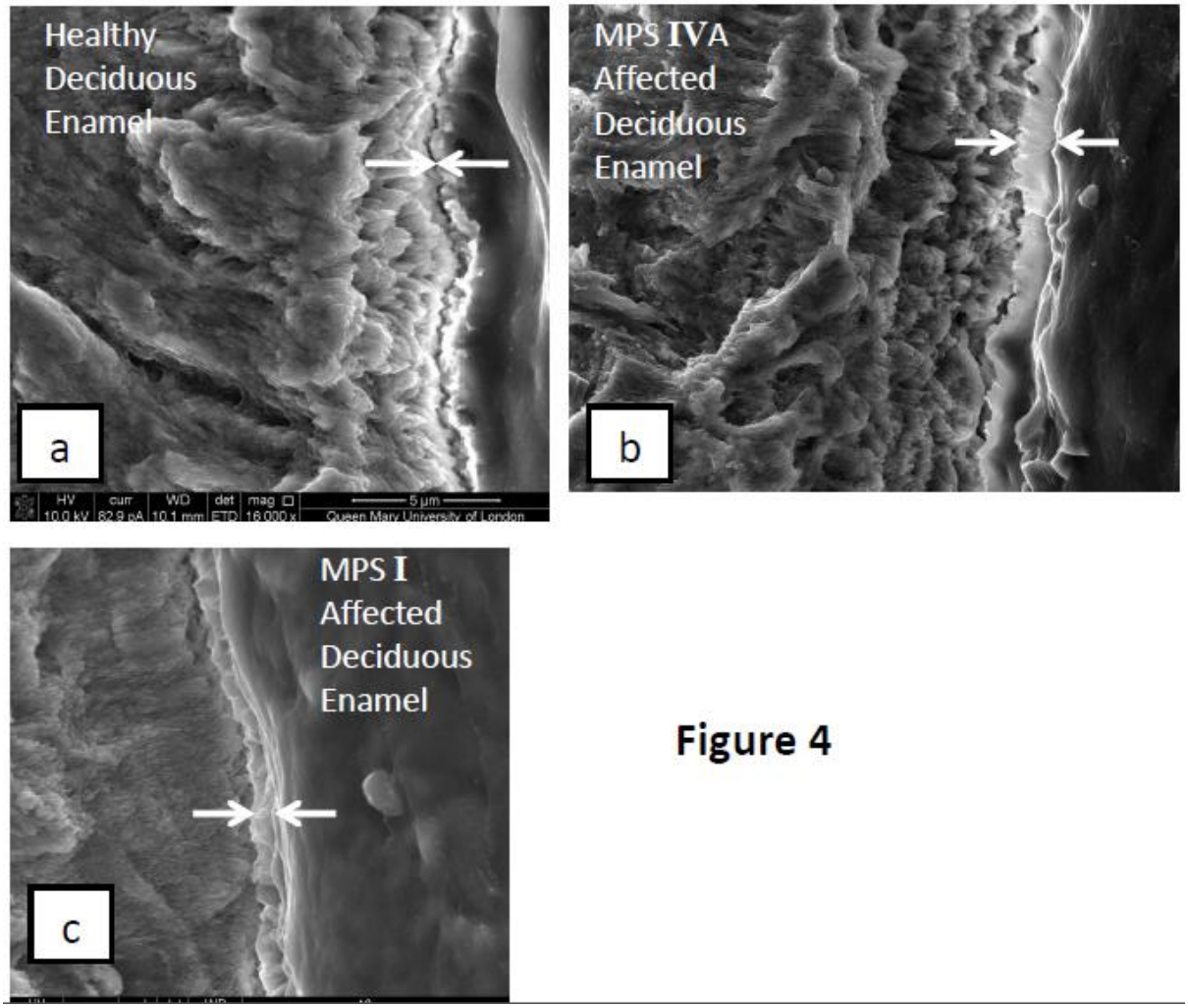

Figure 4

Figure 4: shows three scanning electron micrographs. Figure 4a showing the EDJ of a normal deciduous maxillary central incisor marked by white arrows, Figure 4b and 4c show the EDJ of MPS IVA and MPS I affected deciduous maxillary central incisors respectively, marked by white arrows.