UNIVERSITY OF BIRMINGHAM
University of Birmingham Research at Birmingham

Novel 3q27.2-qter deletion in a patient with Diamond-Blackfan anemia and immunodeficiency:

Alkhunaizi, Ebba; Schrewe, Brett; Alizadehfar, Reza; Vézina, Catherine; Stewart, Grant S.; Braverman, Nancy

DOI:
10.1002/ajmg.a.38208

License:
Other (please specify with Rights Statement)

Document Version
Peer reviewed version

Citation for published version (Harvard):
Alkhunaizi, E, Schrewe, B, Alizadehfar, R, Vézina, C, Stewart, GS & Braverman, N 2017, 'Novel 3q27.2-qter deletion in a patient with Diamond-Blackfan anemia and immunodeficiency: Case report and review of literature', *American Journal of Medical Genetics. Part A*, vol. 173, no. 6, pp. 1514-1520. https://doi.org/10.1002/ajmg.a.38208

Link to publication on Research at Birmingham portal

Publisher Rights Statement:
This is the peer reviewed version of the following article: Alkhunaizi E, Schrewe B, Alizadehfar R, Vézina C, Stewart GS, Braverman N. Novel 3q27.2-qter deletion in a patient with Diamond–Blackfan anemia and immunodeficiency: Case report and review of literature. Am J Med Genet Part A. 2017; 173A:1514–1520. https://doi.org/10.1002/ajmg.a.38208, which has been published in final form at 10.1002/ajmg.a.38208. This article may be used for non-commercial purposes in accordance with Wiley Terms and Conditions for Self-Archiving.

General rights
Unless a licence is specified above, all rights (including copyright and moral rights) in this document are retained by the authors and/or the copyright holders. The express permission of the copyright holder must be obtained for any use of this material other than for purposes permitted by law.

•Users may freely distribute the URL that is used to identify this publication.
•Users may download and/or print one copy of the publication from the University of Birmingham research portal for the purpose of private study or non-commercial research.
•User may use extracts from the document in line with the concept of 'fair dealing' under the Copyright, Designs and Patents Act 1988 (?)
•Users may not further distribute the material nor use it for the purposes of commercial gain.

Where a licence is displayed above, please note the terms and conditions of the licence govern your use of this document.

When citing, please reference the published version.

Take down policy
While the University of Birmingham exercises care and attention in making items available there are rare occasions when an item has been uploaded in error or has been deemed to be commercially or otherwise sensitive.

If you believe that this is the case for this document, please contact UBIRA@lists.bham.ac.uk providing details and we will remove access to the work immediately and investigate.

Download date: 26. Apr. 2023

Novel 3q27.2-qter Deletion in a Patient with Diamond-Blackfan Anemia and Immunodeficiency: Case Report and Review of Literature

Ebba Alkhunaizi[1], Brett Schrewe[2], Reza Alizadehfar[3], Catherine Vézina[4], Grant S. Stewart[5], Nancy Braverman[1]

1) Department of Medical Genetics and Pediatrics, McGill University Health Centre, Montreal, QC, Canada; 2) Department of Pediatrics, University of British Columbia, Vancouver, BC, Canada; 3) Department of Pediatric Allergy and Immunology, McGill University Health Centre, Montreal, QC, Canada; 4) Department of Pediatric Hematology and Oncology, McGill University Health Centre, Montreal, QC, Canada; 5) Institute for Cancer and Genomic Sciences, University of Birmingham, Birmingham, UK

Conflict of interest: none declared.

***Correspondence to:**

Ebba Alkhunaizi, 1001 Décarie Blvd

Montreal Children's Hospital, Block A, A043140.3, Montreal H4A3J1, QC, Canada

E-mail: ebba.alkhunaizi@mail.mcgill.ca

ABSTRACT:

3q27.2-qter deletion syndromes feature an overlapping set of terminal and interstitial deletions with variable congenital malformations. Diamond-Blackfan anemia (DBA) is etiologically heterogeneous disorder in which one cause is dominant mutations of the *RPL35A* gene on 3q29. We report a child with a 3q27.2-qter deletion that contains the *RPL35A* gene. She had clinical and laboratory features consistent with DBA and as well, an unexplained immunodeficiency disorder. Given these unusual findings, we reviewed other patients in the literature with overlapping genomic deletions. In addition, we evaluated our patient for the immunodeficiency disorder, RIDDLE syndrome, due to recessive mutations in the *RNF168* gene on 3q29.

A PubMed search for case reports of 3q27.2-qter overlapping deletions was performed. To determine if *RPL35A* was in the deletion region, the chromosomal regions reported were mapped to genomic regions using the UCSC Genome Browser. We identified 85 overlapping deletions, of which 6 included the *RPL35A* gene and all should be had DBA. Interestingly, none of the reported cases had immunodeficiency. To evaluate RIDDLE syndrome, we sequenced the remaining *RNF168* gene and examined her fibroblast culture for a DNA double strand break repair deficiency. These results were normal, indicating that the immunodeficiency is unlikely to result from a *RNF168* deficiency. We show that *RPL35A* haploinsufficiency is a cause of DBA and we report a novel case with 3q27.2-qter deletion and immunodeficiency. The etiology for the immunodeficiency remains unsolved and could be caused by an unknown gene effect or consequent to the DBA phenotype.

Key words: Diamond-Blackfan anemia; RIDDLE syndrome; 3q27.2-qter deletion; *RPL35A*; *RNF168*; immunodeficiency

INTRODUCTION:

3q27.2-qter deletion syndromes feature an overlapping set of terminal and interstitial deletions with variable congenital malformations, dysmorphic features and clinical manifestations. DBA (MIM# 105650) is a rare dominant congenital blood disorder that often manifests in the first two years of life with normochromic, macrocytic anemia and selective deficiency of red cell precursors due to absent erythroid progenitors in the bone marrow. The diagnosis of DBA is based on clinical and laboratory diagnostic criteria, that include: (1) age younger than one year, (2) macrocytic anemia with no other significant cytopenias, (3) reticulocytopenia and (4) normal marrow cellularity with a paucity of erythroid precursors. Supporting major criteria include: (1) a gene mutation described in classical DBA and (2) a positive family history. Supporting minor criteria include: (1) increased erythrocyte adenosine deaminase activity (eADA), (2) congenital anomalies described in classical DBA, (3) elevated hemoglobin F and (4) an absence of evidence of other bone marrow failure syndromes (Da Costa et al., 2010; Lipton and Ellis, 2010; Vlachos et al., 2008). Currently, DBA is due to defects causing haploinsufficiency in at least twelve genes that encode ribosomal proteins (Gazda et al., 2012), as well as the *GATA1* gene that encodes the hematopoietic transcription factor (Sankaran et al., 2012). One of these genes is *RPL35A* gene (MIM# 180468), which plays an essential role in rRNA processing, ribosome biogenesis, selective cell proliferation and apoptosis (Farrar et al., 2008). In this report, we present a patient with a *de novo* 12.594 Mb deletion of 3q27.2-qter that contains the *RPL35A* gene. Her clinical and laboratory features are consistent with that reported in this deletion and DBA but also include the unique feature of immunodeficiency. To investigate the cause of the immunodeficiency, we reviewed other patients in the English

literature with overlapping genomic deletions, sequenced the *RNF168* gene and examined her fibroblasts for a defect in DNA double strand break (DSB) repair.

MATERIALS AND METHODS:

We performed a search using PubMed database from 1984 until the present date using the search terms "Diamond-Blackfan anemia", "Ribosomopathy" and "*RPL35A*", "3q27 deletion", "3q27 microdeletion", "3q28 deletion", "3q28 microdeletion", "3q29 deletion" and "3q29 microdeletion". The established list of articles was chosen based on their relevance and scope. Our search found 85 cases with overlapping genomic deletions. These cases were reported by (Senzaki et al., 2003; Pollazzon et al., 2009; Alvarez Arratia et al., 1984; Farrar et al., 2008; Willatt et al., 2005; Krepischi-Santos et al., 2006; Li et al., 2009; Ballif et al., 2008; Monfort et al., 2008; Città et al., 2013; Tyshchenko et al., 2009; Quintero-Rivera et al., 2010; Quarello et al., 2012; Kuramitsu et al., 2012; Glassford et al., 2016). Genomic delineation of the deleted regions was determined using UCSC Genome Browser. Ethics approval was obtained according to institutional guidelines at the Montréal Children's Hospital. The parents also gave consent for full photographs, publication and fibroblast studies.

CLINICAL CASE:

A 9 year old girl, was born to non-consanguineous French-Canadian parents. The pregnancy was complicated by oligohydramnios and reduced fetal movement. She was born at 37 weeks; birth weight: 2346 grams (10th percentile), head circumference: 31 cm (10th percentile) and length: 46 cm (between 10th and 50th percentile). Her neonatal course was significant for transient hypoglycemia and indirect hyperbilirubinemia, which was treated with phototherapy. Five weeks after birth, she presented with failure to thrive that led to a diagnosis of coarctation of

the aorta and severe mitral stenosis, which was surgically repaired. At this time, there was severe anemia with hemoglobin of <56 g/L which required red blood cell transfusions. In addition, she was suspected to have Crohn's disease, based on both clinical and histological evidence; for this she was treated with steroids which were tapered and stopped in the first year of life without relapse. The hemoglobin level was stable during the period of steroid treatment. Furthermore, she had gastro-esophageal reflux disease which eventually required a Nissen fundoplication and gastrostomy because of insufficient oral intake and weight loss. In her first few years of life, she had multiple upper respiratory tract infections and pneumonias, the latter required multiple hospital admissions. At 5 years of age, she was started on weekly subcutaneous immunoglobulin for low immunoglobulin titers and this treatment eliminated further pneumonias. In term of development, she has motor and language delays. She started to walk and speak at around 3 years of age. She has expressive language delay with good receptive language skills. At 9 years, she has 15 single words. Her fine motor and social skills were age-appropriate.

At the time she was evaluated for her anemia and recurrent infections, around 4 years of age, laboratory investigations revealed hemoglobin < 56 g/L and macrocytic anemia [mean corpuscular volume 97 (75.0-87.0 fL)]. The white blood cell count, differentials and platelets were within normal limits. Serum ferritin, iron, and transferrin saturation, vitamin B12 and folate level were also normal. Hemoglobin F was elevated. A bone marrow aspiration showed a normocellular marrow with evidence of maturation and increased megalokaryocytes. There was, however, mildly decreased myelopoiesis and erythropoiesis with mild macronormoblastic features. Her blood type is O+ and direct Coombs testing was negative. Her initial B and T cell enumeration showed decreased overall CD8+ T cell count for age at 226 x 10^9/L (12%) (N: 22-38%) with an increased CD4+/CD8+ ratio at 5.1 (1.0-2.1). On her latest evaluation at 8 years, the

CD8+ T count remained low. However, her total T cell counts as well as CD4 T cell numbers remain normal. Although her initial B cell counts were normal, her recent counts were decreased at 123 x 10^9/L (>200 x 10^9/L). Immunoglobulin levels prior to immunoglobulin replacement therapy (IgRT) showed low IgG level at 3.0 (5.1-13.4 g/L), while IgM, IgE and IgA levels have remained within normal limits. She had a good protein vaccine response (diphtheria and tetanus) but a poor polysaccharide antigen response (Pneumovax) prompting IgRT in the context of her recurrent oto-sino-pulmonary infections. Although her T cell proliferation to mitogens were normal prior IgRT, with time she has had decreased T cell proliferative responses. Interestingly, she also has had decreased memory T cell subsets as well as switched memory B cells at 1%. Finally, her immunological phenotyping revealed an unexplained increase in her transitional CD4+ as well as CD8+ CD45+ RA+ (20% increase) and CD8+CD45+ RO+ (8% increase). She also had a normal functional evaluation of her classical and alternative pathways of the complement system. A karyotype at 650 band-resolution showed 46, XX. However, array comparative genomic hybridization (aCGH) revealed a *de novo*12.594 Mb deletion of 3q27.2-qter. Both parental aCGH analyses were normal. Additional biochemical tests showed normal urine organic acids, oligosaccharides, mucopolysaccharides. Transferrin isoelectric focusing showed a normal pattern of glycosylation. After her diagnosis of DBA at 5 years of age, she was started on steroid treatment and a remarkable improvement in her hematological profile was noted with no further blood transfusions. Family history was remarkable for a paternal grandmother with Sjögren syndrome and hypothyroidism. Also, a paternal aunt who died at 28 years in the context of CREST syndrome complications. In addition, a stillborn paternal female first cousin was reported. There was no history of anemia or immunodeficiency.

Physical examination at 9 years of age revealed the following growth parameters: weight: 17.8 kg (< 0.1 percentile = 50th percentile for 4.5 year), height 111 cm (< 0.1 percentile = 50th percentile for 5.5 year), head circumference 47 cm (< 2nd percentile = 50th percentile for 16 months). Pertinent findings on physical exam showed (Figure 1): hypertelorism with downward slanting palpebral fissures, bilateral lower lid ptosis, small mal-aligned ears with cleft earlobe on the left ear and Darwin's notch on the right ear, bulbous nasal tip, flat philtrum, thin upper lip, small mouth and a moderately-high arched palate. She also has short finger nails with proximally placed thumbs but no bifid or tri-phalangeal thumbs. Cutis marmorata was also noted.

RESULTS:

We identified 85 patients from the literature with deletions overlapping 3q27.2-qter (Table I). 6 cases overlapped with the *RPL35A* region and had DBA. All cases showed clinical manifestations that include craniofacial abnormalities, developmental delay, growth deficiencies and variable congenital malformations that likely correspond to the associated genomic deletion. However, there were no patients reported with immunodeficiency.

For the cases with DBA (Table I), two were reported by Farrar et al. (2008), one with a *de novo* 3q28-qter deletion and another with a 3q29 deletion. The first patient had anemia that responded to steroid treatment. He developed neutropenia, and had a bone marrow biopsy done that showed decreased myeloid maturation with mild dysplasia. He remained steroid dependent and subsequently developed persistent leukopenia. The second patient presented at 7 weeks of life with macrocytic anemia, reticulocytopenia, increased eADA activity and hemoglobin F levels and responded to steroid treatment. In these two patients, decreased expression of RPL35A transcripts was confirmed by quantitative RT-PCR (Farrar et al., 2008). Kuramitsu et al. (2012) reported one patient with an *RPL35A* gene deletion detected by semi-quantitative PCR

and confirmed by SNP arrays. This patient presented with multiple malformations including thumb anomalies, synostosis of radius and ulna, Cornelia de Lange-like facies, cleft palate, undescended testis, short stature, cerebellar hypoplasia and fetal hydrops. Quarello et al. (2012), identified 3 other cases with *RPL35A* gene deletions by multiplex ligation-dependent probe amplification (MLPA) assay and confirmed by RT-PCR analysis. All of these cases were identified on the basis of DBA features.

Although the Farrer et al. patient above developed neutropenia and leukopenia, the etiology was obscured by the concomitant steroid use. However, our patient was not on steroids at the time the immunodeficiency presented. We considered whether our patient had an autosomal recessive cause of immunodeficiency, involving a deleted gene together with a second mutation on the remaining gene. We reviewed genes in this region (76 OMIM genes) and identified only RIDDLE (radiosensitivity, immunodeficiency, dysmorphic features, and learning difficulties) syndrome, which is caused by recessive mutations in the *RNF168* gene at 3q29. The syndrome is associated with low immunoglobulin levels, short stature and developmental delay which were exhibited by our patient (Stewart et al., 2007). We sequenced the remaining *RNF168* gene and examined our patient's fibroblasts for an inability to delocalise DSB repair proteins to sites of ionizing radiation (IR) induced DNA damage (Figure 2). Defects in RNF168 result in a failure to form IR-induced 53BP1, BRCA1, RNF168 and poly-ubiquitin foci and elevated levels of γ-H2AX foci at late times during DNA repair (24h post-irradiation). The lack of any gene alterations in the remaining *RNF168* allele, normal IR-induced foci formation, and an absence of residual γ-H2AX foci at 24h post-irradiation indicates that our patient does not have any abnormalities in the RNF168-dependent DNA damage response. Thus, the underlying immunodeficiency is unlikely to result from a loss of RNF168 function.

DISCUSSION:

DBA is a rare autosomal dominant syndrome causing bone marrow failure and is classified as a ribosomopathy, along with Schwachman-Diamond syndrome (SDS), congenital hair hypoplasia (CHH), dyskeratosis congenita (DKC) and Treacher-Collins syndrome. Currently, DBA can be caused by mutations in at least 12 genes that encode ribosomal proteins can cause DBA (Gazda et al., 2012). Dominant mutations in *RPL35A* account for (~3%) of DBA cases (Farrar and Dahl, 2011).

We have shown that complete deletion of *RPL35A* can also cause DBA syndrome and was present in our patient as well as 6 other patients in the literature (Farrar et al., 2008; Quarello et al., 2012; Kuramitsu et al., 2012). The cases from the literature were identified by virtue of the patient being recognized with DBA, thus showing that complete gene deletions can underlie this disorder. In our patient, she was recognized first as having a 3q27.2-qter deletion, which then facilitated the correct diagnosis of her anemia. Considering the frequent use of aCGH as a diagnostic tool, these cases illustrate the co-occurrence of *RPL35A* deletions and DBA. We did not find any instances of an *RPL35A* deletion without the co-occurrence of DBA.

Although the cause of the DBA is clarified, the etiology of the immunodeficiency phenotype in our patient remains unsolved. The immune dysregulation in this case affected B-cell immunity most, requiring weekly subcutaneous IgRT, and to a lesser extent affecting T-cell immunity. A diagnosis of a specific antibody defect (specific polysaccharide antibody deficiency), or an atypical common variable immunodeficiency (with a decrease of only one immunoglobulin isotype) were considered in this patient.

We reviewed cases with overlapping deletions to identify whether an immunodeficiency phenotype has been associated with either the 12.594 Mb deletion or to the DBA. Although none of the reported overlapping deletion cases had features of an immunodeficiency disorder, there were 15 patients with recurrent ear infections (Table I) (Willatt et al., 2005; Ballif et al., 2008; Glassford et al., 2016). In the deletion region, *RNF168* gene (RIDDLE syndrome) at 3q29 was a potential candidate. However, testing for this disorder was normal.

Another possible, untested genomic mechanism contributing to the immunodeficiency in our patient is an epistatic effect on *LAMP3* (MIM# 605883), located at 3q27.1 approximately 2 Mb upstream from the deletion region. A role for *LAMP3* (lysosome-associated membrane protein 3) in the regulation of the immune system in a patient with 3q26.33-3q27.2 deletion was proposed as the cause of their recurrent infections and hypogammaglobulinemia (Dasouki et al., 2014).

We noted that the possibility of immunodeficiency as part of the DBA syndrome itself has been discussed in the literature. Finlay et al. (1982) evaluated the immunologic function in five patients with DBA by assessing lymphocyte enumeration, proliferation, suppression and growth of T cell colonies. Their investigations revealed a possible impairment of lymphocyte function that suggested involvement of the immune system. This was further investigated by Zivny et al. (2003) who studied hematopoietic progenitor differentiation *in vitro* and stem cell repopulation *in vivo* using samples from DBA patients and controls. This study demonstrated a defective erythroid, but normal lymphoid cell repopulation in DBA patients and attributed that to the underlying ribosomal biogenesis defects. Rochowski et al. (2011) proposed the possibility of altered immunologic function in patients with inherited bone marrow failure syndromes, including DBA. This was interrogated by comparing neutrophil functions in patients to those in

healthy family members. However, no differences in neutrophil stimulation and respiratory burst were demonstrated. In 2015, Giri et al. assessed the immunological parameters in 33 patients with DBA by evaluating complete blood counts, serum immunoglobulin levels (IgG, IgA and IgM) and lymphocyte phenotyping (T, B and NK cells) and compared these to unaffected first-degree relatives. Results showed that a minority of DBA patients had some parameters that were below the normal range, or below the range seen in the relatives. When this was adjusted to variables known to influence the immune response, no significant differences between the two groups were observed (Giri et al., 2015). Recently, a patient was reported with a clinical diagnosis of DBA and common variable immunodeficiency without a definite cause identified for the immune deficiency (Khan et al., 2011).

Finally, there is the possibility that this child has an additional diagnosis that has not yet been recognized, and could be investigated by whole genome/exome sequencing. Thus, the relationship between DBA and immunodeficiency remains unresolved and we contribute another case in which an immunodeficiency might be an underlying feature of the DBA itself.

CONCLUSION:

In summary, we have presented a 9 year old girl with a novel *de novo* 12.594 Mb deletion syndrome (3q27.2-qter). In addition to DBA due to *RPL35A* haploinsufficiency causing the DBA phenotype manifestation, she had an unexplained immunodeficiency. We propose that this is secondary to an unknown gene effect, or to the DBA phenotype itself. Finally, applying DBA diagnostic criteria is warranted with those patients who carry 3q terminal deletions that overlap with *RPL35A* genomic region.

ACKNOWLEDGEMENTS:

We thank the family for their participation in this article. The fibroblast studies were done in the laboratory of Dr. Grant Stewart, who is supported by CR-UK Senior Fellowship (C17183/A1303).

REFERENCES:

Alvarez Arratia MC, Rivera H, Möller M, Valdivia A, Vigueras A, Cantu JM. 1984. De novo del(3)(q2800). Annales De Génétique 27: 109–111.

Ballif BC, Theisen A, Coppinger J, Gowans GC, Hersh JH, Madan-Khetarpal S, Schmidt KR, Tervo R, Escobar LF, Friedrich CA, McDonald M, Campbell L, Ming JE, Zackai EH, Bejjani BA, Shaffer LG. 2008. Expanding the clinical phenotype of the 3q29 microdeletion syndrome and characterization of the reciprocal microduplication. Molecular Cytogenetics 1: 8.

Città S, Buono S, Greco D, Barone C, Alfei E, Bulgheroni S, Usilla A, Pantaleoni C, Romano C. 2013. 3q29 microdeletion syndrome: Cognitive and behavioral phenotype in four patients. American Journal of Medical Genetics. Part A 161A: 3018–3022.

Da Costa L, Moniz H, Simansour M, Tchernia G, Mohandas N, Leblanc T. 2010. Diamond-Blackfan anemia, ribosome and erythropoiesis. Transfusion Clinique et Biologique 17: 112–119.

Dasouki M, Roberts J, Santiago A, Saadi I, Hovanes K. 2014. Confirmation and further delineation of the 3q26.33–3q27.2 microdeletion syndrome. European Journal of Medical Genetics 57: 76–80.

Farrar JE, Dahl N. 2011. Untangling the Phenotypic Heterogeneity of Diamond Blackfan Anemia. Seminars in Hematology 48: 124–135.

Farrar JE, Nater M, Caywood E, McDevitt MA, Kowalski J, Takemoto CM, Talbot CC, Meltzer P, Esposito D, Beggs AH, Schneider HE, Grabowska A, Ball SE, Niewiadomska E, Sieff CA, Vlachos A, Atsidaftos E, Ellis SR, Lipton JM, Gazda HT, Arceci RJ. 2008. Abnormalities of the large ribosomal subunit protein, Rpl35a, in Diamond-Blackfan anemia. Blood 112: 1582–1592.

Finlay JL, Shahidi NT, Horowitz S, Borcherding W, Hong R. 1982. Lymphocyte dysfunction in congenital hypoplastic anemia. Journal of Clinical Investigation 70: 619–626.

Gazda HT, Preti M, Sheen MR, O'Donohue M-F, Vlachos A, Davies SM, Kattamis A, Doherty L, Landowski M, Buros C, Ghazvinian R, Sieff CA, Newburger PE, Niewiadomska E, Matysiak M, Glader B, Atsidaftos E, Lipton JM, Gleizes P-E, Beggs AH. 2012. Frameshift mutation in p53 regulator RPL26 is associated with multiple physical abnormalities and a specific pre-rRNA processing defect in Diamond-Blackfan anemia. Human Mutation 33: 1037–1044.

Giri N, Alter BP, Penrose K, Falk RT, Pan Y, Savage SA, Williams M, Kemp TJ, Pinto LA. 2015. Immune status of patients with inherited bone marrow failure syndromes. American Journal of Hematology 90: 702–708.

Glassford MR, Rosenfeld JA, Freedman AA, Zwick ME, Unique Rare Chromosome Disorder Support Group, Mulle JG. 2016. Novel features of 3q29 deletion syndrome: Results from the 3q29 registry. American Journal of Medical Genetics Part A 170: 999–1006.

Khan S, Pereira J, Darbyshire PJ, Holding S, Doré PC, Sewell WAC, Huissoon A. 2011. Do ribosomopathies explain some cases of common variable immunodeficiency? Clinical and Experimental Immunology 163: 96–103.

Krepischi-Santos ACV, Vianna-Morgante AM, Jehee FS, Passos-Bueno MR, Knijnenburg J, Szuhai K, Sloos W, Mazzeu JF, Kok F, Cheroki C, Otto PA, Mingroni-Netto RC, Varela M, Koiffmann C, Kim CA, Bertola DR, Pearson PL, Rosenberg C. 2006. Whole-genome array-CGH screening in undiagnosed syndromic patients: old syndromes revisited and new alterations. Cytogenetic and Genome Research 115: 254–261.

Kuramitsu M, Sato-Otsubo A, Morio T, Takagi M, Toki T, Terui K, Wang R, Kanno H, Ohga S, Ohara A, Kojima S, Kitoh T, Goi K, Kudo K, Matsubayashi T, Mizue N, Ozeki M, Masumi A, Momose H, Takizawa K, Mizukami T, Yamaguchi K, Ogawa S, Ito E, Hamaguchi I. 2012. Extensive gene deletions in Japanese patients with Diamond-Blackfan anemia. Blood 119: 2376–2384.

Li F, Lisi EC, Wohler ES, Hamosh A, Batista DAS. 2009. 3q29 interstitial microdeletion syndrome: An inherited case associated with cardiac defect and normal cognition. European Journal of Medical Genetics 52: 349–352.

Lipton JM, Ellis SR. 2010. Diamond Blackfan anemia 2008 – 2009: Broadening the scope of ribosome biogenesis disorders. Current opinion in pediatrics 22: 12–19.

Monfort S, Roselló M, Orellana C, Oltra S, Blesa D, Kok K, Ferrer I, Cigudosa JC, Martínez F. 2008. Detection of known and novel genomic rearrangements by array based comparative genomic hybridisation: deletion of ZNF533 and duplication of CHARGE syndrome genes. Journal of Medical Genetics 45: 432–437.

Pollazzon M, Grosso S, Papa FT, Katzaki E, Marozza A, Mencarelli MA, Uliana V, Balestri P, Mari F, Renieri A. 2009. A 9.3Mb microdeletion of 3q27.3q29 associated with psychomotor and growth delay, tricuspid valve dysplasia and bifid thumb. European Journal of Medical Genetics 52: 131–133.

Quarello P, Garelli E, Brusco A, Carando A, Mancini C, Pappi P, Vinti L, Svahn J, Dianzani I, Ramenghi U. 2012. High frequency of ribosomal protein gene deletions in Italian Diamond-Blackfan anemia patients detected by multiplex ligation-dependent probe amplification assay. Haematologica 97: 1813–1817.

Quintero-Rivera F, Sharifi-Hannauer P, Martinez-Agosto JA. 2010. Autistic and psychiatric findings associated with the 3q29 microdeletion syndrome: Case report and review. American Journal of Medical Genetics Part A 152A: 2459–2467.

Rochowski A, Sun C, Glogauer M, Alter BP. 2011. Neutrophil functions in patients with inherited bone marrow failure syndromes. Pediatric Blood & Cancer 57: 306–309.

Sankaran VG, Ghazvinian R, Do R, Thiru P, Vergilio J-A, Beggs AH, Sieff CA, Orkin SH, Nathan DG, Lander ES, Gazda HT. 2012. Exome sequencing identifies GATA1 mutations resulting in Diamond-Blackfan anemia. The Journal of Clinical Investigation 122: 2439–2443.

Senzaki H, Inui M, Ban S, Masutani S, Morsy M, Kobayashi T, Nagasaka H, Sasaki N, Kyo S, Yokote Y. 2003. Dilated cardiomyopathy in a 3-year-old girl with a terminal deletion, 46, XX, del (3)(q27-qter), of the long arm of chromosome 3. European journal of pediatrics 162: 403–405.

Stewart GS, Stankovic T, Byrd PJ, Wechsler T, Miller ES, Huissoon A, Drayson MT, West SC, Elledge SJ, Taylor AMR. 2007. RIDDLE immunodeficiency syndrome is linked to defects in 53BP1-mediated DNA damage signaling. Proceedings of the National Academy of Sciences of the United States of America 104: 16910–16915.

Tyshchenko N, Hackmann K, Gerlach E-M, Neuhann T, Schrock E, Tinschert S. 2009. 1.6 Mb deletion in chromosome band 3q29 associated with eye abnormalities. European Journal of Medical Genetics 52: 128–130.

Vlachos A, Ball S, Dahl N, Alter BP, Sheth S, Ramenghi U, Meerpohl J, Karlsson S, Liu JM, Leblanc T, Paley C, Kang EM, Leder EJ, Atsidaftos E, Shimamura A, Bessler M, Glader B, Lipton JM, on behalf of the participants of the Sixth Annual Daniella Maria Arturi International Consensus Conference. 2008. Diagnosing and treating Diamond Blackfan anaemia: results of an international clinical consensus conference. British Journal of Haematology 142: 859–876.

Willatt L, Cox J, Barber J, Cabanas ED, Collins A, Donnai D, FitzPatrick DR, Maher E, Martin H, Parnau J, Pindar L, Ramsay J, Shaw-Smith C, Sistermans EA, Tettenborn M, Trump D, de Vries BBA, Walker K, Raymond FL. 2005. 3q29 Microdeletion Syndrome: Clinical and Molecular Characterization of a New Syndrome. American Journal of Human Genetics 77: 154–160.

Zivny J, Jelinek J, Pospisilova D, Plasilova M, Necas E, Stopka T. 2003. Diamond blackfan anemia stem cells fail to repopulate erythropoiesis in NOD/SCID mice. Blood Cells, Molecules & Diseases 31: 93–97.

FIGURE LEGENDS:

Figure 1**:** 9 years old girl with 3q27.2-qter deletion showing (A) hypertelorism, down slanting palpebral fissures, sparse eyebrows, bilateral lower lid ptosis, bilateral Dennie–Morgan fold, bulbous nasal tip, flat philtrum, thin upper lip and mal-aligned ears. (B) Cleft earlobe on left ear. (C) Darwin's notch and tubercle on right ear. (D, E) Proximally placed thumbs with short finger nails. (F) Cutis marmorata.

Figure 2: Functional immunofluorescent assays of our patient's fibroblasts to assess formation of RNF168 (A), BRCA1 (B), poly-ubiquitin (C), γ-H2AX (D) and 53BP1 (E) foci following exposure to ionizing radiation (IR). Our patient's fibroblasts form normal RNF168, BRCA1, poly-ubiquitin, γ-H2AX and 53BP1 foci following 3Gy of IR, similar to the normal fibroblast control cells.

[Color figure can be viewed in the online issue, which is available at http://onlinelibrary.wiley.com/journal/10.1002/(ISSN)1552-4833.]

TABLE:

Table I: Clinical and cytogenetic features reported in patients with 3q27.2-qter overlapping genomic deletion

Table I: Clinical and cytogenetic features reported in patients with 3q27.2-qter overlapping genomic deletion

Author	Senzaki et al., 2003	Pollazzon et al., 2009	Alvarez Arratia et al., 1984	Farrar et al., 2008		Willatt et al., 2005	Krepischi-santos et al., 2006	Li et al., 2009		Ballif et al., 2008	Monfort et al., 2008	Città et al., 2013	Tyshchenko et al., 2009	Quintero-Rivera et al., 2010	Quarello et al., 2012	Kuramitsu et al. 2012	(Glassford et al., 2016)	Our patient
Deletion region	3q27-qter del (N=1)	3q27.3-3q29 del (N=1)	3q28 del (N=1)	3q28-qter del (N=1)	3q29 del (N=1)	3q29 del (N=6)	3q29 del (N=1)	3q29 del (N=1-A)[1]	3q29 del (N=1-B)	3q29 del (N=14)	3q29 del (N=2)	3q29 del (N=4)	3q29 del (N=1)	3q29 del (N=2)	3q29 del[2] (N=3)	3q29 del[2] (N=1)	3q29 del[Δ] (N=44)	3q27.2-qter del (N=1)
RPL35A deletion	-	-	-	+	+	-	-	-	-	-	-	-	-	-	3/3	+	-	+
DBA	-	-	-	+	+	-	-	-	-	-	-	-	-	-	3/3	+	-	+
Growth Delay	+	-	+	N/A	N/A	1/6	+	N/A	-	N/A	N/A	-	-	1/2	N/A	+	17/44	+
Short stature	+	-	N/A	N/A	N/A	1/6	+	N/A	-	N/A	N/A	-	-	1/2	N/A	+	N/A	+
Microcephaly	+	-	+	N/A	N/A	1/6	+	N/A	-	5/14	N/A	1/4	-	1/2	N/A	N/A	N/A	+
Developmental delay (mental, motor or speech)	+	+	+	+	N/A	6/6	+	+	-	+	+	4/4	+	2/2	N/A	N/A	17/42	+
Dysmorphic features																		
Eyes	+	+	+	+	N/A	1/6	+	N/A	+	N/A	+	4/4	+	1/2	N/A	N/A	N/A	+
Ears	+	+	N/A	+	N/A	1/6	+	N/A	+	4/14	+	4/4	-	1/2	N/A	N/A	N/A	+
Nose	+	+	N/A	N/A	N/A	N/A	N/A	N/A	+	4/14	+	4/4	+	2/2	N/A	N/A	N/A	+
Mouth	+	+	+	N/A	N/A	1/6	+	N/A	+	2/14	+	4/4	+	1/2	N/A	+	1/42	+
Fingers, toes	+	+	+	N/A	N/A	4/6	N/A	N/A	+	0/14	N/A	2/4	-	2/2	N/A	+	N/A	+
Congenital anomalies																		
Heart	+	+	+	+	N/A	N/A	N/A	+	+	N/A	+	1/4	-	-	N/A	N/A	11/42	+
CNS	N/A	+	N/A	N/A	N/A	1/6	N/A	N/A	N/A	2/14	N/A	2/4	N/A	1/2	N/A	+	N/A	+
Gastrointestinal	N/A	N/A	N/A	N/A	N/A	N/A	N/A	N/A	+	N/A	N/A	N/A	+	1/2	N/A	N/A	28/41	+
Genitourinary	N/A	N/A	N/A	+	N/A	N/A	N/A	N/A	N/A	1/14	N/A	1/4	N/A	-	N/A	+	Genitourinary: 3/40, Renal: 2/38	-
Musculoskeletal	N/A	+	N/A	N/A	+	2/6	N/A	N/A	N/A	1/14	N/A	3/4	-	1/2	N/A	+	N/A	+
Immunology																		
Immunodeficiency[ǂ]	N/A	N/A	N/A	N/A	N/A	N/A	N/A	N/A	N/A	N/A	N/A	N/A	N/A	N/A	N/A	N/A	N/A	+
Recurrent otitis	N/A	N/A	N/A	N/A	N/A	1/6	N/A	N/A	N/A	1/14	N/A	N/A	-	-	N/A	N/A	13/41	+

+ : present; - : not present; N/A : not available or reported; N : number of cases; [1]1-A is the father of 1-B, [ǂ]low lymphocytes or immunoglobulin; [2] the extent of the deletion beyond the *RPL35A* gene in either direction is unknown.
[Δ]: In the Glassford report, it is not clear if any of these patients were previously reported.

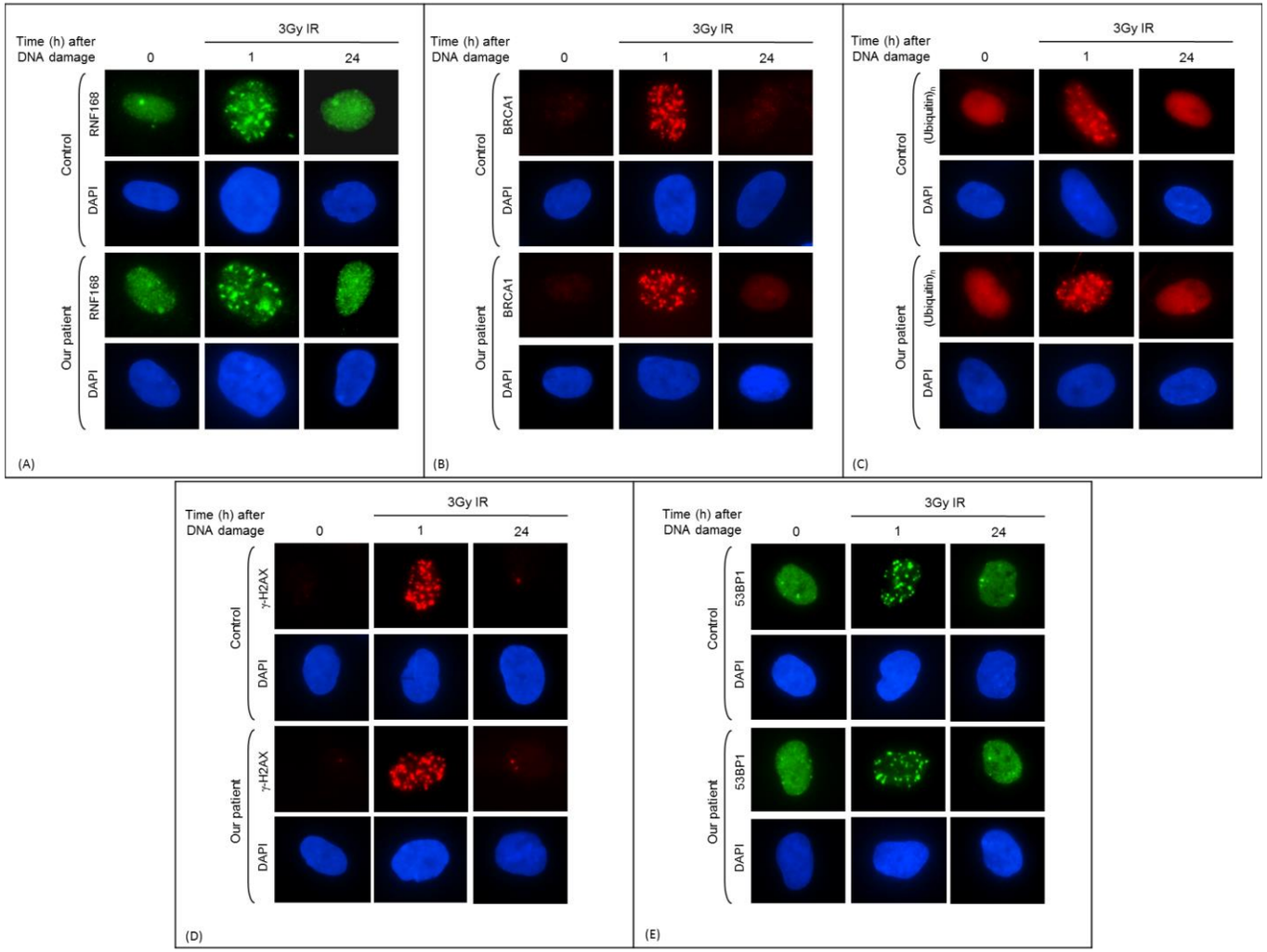
Time (h) after DNA damage
3Gy IR
0
1
24
Control
Our patient
RNF168
BRCA1
(Ubiquitin)n
γ-H2AX
53BP1
DAPI
(A)
(B)
(C)
(D)
(E)

A
B
C
D
E
F