

# Prevalence of adenomyosis in women with subfertility: systematic review and meta-analysis

Mishra, I.; Melo, P.; Easter, C.; Sephton, V.; Dhillon-Smith, R.; Coomarasamy, A.

DOI:

[10.1002/uog.26159](https://doi.org/10.1002/uog.26159)

License:

Creative Commons: Attribution (CC BY)

*Document Version*

Publisher's PDF, also known as Version of record

*Citation for published version (Harvard):*

Mishra, I, Melo, P, Easter, C, Sephton, V, Dhillon-Smith, R & Coomarasamy, A 2023, 'Prevalence of adenomyosis in women with subfertility: systematic review and meta-analysis', *Ultrasound in Obstetrics and Gynecology*, vol. 62, no. 1, pp. 23-41. <https://doi.org/10.1002/uog.26159>

[Link to publication on Research at Birmingham portal](#)

## General rights

Unless a licence is specified above, all rights (including copyright and moral rights) in this document are retained by the authors and/or the copyright holders. The express permission of the copyright holder must be obtained for any use of this material other than for purposes permitted by law.

- Users may freely distribute the URL that is used to identify this publication.
- Users may download and/or print one copy of the publication from the University of Birmingham research portal for the purpose of private study or non-commercial research.
- User may use extracts from the document in line with the concept of 'fair dealing' under the Copyright, Designs and Patents Act 1988 (?)
- Users may not further distribute the material nor use it for the purposes of commercial gain.

Where a licence is displayed above, please note the terms and conditions of the licence govern your use of this document.

When citing, please reference the published version.


## Take down policy

While the University of Birmingham exercises care and attention in making items available there are rare occasions when an item has been uploaded in error or has been deemed to be commercially or otherwise sensitive.

If you believe that this is the case for this document, please contact [UBIRA@lists.bham.ac.uk](mailto:UBIRA@lists.bham.ac.uk) providing details and we will remove access to the work immediately and investigate.



# Prevalence of adenomyosis in women with subfertility: systematic review and meta-analysis

I. MISHRA<sup>1,2</sup> , P. MELO<sup>1,2</sup>, C. EASTER<sup>3</sup>, V. SEPTON<sup>4</sup>, R. DHILLON-SMITH<sup>1</sup> and A. COOMARASAMY<sup>1,2</sup>

<sup>1</sup>Institute of Metabolism and Systems Research, Tommy's National Centre for Miscarriage Research, University of Birmingham, Birmingham, UK; <sup>2</sup>CARE Fertility Birmingham, Birmingham, UK; <sup>3</sup>Institute of Applied Health Research, University of Birmingham, Birmingham, UK; <sup>4</sup>CARE Fertility Chester, Chester, UK

**KEYWORDS:** adenomyosis; endometriosis; fibroid; MRI; MUSA; prevalence; subfertility; transvaginal ultrasound

## CONTRIBUTION

*What are the novel findings of this work?*

This is the first systematic review to evaluate the prevalence of both isolated adenomyosis and adenomyosis with coexisting endometriosis and/or fibroids in women with subfertility. The pooled prevalence was 10% for isolated adenomyosis, 1% for adenomyosis with coexisting fibroids, 6% for adenomyosis with coexisting endometriosis and 7% for adenomyosis with endometriosis and/or fibroids.

*What are the clinical implications of this work?*

One in 10 women with subfertility have a diagnosis of isolated adenomyosis. However, it is potentially underdiagnosed because of a lack of adherence to standardized diagnostic criteria. Clinicians and researchers should use well-established diagnostic criteria, such as those proposed by the morphological uterus sonographic assessment (MUSA) statement, to report on adenomyosis.

## ABSTRACT

**Objective** To determine the prevalence of adenomyosis in women with subfertility.

**Methods** A systematic search was conducted in MEDLINE, EMBASE, CINAHL Plus, Google Scholar, PsycINFO and Web of Science Core Collection from database inception to October 2022. The included studies evaluated the prevalence of adenomyosis in women with subfertility, with or without endometriosis and/or uterine fibroids. Secondary analyses were conducted to identify

variation in the prevalence of isolated adenomyosis according to geographical location, diagnostic modality, diagnostic criteria, type of ultrasound, ultrasound features of adenomyosis and the use of assisted reproductive technology.

**Results** Among 21 longitudinal studies evaluating 25 600 women, the overall pooled prevalence of isolated adenomyosis was 10% (95% CI, 6–15%) ( $I^2 = 99.1%$ ;  $\tau^2 = 0.12$ ). The pooled prevalence was 1% (95% CI, 0–4%) for adenomyosis with concurrent fibroids (eight studies;  $I^2 = 95.8%$ ;  $\tau^2 = 0.03$ ), 6% (95% CI, 3–11%) for adenomyosis with concurrent endometriosis (18 studies;  $I^2 = 98.6%$ ;  $\tau^2 = 0.12$ ) and 7% (95% CI, 2–13%) for adenomyosis with concurrent endometriosis and/or fibroids (nine studies;  $I^2 = 98.3%$ ;  $\tau^2 = 0.09$ ). The prevalence of isolated adenomyosis varied substantially according to geographical location, with Australia exhibiting the highest pooled prevalence of adenomyosis (19% (95% CI, 12–27%)), which was significantly higher compared with that in Asia (5% (95% CI, 1–12%)). The pooled prevalence of isolated adenomyosis diagnosed using a combination of direct and indirect ultrasound features was 11% (95% CI, 7–16%), whereas it was 0.45% (95% CI, 0–1%) in the study in which only an indirect feature was used as the diagnostic criterion.

**Conclusion** One in 10 women with subfertility have a diagnosis of isolated adenomyosis. The prevalence of adenomyosis varies according to the presence of concurrent endometriosis and/or fibroids. © 2023 The Authors. *Ultrasound in Obstetrics & Gynecology* published by John Wiley & Sons Ltd on behalf of International Society of Ultrasound in Obstetrics and Gynecology.

Correspondence to: Dr I. Mishra, Institute of Metabolism and Systems Research, Tommy's National Centre for Miscarriage Research, University of Birmingham, Edgbaston, Birmingham B15 2TT, UK (e-mail: ixm040@student.bham.ac.uk; i.mishra@nhs.net)

Accepted: 23 December 2022

## INTRODUCTION

Adenomyosis is a benign condition characterized by the presence of ectopic endometrial glands and stroma in the myometrium<sup>1</sup>. It has been associated typically with multiparity in women older than 40 years with menorrhagia, in whom a definitive diagnosis was possible only through the histological analysis of hysterectomy specimens<sup>2–4</sup>. Recently, however, there has been a growing body of evidence suggesting that adenomyosis may present earlier in life with abnormal uterine bleeding, subfertility, pelvic pain or even without symptoms and that its diagnosis is possible using non-invasive techniques<sup>2,5,6</sup>. Yet, epidemiological data on the burden of adenomyosis remain scarce, with the reported prevalence varying widely between 5% and 70%<sup>7</sup>.

The negative impact of adenomyosis extends beyond subfertility<sup>2,8–13</sup> and includes impaired implantation<sup>14–17</sup> and trophoblastic function<sup>18</sup>. The evidence regarding the association between adenomyosis and pregnancy loss is conflicting, with some studies suggesting no impact on reproductive function<sup>19–24</sup>. On the other hand, recent meta-analyses have found a negative association between adenomyosis and fertility outcome, especially after short-protocol downregulation in assisted reproductive technology (ART)<sup>25,26</sup>. Quantification of the burden of adenomyosis may facilitate development of therapeutic interventions targeted at women with this condition who are undergoing assisted conception.

Adenomyosis is often diagnosed concurrently with endometriosis and/or fibroids. The prevalence of ultrasound-diagnosed adenomyosis has been reported to be as high as 89.4% in women with endometriosis<sup>27–29</sup>. Similarly, the prevalence of histologically diagnosed adenomyosis with concurrent fibroids (20%) was noted to be higher compared with that of isolated adenomyosis (8%) on specimens of supracervical hysterectomies<sup>7,30</sup>. However, the burden of isolated adenomyosis remains understudied.

In the most recent systematic review on the prevalence of adenomyosis in women with subfertility, conducted a decade ago, the investigators could not draw definitive conclusions because of limited data<sup>9</sup>. Additional studies have since reported on the prevalence of adenomyosis in women with subfertility, yet there has been no recent review evaluating pooled prevalence estimates. The aim of this study was to provide a comprehensive up-to-date synthesis of the data on prevalence of isolated adenomyosis and adenomyosis occurring concurrently with endometriosis and/or fibroids in women with subfertility.

## METHODS

### Protocol registration

The protocol of this systematic review was developed and registered prospectively with PROSPERO (CRD42021255140). The protocol outlined the search strategy, inclusion and exclusion criteria for study selection, quality assessment and strategy for data extraction

and synthesis. We have reported the systematic review in line with the Preferred Reporting Items for Systematic Reviews and Meta-Analyses (PRISMA) 2020 checklist<sup>31</sup>.

### Search strategy

A comprehensive and systematic search of the literature was performed on 4 November 2022 in the following databases: MEDLINE, EMBASE, CINAHL Plus, Google Scholar, PsycINFO and Web of Science Core Collection. We searched for publications in any language from inception until October 2022 using a combination of medical subject headings and the following keywords: ‘prevalence’ OR ‘incidence’ OR ‘epidemiology’ OR ‘frequency’ OR ‘occurrence, adenomyosis’ OR ‘adenomyoma’ OR ‘adenomyosis uteri’ OR ‘endometrial adenoma’ OR ‘endometriosis interna’ OR ‘endometriosis, stroma’ OR ‘internal endometriosis’ OR ‘stroma endometriosis’ OR ‘stromal endometriosis’ OR ‘uterine adenomyomatosis’ OR ‘uterine adenomyosis’ OR ‘uterus adenomyosis, infertile’ OR ‘subfertile’ OR ‘fertile’ (Table S1). The search strategy was reviewed by a medical sciences librarian. A manual search of the reference lists of selected articles was also performed to identify any missing papers with relevant data not identified by the electronic search.

### Study selection and eligibility criteria

Two authors (I.M. and P.M.) screened independently the title and abstract of identified papers. Full-text articles were obtained after screening the abstracts that met the eligibility criteria of the study, and any disagreement was resolved by discussion until a consensus was reached. Cohort and cross-sectional studies examining the prevalence of adenomyosis in women with subfertility were included. Subfertility was defined as failure to establish a clinical pregnancy after 12 months of regular, unprotected sexual intercourse or impairment of a woman’s capacity to reproduce as an individual or with her partner<sup>32</sup>. The term subfertility was used interchangeably with infertility. Subfertile women undergoing and those who were not undergoing ART treatment were included. We included articles without any language restrictions. Studies were included if the authors used any of the previously published and recognized ultrasound and magnetic resonance imaging (MRI) diagnostic features for the diagnosis of adenomyosis<sup>2,33–49</sup>. A participant was considered to have adenomyosis when diagnosed on ultrasound, MRI or a combination of ultrasound and MRI. Diagnosis using ultrasound was made based on any of the direct (myometrial cysts, hyperechogenic islands, echogenic subendometrial lines and buds) and/or indirect (asymmetrical myometrial thickening, globular uterus, fan-shaped shadowing, translesional vascularity, irregular and interrupted junctional zone (JZ)) features of adenomyosis. MRI features included any of the following: maximum (JZmax) or average JZ thickness, JZmax-to-myometrial thickness ratio, high-signal-intensity myometrial spots and low-signal-intensity mass. We excluded studies in

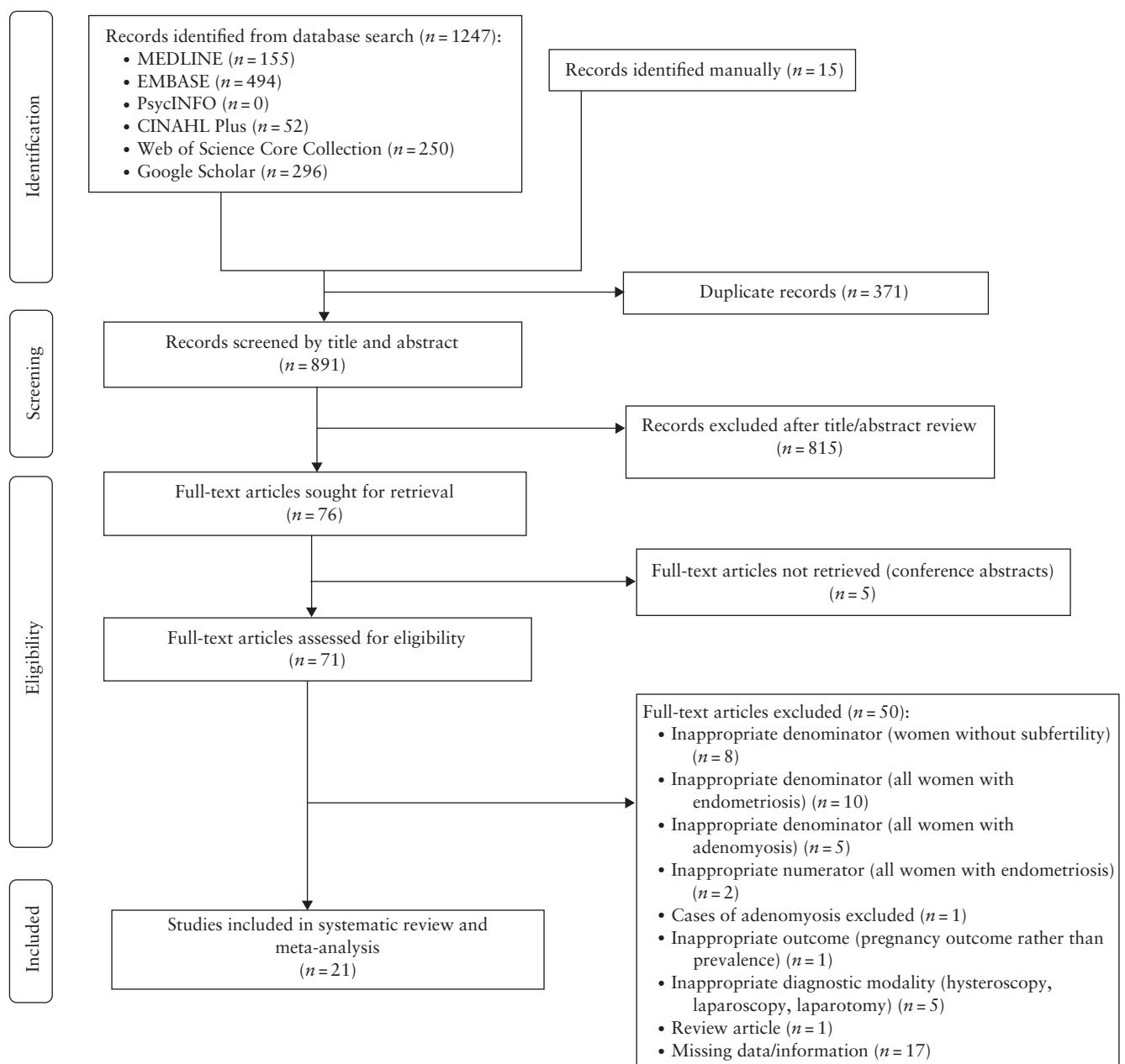
which data were not available separately for women with isolated adenomyosis. Studies in which adenomyosis was diagnosed visually by hysteroscopy, laparoscopy and laparotomy were also excluded due to lack of validation of these tools for diagnosis of adenomyosis. Finally, we also excluded studies in which diagnostic criteria were not mentioned or could not be retrieved after contacting the investigators (Table S2). We planned to report data separately for women with isolated adenomyosis and for those with adenomyosis with concurrent endometriosis and/or fibroids because these pathologies are known to result in a significant variation in the prevalence of adenomyosis<sup>7,30,50</sup>.

The primary outcome was the prevalence of adenomyosis in women with subfertility. This was expressed as a proportion, with the numerator defined as the

number of women with subfertility and adenomyosis with or without endometriosis and/or fibroids, while the denominator represented the total number of women with subfertility in the study group. Subgroup analyses were conducted to identify variation in the prevalence of isolated adenomyosis according to geographical location, diagnostic modality, diagnostic criteria, type of ultrasound, ultrasound features of adenomyosis and the use of ART.

### Data extraction

Two reviewers (I.M. and P.M.) independently extracted study data, including title, first author and year of publication of the paper, country in which the study was conducted, study design, participant characteristics,



**Figure 1** Flowchart summarizing inclusion of studies in systematic review.

Table 1 Characteristics of studies included in systematic review

Study	Country	Study design	Study population characteristics	Mode of diagnosis	Diagnostic criteria used	Imaging operator details	Age (years)	Parity (%)	BMI (kg/m <sup>2</sup> )	Definition of severe adenomyosis
Abu Hashim (2020) <sup>65</sup>	Egypt	Cross-sectional	Subfertility (no ART)	2D US and MRI	US: $\geq 1$ MUSA criterion. MR: Diffuse: JZ $\geq 12$ mm and JZmax/myometrial thickness $> 40\%$ with or without presence of high-signal-intensity myometrial spots. Focal: low-signal-intensity mass with ill-defined margins	Single operator for US. For MRI, one experienced radiologist in gynecological MRI blinded to US findings	$\leq 41$ ; $32.7 \pm 3$	P0, 90.5; P1, 9.5; $> P1, 0$	$31.3 \pm 2.7$	NR
Bourdon (2021) <sup>56</sup>	France	Cross-sectional	Surgery for benign gynecological pathology, including subfertility (no ART)	MRI	Diffuse: JZ $\geq 12$ mm and JZmax/myometrial thickness $> 40\%$ with or without presence of high-signal-intensity myometrial spots. Focal: low-signal-intensity mass with ill-defined margins	Two radiologists with expertise in gynecological imaging, blinded to clinical findings and previous imaging	18–42; mean NR	NR	NR	NR
Costello (2011) <sup>20</sup>	Australia	Retro	Subfertility and ART (fresh IVF/CSI cycle)	2D and 3D US	At least two of following features, with (i) and (ii) being mandatory: (i) subjective enlargement of uterus; (ii) heterogeneous myometrium/hypoechoic striations; (iii) asymmetrically thickened myometrium; (iv) myometrial cysts; (v) irregular/interrupted JZ	More than two operators with expertise in gynecological imaging at one imaging center, with review of images by single reviewer with expertise in gynecological imaging	$\leq 42$ ; $36.75 \pm 3.75$	NR	$24.58 \pm 4.18$	NR
de Souza (1995) <sup>8</sup>	UK	Prosp	Subfertility (no ART); dysmenorrhea and menorrhagia	MRI	Diffuse: increased JZ thickness (8–12 mm), with increased JZ-to-outer-myometrial ratio with or without high-signal foci. Focal: localized ill-defined mixed-signal-intensity mass within myometrium	Two radiologists blinded to previous US findings	26–41; $34.36 \pm 0.71$	P0, 64.3; $\geq P1, 35.7$	NR	NR
Higgins (2021) <sup>24</sup>	Australia	Prosp	Subfertility and ART (first fresh IVF cycle)	2D and 3D US	$\geq 1$ MUSA criterion	More than two operators with expertise in gynecological US trained to diagnose adenomyosis using MUSA criteria. Images reviewed by three certified specialists in gynecological US	18–45; $37.4 \pm 0.3$	P0, 93.0; $\geq P1, 7.0$	$26.2 \pm 0.3$	$\geq 3$ positive markers of adenomyosis on US
Hou (2020) <sup>14</sup>	China	Retro	Subfertility and ART (first fresh IVF cycle) with normal ovarian reserve (serum basal FSH $< 10$ mIU/mL and AFC $\geq 10$ )	2D US, clinical symptoms and signs	More than two of following on two separate occasions detected independently by two investigators: no distinction of endometrial–myometrial junction; asymmetry of anterior and posterior myometrium; subendometrial myometrial striations; myometrial cysts and fibrosis and heterogeneous myometrial echotexture. Symptoms: progressive and secondary dysmenorrhea and menorrhagia. Signs: enlargement of uterus, increased firmness and tenderness	Two operators with expertise in gynecological imaging independently on two separate occasions	$< 38$ ; $31.8 \pm 1$	NR	$22.6 \pm 0.63$	NR
Kunz (2005) <sup>50</sup>	Germany	Prosp	Subfertility (no ART)	MRI	Average JZ $> 10$ mm	Two independent investigators blinded to clinical data	17–46; mean NR	NR	NR	NR

Continued over.

Table 1 Continued

Study	Country	Study design	Study population characteristics	Mode of diagnosis	Diagnostic criteria used	Imaging operator details	Age (years)	Parity (%)	BMI (kg/m <sup>2</sup> )	Definition of severe adenomyosis
Martinez-Conejero (2011) <sup>61</sup>	Spain	Retro	Subfertility and ART (fresh or frozen oocyte recipient IVF cycle)	2D US	Hypoechoic and heterogeneous areas with decreased echogenicity associated with elliptic intramyometrial lakes > 2 mm in diameter in globular-appearing uterus	NR	29–49; 40.5 ± 3.33	NR	NR	NR
Maubon (2010) <sup>15</sup>	France	Prosp	Subfertility and ART (fresh or frozen IVF cycle)	MRI	Average JZ > 7 mm and JZmax > 10 mm. Average JZ extracted from mean of three measurements in midsagittal section of uterus in anterior, posterior and fundal walls. JZmax defined as largest value of these three measurements and recorded in cases of irregular JZ	One experienced radiologist with expertise in gynecological MRI, other than that patients were undergoing IVF	21–43; mean NR	NR	NR	NR
Naftalin (2012) <sup>27</sup>	UK	Prosp	Women attending general gynecology clinic with subfertility (no ART)	2D and 3D US	Any one of following: asymmetrical myometrial thickening not caused by presence of fibroids; parallel shadowing; linear striations; myometrial cysts; hypercholeogenic islands; adenomyoma; irregular endometrial–myometrial junction	Single operator with expertise in gynecological imaging and in-depth training to diagnose adenomyosis on US	NR	NR	NR	NR
Neal (2020) <sup>22</sup>	USA	Prosp	Subfertility and ART (frozen ICSI cycle: transfer of single euploid blastocyst)	2D and 3D US	≥ 1 MUSA criterion noted by three of five reviewers	US performed by more than two operators and images reviewed independently by five reproductive endocrinology specialists with expertise in gynecological US	37.1 ± 5.2	≥ P1, 46.5	25.0 ± 5.0	According to number of positive sonographic markers and number of reviewers assigning diagnosis of adenomyosis, with most severe cases having two or more sonographic features of adenomyosis
Orlov (2022) <sup>59</sup>	Sweden	Cross-sectional	Women with symptoms of endometriosis, including those with subfertility (no ART)	2D US	≥ 1 MUSA criterion	Single operator with expertise in gynecological US, including diagnosis of deep endometriosis	24–51; 35.2 ± 5.6	NR	NR	NR
Puente (2016) <sup>64</sup>	Spain	Cross-sectional	Subfertility and ART (fresh or frozen IVF/ICSI cycle), including those with recurrent miscarriage (≥ 2) and/or repeat implantation failure (≥ 3 IVF failures)	2D and 3D US	One or more of following: globular uterus; asymmetrically thickened myometrial wall; heterogeneous myometrium with fan-shaped shadowing, irregular/interrupted JZ; intramyometrial cysts; subendometrial lines	Single operator with expertise in gynecological US	38.3 ± 4.1	P0, 94	20.9 ± 4.5	According to effect of adenomyosis on uterine cavity shape. Endometrial cavity classified as having normal (triangular) shape, moderate distortion of triangular aspect or severe distortion (pseudo-T-shaped)
Rees (2022) <sup>66</sup>	The Netherlands	Retro	Subfertility and ART (first fresh embryo transfer during IVF/ICSI cycle)	MRI	Focal or diffuse JZ thickening > 12 mm, JZ/myometrium ratio > 40% and/or presence of high-signal-intensity myometrial foci on T1/T2	Re-evaluation of MRI by study investigator and three pelvic radiologists	18–42; 33.75 ± 3.61	P0, 50; ≥ P1, 41.7	23.59 ± 3.88	NR

Continued over.

Table 1 Continued

Study	Country	Study design	Study population characteristics	Mode of diagnosis	Diagnostic criteria used	Imaging operator details	Age (years)	Parity (%)	BMI (kg/m <sup>2</sup> )	Definition of severe adenomyosis
Salim (2012) <sup>16</sup>	UK	Prosp	Subfertility and ART (first fresh IVF/ICSI cycle) with adequate ovarian reserve (serum basal FSH < 10 IU/L, estradiol < 200 pmol/L and AFC > 8)	2D US	Presence of all following features: asymmetrical thickening of myometrium, irregular cystic areas within myometrium and linear striations radiating out from myometrium	Two operators with expertise in gynecological US	34.0 ± 3.67	NR	24.5 ± 2.7	NR
Sharma (2019) <sup>68</sup>	India	Retro	Subfertility and ART (first fresh IVF cycle)	2D US	Three of following features: globular uterus; asymmetrical thickened myometrial wall; poorly defined endomyometrial interface; presence of heterogeneous myometrial area and myometrial cysts	Single operator with expertise in gynecological US	≤ 40; 32.89 ± 2.98	NR	24.9 ± 3.42	All five diagnostic US criteria
Silva (2020) <sup>63</sup>	Portugal	Prosp	Subfertility (no ART)	2D and 3D US	≥ 1 MUSA criterion	Single operator, with postprocessing and analysis of 3D volume performed independently by two blinded operators followed by reanalysis of 3D volumes in 4 months	23–40; mean NR	NR	NR	NR
Stanekova (2018) <sup>18</sup>	Australia	Retro	Subfertility and ART (first frozen ICSI cycle: euploid embryo with good morphology), excluding women using donor oocyte and surrogacy	2D and 3D US, MRI in case of uncertainty	US: area of ≥ 2 cm of adenomyosis with following features: enlarged globular uterus; heterogeneous myometrium; subendometrial myometrial striations and cysts; asymmetrical thickening of uterine walls; poorly defined JZ. MRI: JZ ≥ 12 mm and subendometrial cyst	NR	37.0 ± 4.0	P0, 75.8; P1, 21.2; ≥ P2, 6.0	27.6 ± 5.6	NR
Thalluri (2012) <sup>62</sup>	Australia	Retro	Subfertility and ART (first fresh or frozen IVF cycle)	2D US	Globular uterus; asymmetrical thickened myometrial wall; heterogeneous myometrium; myometrial cysts; increased echotexture of endometrium; and subendometrial linear striations	Performed by more than two operators and reported by radiologists with expertise in gynecological US	≤ 39; 35 ± 1.5	NR	24.8 ± 2.33	NR
Yan (2014) <sup>23</sup>	China	Retro	Subfertility and ART (fresh IVF/ICSI cycle)	2D US	Heterogeneous areas in myometrium with poorly defined borders. Diagnosis further corroborated by presence of clinical symptoms, such as dysmenorrhea and irregular uterine bleeding or surgical pathology report	Two experienced and skilled clinicians	≤ 42; 34.3 ± 4.1	≥ P1, 54.5	23.3 ± 3.5	NR
Zhang (2021) <sup>67</sup>	China	Retro	Tubal factor subfertility and ART (first frozen IVF/ICSI cycle)	2D and 3D US	≥ 3 MUSA criteria	NR	≤ 40; 34.6 ± 4.5	NR	23.8 ± 3.2	NR

Data are given as range or mean ± SD, unless stated otherwise. Only first author is given for each study. 2D, two-dimensional; 3D, three-dimensional; AFC, antral follicle count; ART, assisted reproductive technology; BMI, body mass index; FSH, follicle-stimulating hormone; IVF, *in-vitro* fertilization; ICSI, intracytoplasmic sperm injection; JZ, junctional zone; JZmax, maximum JZ thickness; MRI, magnetic resonance imaging; MUSA, morphological uterus sonographic assessment; NR, not recorded; P, parity; Prosp, prospective; Retro, retrospective; T1, T1-weighted MRI; T2, T2-weighted MRI; US, ultrasound.

Table 2 Prevalence of adenomyosis and disease characteristics in studies included in systematic review

Study	Women with subfertility	Adenomyosis with endometriosis and/or fibroids	Adenomyosis with fibroids	Adenomyosis with endometriosis	Isolated adenomyosis	Symptoms of adenomyosis	Type of adenomyosis	Severe adenomyosis
Abu Hashim (2020) <sup>65</sup>	320	9/320 (3)	5/320 (2)	4/320 (1)	12/320 (4)	14/21 (67)	Diffuse, 18/21 (86); focal, 3/21 (14)	NR
Bourdon (2021) <sup>56</sup>	135	47/135 (35)	NR	NR	6/135 (4)	NR	Diffuse, 16/53 (30); focal, 37/53 (70); focal + diffuse, 22/53 (42)	NR
Costello (2011) <sup>20</sup>	201	8/201 (4)	3/201 (1)	5/201 (2)	29/201 (14)	NR	NR	NR
de Souza (1995) <sup>8</sup>	26	9/26 (35)	1/26 (4)	7/26 (27)	5/26 (19)	Isolated, 5/5 (100)	Isolated: diffuse, 5/5 (100)	NR
Higgins (2021) <sup>24</sup>	944	38/944 (4)	3/944 (0.3)	35/944 (4)	263/944 (28)	NR	NR	132/301 (44)
Hou (2020) <sup>14</sup>	3960	NR (fibroids and endometriosis excluded)	NR (fibroids excluded)	NR (endometriosis excluded)	489/3960 (12)	489/489 (100) (presence of symptoms was one of diagnostic features)	NR	NR
Kunz (2005) <sup>50</sup>	227	NR (fibroids excluded)	NR (fibroids excluded)	126/227 (56)	19/227 (8)	NR	Isolated: focal, 7/19 (37); diffuse, 12/19 (63)	NR
Martínez-Conejero (2011) <sup>61</sup>	443	NR (fibroids excluded)	NR (fibroids excluded)	23/443 (5)	129/443 (29)	NR	NR	NR
Maubon (2010) <sup>15</sup>	152	NR (fibroids excluded)	NR (fibroids excluded)	8/152 (5)	16/152 (11)	NR	NR	NR
Naftalin (2012) <sup>27</sup>	158	14/158 (9)	8/158 (5)	5/158 (3)	11/158 (7)	NR	NR	NR
Neal (2020) <sup>22</sup>	648	NR (fibroids excluded)	NR (fibroids excluded)	4/648 (1)	95/648 (15)	NR	NR	17/99 (17) for sonographic features (two or more); 9/99 (9) for number of reviewers assigning diagnosis of adenomyosis (five or more)
Orlov (2022) <sup>59</sup>	64	NR	NR	10/64 (16)	4/64 (6)	14/14 (100)	NR	NR
Puente (2016) <sup>64</sup>	1015	82/1015 (8)	48/1015 (5)	34/1015 (3)	166/1015 (16)	NR	NR	25/248 (10)
Rees (2022) <sup>66</sup>	255	NR (fibroids excluded)	NR (fibroids excluded)	93/255 (36)	36/255 (14)	Isolated, 8/36 (22)	Focal, 58/129 (45); diffuse, 31/129 (24); cystic, 5/129 (4); focal + cystic, 17/129 (13); diffuse + cystic, 10/129 (8); unclear, 8/129 (6)	NR
Salim (2012) <sup>16</sup>	275	NR (fibroids excluded)	NR (fibroids excluded)	1/275 (0.4)	18/275 (7)	6/19 (32)	NR	NR
Sharma (2019) <sup>68</sup>	973	NR (fibroids excluded)	NR (fibroids excluded)	88/973 (9)	64/973 (7)	NR	Diffuse, 152/152 (focal cases excluded)	Isolated, 29/64 (45); with concurrent endometriosis, 30/88 (34)
Silva (2020) <sup>63</sup>	65	0/65 (0)	0/65 (0)	0/65 (0)	0/65 (0)	NR	NR	NR
Stanekova (2018) <sup>18</sup>	171	NR (fibroids excluded)	NR (fibroids excluded)	8/171 (5)	26/171 (15)	NR	NR	NR
Thalluri (2012) <sup>62</sup>	213	NR (fibroids excluded)	NR (fibroids excluded)	1/213 (0.5)	37/213 (17)	NR	NR	NR
Yan (2014) <sup>23</sup>	10 268	37/10 268 (0.4)	11/10 268 (0.1)	26/10 268 (0.3)	46/10 268 (0.4)	NR	NR	NR
Zhang (2021) <sup>67</sup>	5087	NR (endometriosis and fibroids excluded)	NR (fibroids excluded)	NR (endometriosis excluded)	193/5087 (4)	NR	NR	NR

Data are given as n or n/N (%). Only first author is given for each study. NR, not recorded.



numerator (women with a diagnosis of adenomyosis with or without coexisting endometriosis and/or fibroids), denominator (women with subfertility), mode of diagnosis, diagnostic criteria, imaging operator details, age, body mass index, parity, presence/absence of symptoms of adenomyosis and type and severity of adenomyosis. We attempted to contact the authors to retrieve missing data if applicable.

### Quality assessment

Two review authors (I.M. and P.M.) assessed the methodological quality of the included studies using the Critical Appraisal Skills Program (CASP) 2018 checklist for cohort studies<sup>51</sup>. This checklist comprises three main domains: validity of study results, study results and application of results locally. The potential for publication bias was not assessed using a funnel plot because the assumption that positive results are more often published is not necessarily true for proportional studies, as there is no clear definition or consensus on what constitutes a positive result in a meta-analysis of proportions<sup>52</sup>.

### Statistical analysis

Data analysis was performed using Stata statistical software, release 17 (StataCorp. LLC, College Station, TX, USA). The prevalence of adenomyosis was reported as a proportion with 95% CI. The Stata Metaprop statistical command and double arcsine transformation

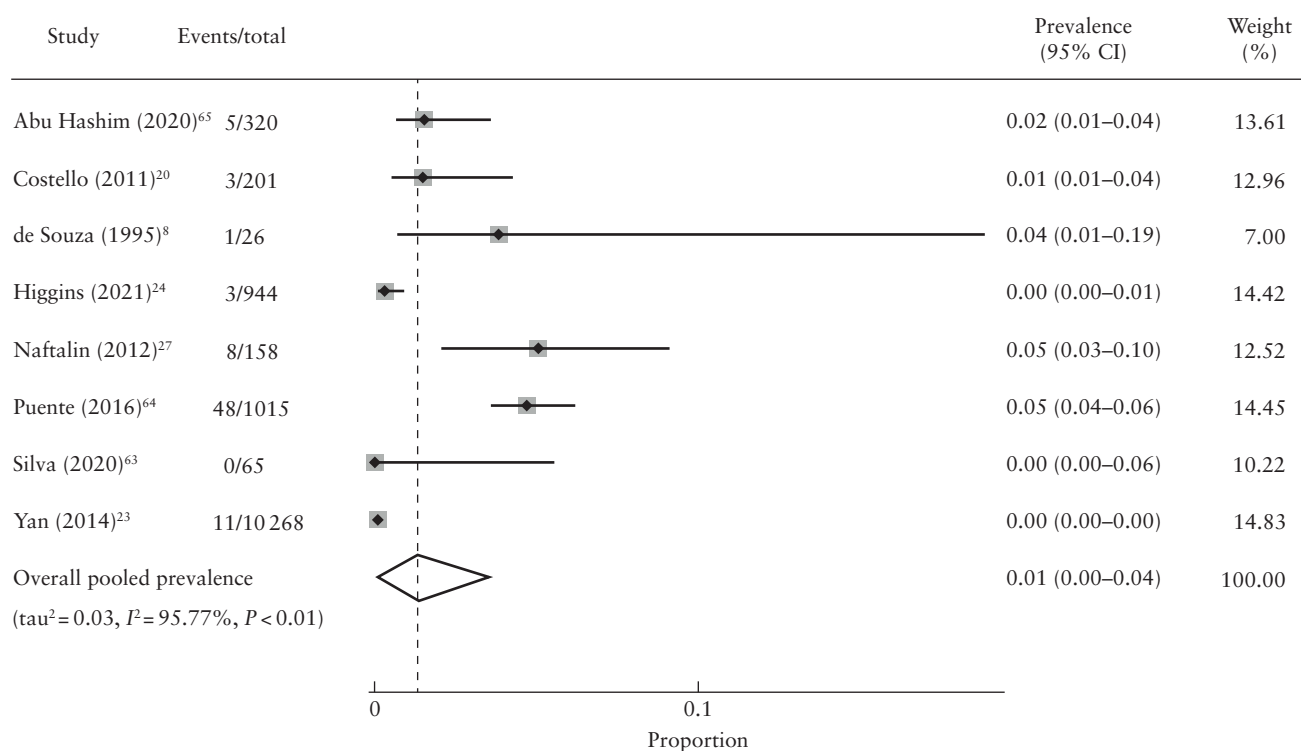
(Freeman–Tukey transformation) were used to pool proportions from individual studies, allowing inclusion of studies with proportions of zero or one<sup>53</sup>. Heterogeneity was assessed graphically, using forest plots, and statistically, using the  $\tau^2$  and  $I^2$  statistics. Effect estimates were pooled using a random-effects model to allow for differences in prevalence estimates between different studies. The  $\tau^2$  statistic represented the extent of variation in the prevalence observed in different studies (between-study variance)<sup>54</sup>.  $I^2 > 50\%$  was considered indicative of substantial heterogeneity<sup>54</sup>.

The primary analysis included studies reporting on the prevalence of adenomyosis in women with subfertility. Secondary analyses were also conducted to identify variation in the prevalence of isolated adenomyosis according to geographical location, mode of diagnosis, diagnostic criteria, type of ultrasound, ultrasound features of adenomyosis and the use of ART. To determine the possible impact of these factors on the observed heterogeneity across studies, we conducted metaregression analysis within the above subgroups.

## RESULTS

### Study selection

The PRISMA flowchart outlines the study selection process in detail (Figure 1). Our electronic search retrieved 1247 records. The manual reference list search of selected articles identified 15 additional studies that appeared to



**Figure 2** Forest plot showing prevalence of adenomyosis with concurrent fibroids in women with subfertility. Only first author is given for each study. Random-effects model and Freeman–Tukey formula were used.

meet the inclusion criteria. The title and abstract of 891 articles were screened after exclusion of 371 duplicates. Following title and abstract screening, 76 records potentially meeting the eligibility criteria were included. We obtained the full text of 71 records, of which 33 studies were excluded because they did not meet the inclusion criteria. Of these, 23 studies had an inappropriate denominator (eight studies that assessed women without subfertility, 10 studies in which all women had endometriosis and five studies in which all women had adenomyosis), two studies had an inappropriate numerator (all women had endometriosis), one study did not report on the prevalence of adenomyosis and focused on pregnancy outcome instead, one study was a review article, one study excluded cases of adenomyosis and five studies used an inappropriate diagnostic modality (Table S2). Additionally, 17 studies with missing information/data were excluded due to unanswered correspondence by the authors or lack of contact details (Table S3). When possible, we attempted to contact the authors of 26 studies to obtain relevant study details and missing data (Table S3). At the time of writing, we received responses for nine studies<sup>23,27,28,55-60</sup>, of which four were included<sup>23,27,56,59</sup> and five excluded<sup>28,55,57,58,60</sup>. A total of 21 studies were included in the final qualitative and quantitative syntheses<sup>8,14-16,18,20,22-24,27,50,56,59,61-68</sup>.

Study characteristics

All of the 21 included studies reported on the prevalence of isolated adenomyosis among a total of 25 600 participants. Of these, 18 studies also reported on the prevalence of adenomyosis occurring concurrently with endometriosis<sup>8,15,16,18,20,22-24,27,50,59,61-66,68</sup>, eight reported on the prevalence of adenomyosis occurring concurrently with fibroids<sup>8,20,23,24,27,63-65</sup> and nine reported on the prevalence of concomitant adenomyosis, fibroids and/or endometriosis<sup>8,20,23,24,27,56,63-65</sup>. Tables 1 and 2 describe the characteristics of the included studies and present the prevalence of adenomyosis, respectively. The quantitative analyses included four cross-sectional studies<sup>56,59,64,65</sup>, eight prospective cohort studies<sup>8,15,16,22,24,27,50,63</sup> and nine retrospective cohort studies<sup>14,18,20,23,61,62,66-68</sup>. The included studies were conducted in 12 different countries. Fourteen studies used ultrasound to diagnose adenomyosis<sup>14,16,20,22-24,27,59,61-64,67,68</sup>, whereas five studies used MRI<sup>8,15,50,56,66</sup>. Two studies used a combination of ultrasound and MRI, with MRI used to confirm the ultrasound diagnosis of adenomyosis<sup>65</sup> or to confirm or refute the diagnosis in cases of uncertainty<sup>18</sup>. Six studies included data on the type of adenomyosis<sup>8,50,56,65,66,68</sup> and, in five of them<sup>8,50,56,65,66</sup>, MRI was used as a diagnostic tool, whereas ultrasound was used in one study<sup>68</sup>. Four studies reported on the severity of adenomyosis based on

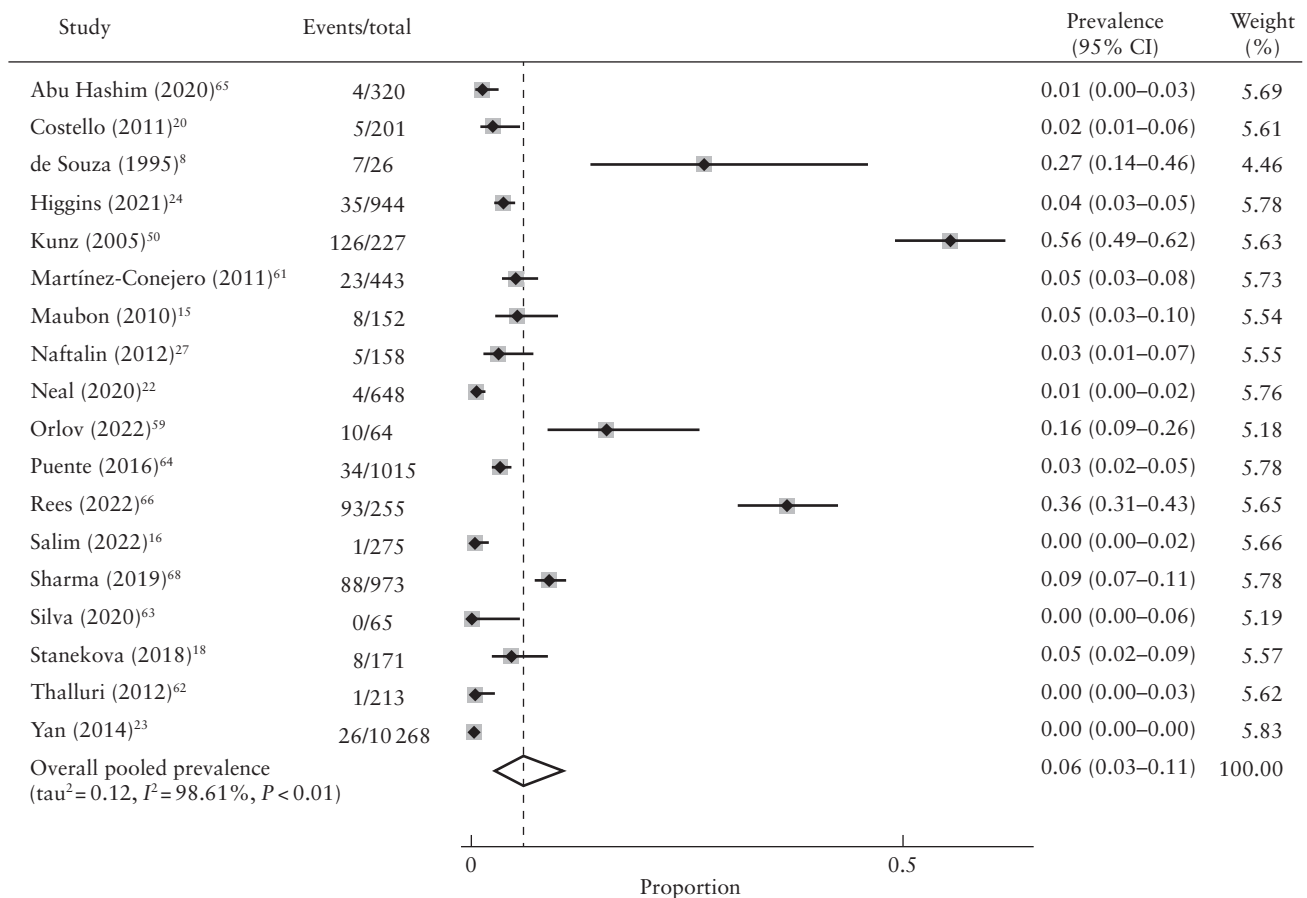


Figure 3 Forest plot showing prevalence of adenomyosis with concurrent endometriosis in women with subfertility. Only first author is given for each study. Random-effects model and Freeman-Tukey formula were used.

ultrasound<sup>22,24,64,68</sup>. Severity was defined differently in all four studies and was based on the number of diagnostic features identified<sup>22,24,68</sup>, the number of reviewers making the diagnosis of adenomyosis<sup>22</sup> and the effect of adenomyosis on the shape of the uterine cavity<sup>64</sup>. The number of features required for adenomyosis to be classified as severe varied as follows: two features<sup>22</sup>, three features<sup>24</sup> and all features<sup>68</sup>.

### Participant characteristics

The age of participants ranged from 17 years to 51 years. In 14 studies, women were assessed for adenomyosis before undergoing ART<sup>14–16,18,20,22–24,61,62,64,66–68</sup>. Women underwent fresh ART cycles in seven studies<sup>14,16,20,23,24,66,68</sup>, frozen cycles in three studies<sup>18,22,67</sup> and frozen or fresh cycles in four studies<sup>15,61,62,64</sup>. In seven studies, women with subfertility who were not undergoing ART cycles were assessed for adenomyosis<sup>8,27,50,56,59,63,65</sup>.

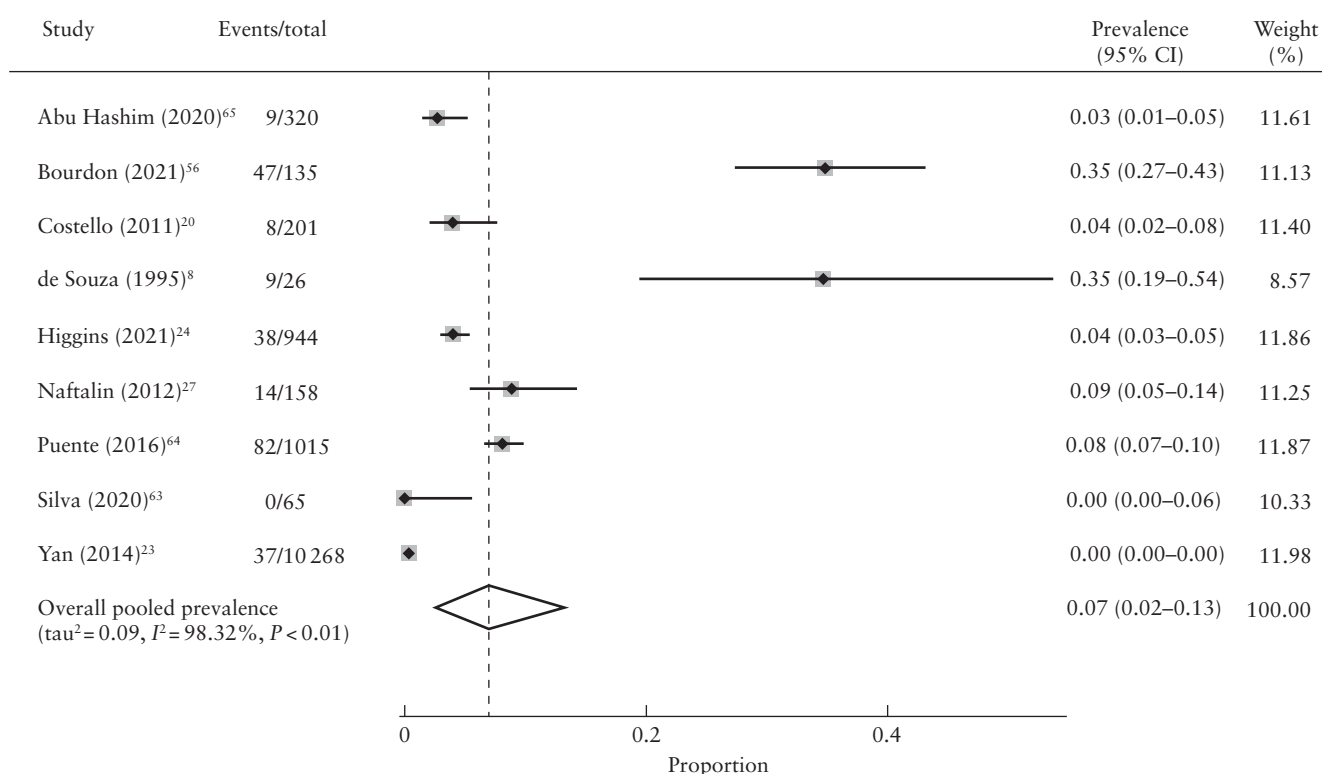
### Overall prevalence of adenomyosis with coexisting fibroids

Prevalence estimates across eight studies ranged from 0% in women aged 23–40 years with subfertility in a prospective study by Silva *et al.*<sup>63</sup> to 5% in two studies, including a cross-sectional study of women with a mean age of 38 years undergoing ART treatment in Spain<sup>64</sup> and a prospective study of women attending a

general gynecology clinic with subfertility in the UK<sup>27</sup>. The study of Silva *et al.*<sup>63</sup> applied MUSA criteria<sup>48</sup> to diagnose adenomyosis using ultrasound, whereas the study of Naftalin *et al.*<sup>27</sup> and Puente *et al.*<sup>64</sup> used the presence of at least one or more direct (myometrial cysts, hyperechogenic islands, echogenic subendometrial lines and buds) and/or indirect (asymmetrical myometrial thickening, globular uterus, fan-shaped shadowing, irregular and interrupted JZ) ultrasound features to diagnose adenomyosis. The overall random-effects pooled prevalence of adenomyosis with fibroids in women with subfertility was 1% (95% CI, 0–4%) with a high level of heterogeneity ( $I^2 = 95.8%$ ,  $\tau^2 = 0.03$ ) (Figure 2).

### Overall prevalence of adenomyosis with coexisting endometriosis

Prevalence estimates across 18 studies ranged from 0% in women aged 23–40 years with subfertility in the study by Silva *et al.*<sup>63</sup> to 56% in women aged 17–46 years with subfertility in Germany<sup>50</sup>. Both studies were prospective; one study<sup>63</sup> applied sonographic MUSA criteria, while the other<sup>50</sup> used average JZ thickness of more than 10 mm on MRI<sup>50</sup> to diagnose adenomyosis. The overall random-effects pooled prevalence of adenomyosis with coexisting endometriosis in women with subfertility was 6% (95% CI, 3–11%) with a high level of heterogeneity ( $I^2 = 98.6%$ ,  $\tau^2 = 0.12$ ) (Figure 3).



**Figure 4** Forest plot showing prevalence of adenomyosis with concurrent endometriosis and/or fibroids in women with subfertility. Only first author is given for each study. Random-effects model and Freeman–Tukey formula were used.

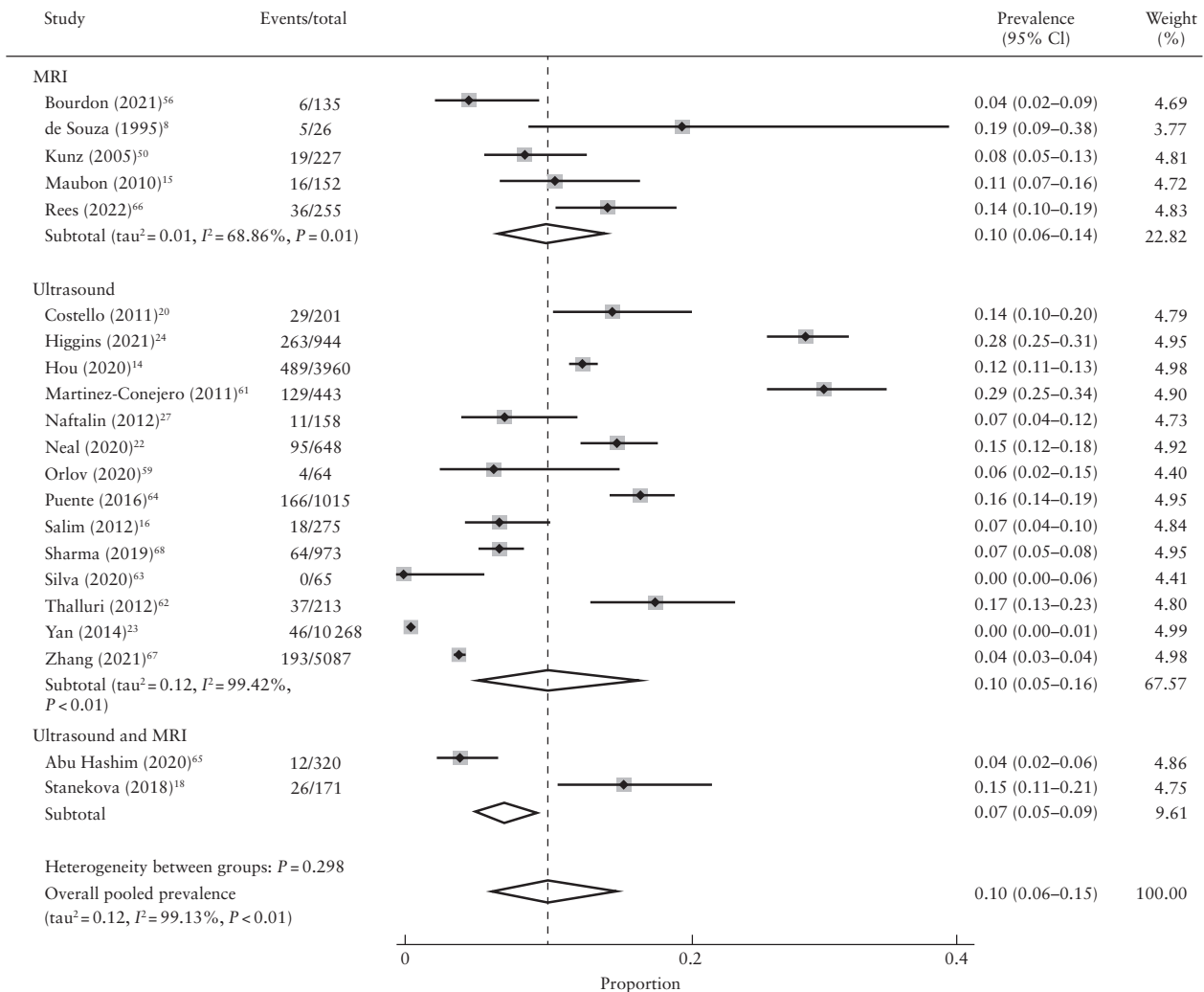
**Overall prevalence of adenomyosis with coexisting endometriosis and/or fibroids**

Prevalence estimates across nine studies ranged from 0% in a prospective cohort of women aged 23–40 years with subfertility in Portugal<sup>63</sup> to 35% in a prospective study of women aged 26–41 years presenting with dysmenorrhea, menorrhagia and subfertility in the UK<sup>8</sup> and in a cross-sectional study of women aged 18–42 years with subfertility and undergoing surgery for benign gynecological disease in France<sup>56</sup>. The study in Portugal<sup>63</sup> used well-defined MUSA criteria, whereas the other two studies<sup>8,56</sup> used MRI to diagnose adenomyosis. The MRI diagnostic criteria in terms of the cut-off for JZ thickness varied between the two studies. De Souza *et al.*<sup>8</sup> used increased thickness of the JZ (8–12 mm) and increased JZ-to-outer-myometrial ratio with or without high-signal foci to diagnose diffuse adenomyosis, and the presence of a localized ill-defined mixed-signal-intensity mass to diagnose focal adenomyosis. In contrast, Bourdon *et al.*<sup>56</sup> used the presence of increased thickness of the JZ  $\geq 12$  mm

and JZmax/myometrial thickness  $> 40\%$  with or without presence of high-signal-intensity myometrial spots to diagnose diffuse adenomyosis, and the presence of a low-signal-intensity mass with ill-defined margins to diagnose focal adenomyosis. The overall random-effects pooled prevalence of adenomyosis with coexisting endometriosis and/or fibroids in women with subfertility was 7% (95% CI, 2–13%) with a high level of interstudy heterogeneity ( $I^2 = 98.3\%$ ;  $\tau^2 = 0.09$ ) (Figure 4).

**Overall prevalence of isolated adenomyosis**

The prevalence of isolated adenomyosis across 21 included studies ranged from 0% in women aged 23–40 years with subfertility in the study of Silva *et al.*<sup>63</sup> to 29% in women aged 29–49 years undergoing oocyte recipient IVF cycles in Spain<sup>61</sup>. The study of Silva *et al.*<sup>63</sup> was prospective and used MUSA criteria to diagnose adenomyosis, whereas the study of Martínez-Conejero *et al.*<sup>61</sup> was retrospective and used ultrasound features of a



**Figure 5** Forest plot showing prevalence of isolated adenomyosis in women with subfertility according to diagnostic modality. Only first author is given for each study. Random-effects model and Freeman–Tukey formula were used.  $I^2$  and  $\tau^2$  were not generated for subgroups including fewer than four studies. MRI, magnetic resonance imaging.

hypoechoic and heterogeneous myometrium associated with elliptic intramyometrial lakes of more than 2 mm in diameter in a globular-appearing uterus to diagnose adenomyosis. The mean age of women with a diagnosis of adenomyosis ranged from 32 years<sup>14</sup> to 41 years<sup>61</sup>. The overall random-effects pooled prevalence of isolated adenomyosis was 10% (95% CI, 6–15%) with a high level of heterogeneity ( $I^2 = 99.1\%$ ;  $\tau^2 = 0.12$ ). We performed subgroup analyses according to geographical area, diagnostic modality, diagnostic criteria, type of ultrasound, ultrasound features of adenomyosis and population of women with subfertility for the isolated adenomyosis group (Figures 5–10).

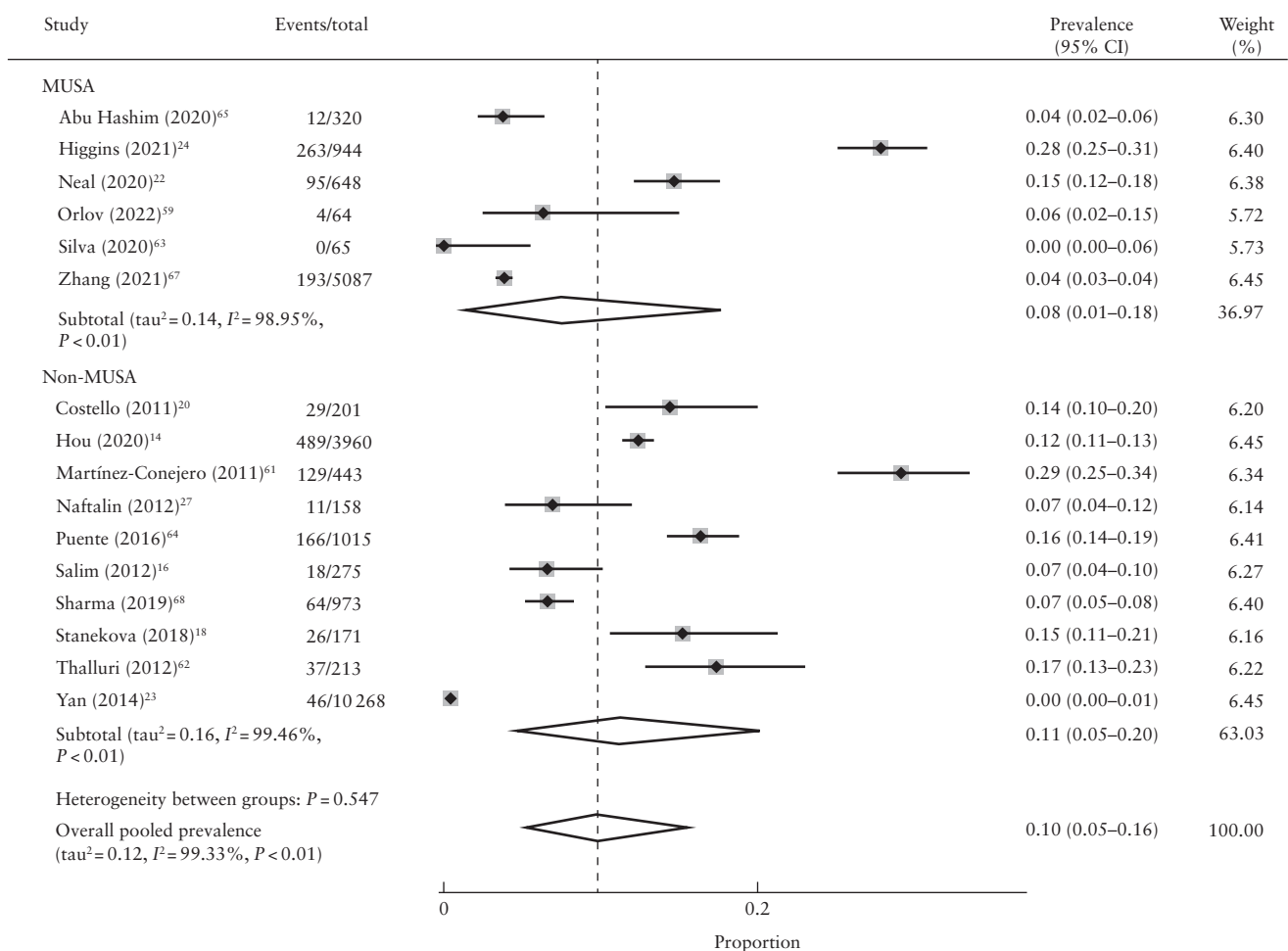
### Prevalence of isolated adenomyosis according to diagnostic modality

The prevalence of adenomyosis according to diagnostic method ranged from 0% to 29% in studies using ultrasound, 4% to 19% in studies using MRI and 4% to 15% in studies using a combination of ultrasound and MRI. The pooled prevalence of isolated adenomyosis was 10% (95% CI, 5–16%) using ultrasound, 10% (95% CI, 6–14%) using MRI and 7% (95% CI, 5–9%) using

a combination of ultrasound and MRI as a diagnostic tool (Figure 5). We performed a meta-regression analysis including pooled prevalence estimates for subgroups based on the mode of diagnosis. This suggested that the mode of diagnosis had little effect on the prevalence of adenomyosis ( $P$ -value ranging from 0.74 to 0.86) when comparing ultrasound with other diagnostic modalities (Table 3).

### Ultrasound as diagnostic modality

The ultrasound diagnostic criteria, type of ultrasound and direct/indirect features used to diagnose adenomyosis varied between studies. Six studies used the well-defined and standardized MUSA criteria for diagnosis of adenomyosis<sup>22,24,59,63,65,67</sup>, whereas 10 studies used variable direct and indirect signs of adenomyosis for its diagnosis on ultrasound<sup>14,16,18,20,23,27,61,62,64,68</sup>. The MUSA criteria are a consensus-based set of parameters, outlining terms and definitions to describe and report the sonographic features of adenomyosis, facilitating consistency in reporting<sup>48</sup>. Two-dimensional (2D) and three-dimensional (3D) ultrasound features in the form of direct and indirect signs used to diagnose adenomyosis



**Figure 6** Forest plot showing prevalence of isolated adenomyosis in women with subfertility according to ultrasound diagnostic criteria. Only first author is given for each study. Random-effects model and Freeman–Tukey formula were used. MUSA, morphological uterus sonographic assessment.

according to MUSA include globular uterus, asymmetrical myometrial wall thickening, myometrial cyst(s), hyperechogenic islands, fan-shaped shadowing, echogenic subendometrial lines and buds, translesional vascularity, irregular JZ and interrupted JZ<sup>48,49</sup>. The way in which MUSA criteria were applied also varied between studies, as outlined in Table 1. The pooled prevalence of isolated adenomyosis was 8% (95% CI, 1–18%) in studies using MUSA criteria and 11% (95% CI, 5–20%) in those using non-MUSA diagnostic criteria (Figure 6).

Ultrasound assessment was performed by clinicians and sonographers with expertise in gynecological imaging in 13 of 16 ultrasound-based studies<sup>14,16,20,22–24,27,59,62–65,68</sup>. Operator information was not mentioned in three studies<sup>18,61,67</sup>. The prevalence varied with the number of operators performing the ultrasound assessment. It ranged from 0% to 16% across six studies in which ultrasound assessment was performed by a single operator to minimize the interobserver variability<sup>27,59,63–65,68</sup>, from 0.45% to 12% across three studies in which assessment was performed by two operators<sup>14,16,23</sup>, and from 14% to 28% across studies in which assessment was performed by more than two operators<sup>20,22,24,62</sup>. In these studies, the images were rereviewed by one expert<sup>20</sup>, three experts<sup>24</sup> or five experts<sup>22</sup>. In one study<sup>14</sup>, in which

ultrasound was performed on two separate occasions to diagnose adenomyosis, the prevalence of adenomyosis was 12%.

Eight studies used a combination of 2D and 3D ultrasound for diagnosis of adenomyosis<sup>18,20,22,24,27,63,64,67</sup>, while the remaining eight studies used 2D ultrasound for the diagnosis<sup>14,16,23,59,61,62,65,68</sup>. The pooled prevalence of isolated adenomyosis was 9% (95% CI, 3–18%) in studies using 2D ultrasound and 11% (95% CI, 5–20%) in studies using a combination of 2D and 3D ultrasound (Figure 7).

Fifteen studies used a combination of direct (myometrial cysts, hyperechogenic islands, echogenic subendometrial lines and buds)<sup>48,70</sup> and indirect (asymmetrical myometrial thickening, globular uterus, fan-shaped shadowing, translesional vascularity, irregular and interrupted JZ)<sup>48,70</sup> ultrasound features of adenomyosis for the diagnosis<sup>14,16,18,20,22,24,27,59,61–65,67,68</sup>. One study used only an indirect feature of adenomyosis (poorly marginated hypoechoic and heterogeneous areas in the myometrium) for the diagnosis<sup>23</sup>. The pooled prevalence of isolated adenomyosis was 11% (95% CI, 7–16%) in studies using a combination of direct and indirect ultrasound features and 0.45% (95% CI, 0–1%) in the study in which only an indirect feature was used as the diagnostic criterion (Figure 8).

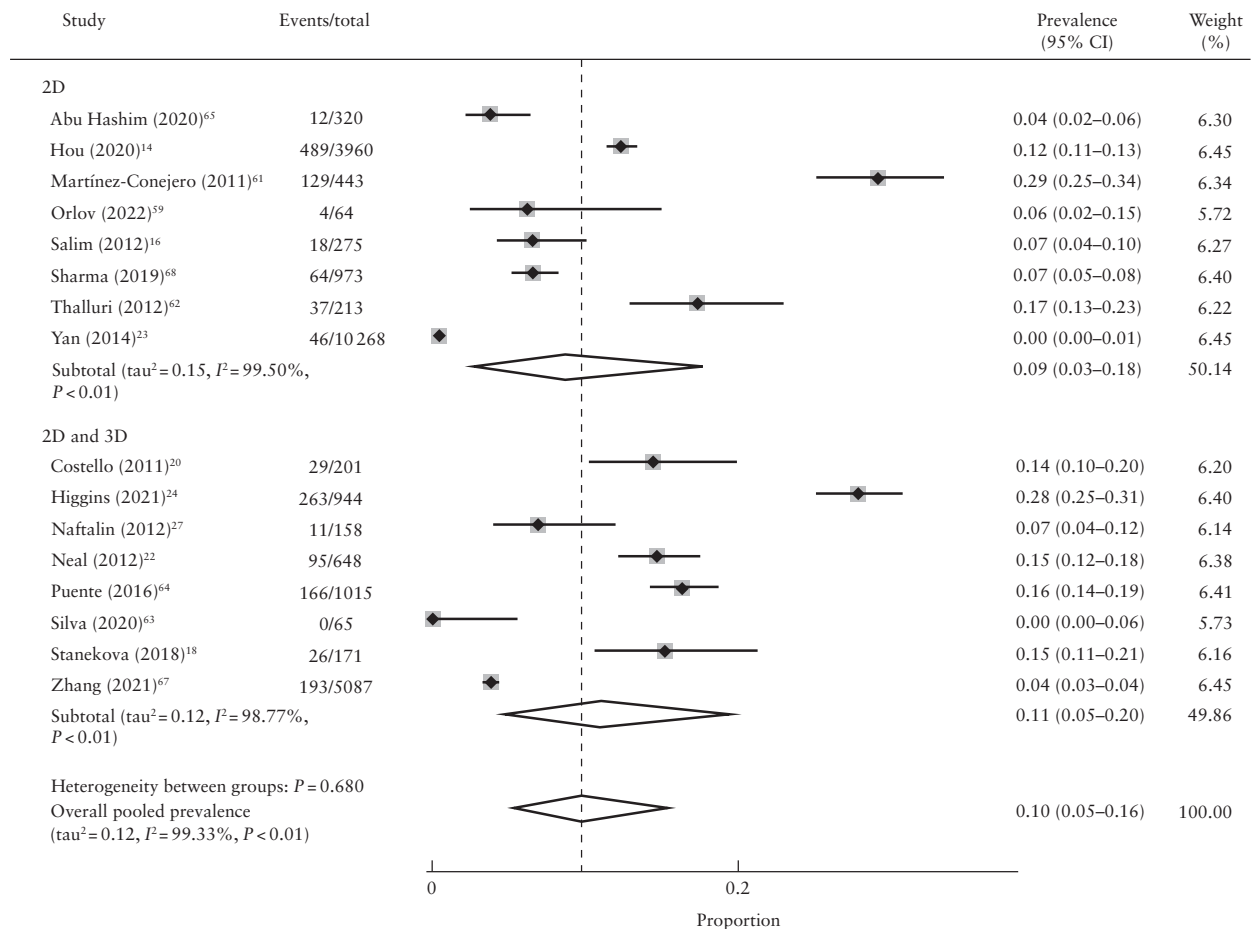


Figure 7 Forest plot showing prevalence of isolated adenomyosis in women with subfertility according to type of ultrasound. Only first author is given for each study. Random-effects model and Freeman–Tukey formula were used. 2D, two-dimensional; 3D, three-dimensional.

Metaregression analysis suggested that there was little effect of ultrasound diagnostic criteria ( $P=0.85$ ), type of ultrasound ( $P=0.49$ ) or direct/indirect features of adenomyosis ( $P=0.13$ ) on the prevalence of adenomyosis (Table 3).

### MRI as diagnostic modality

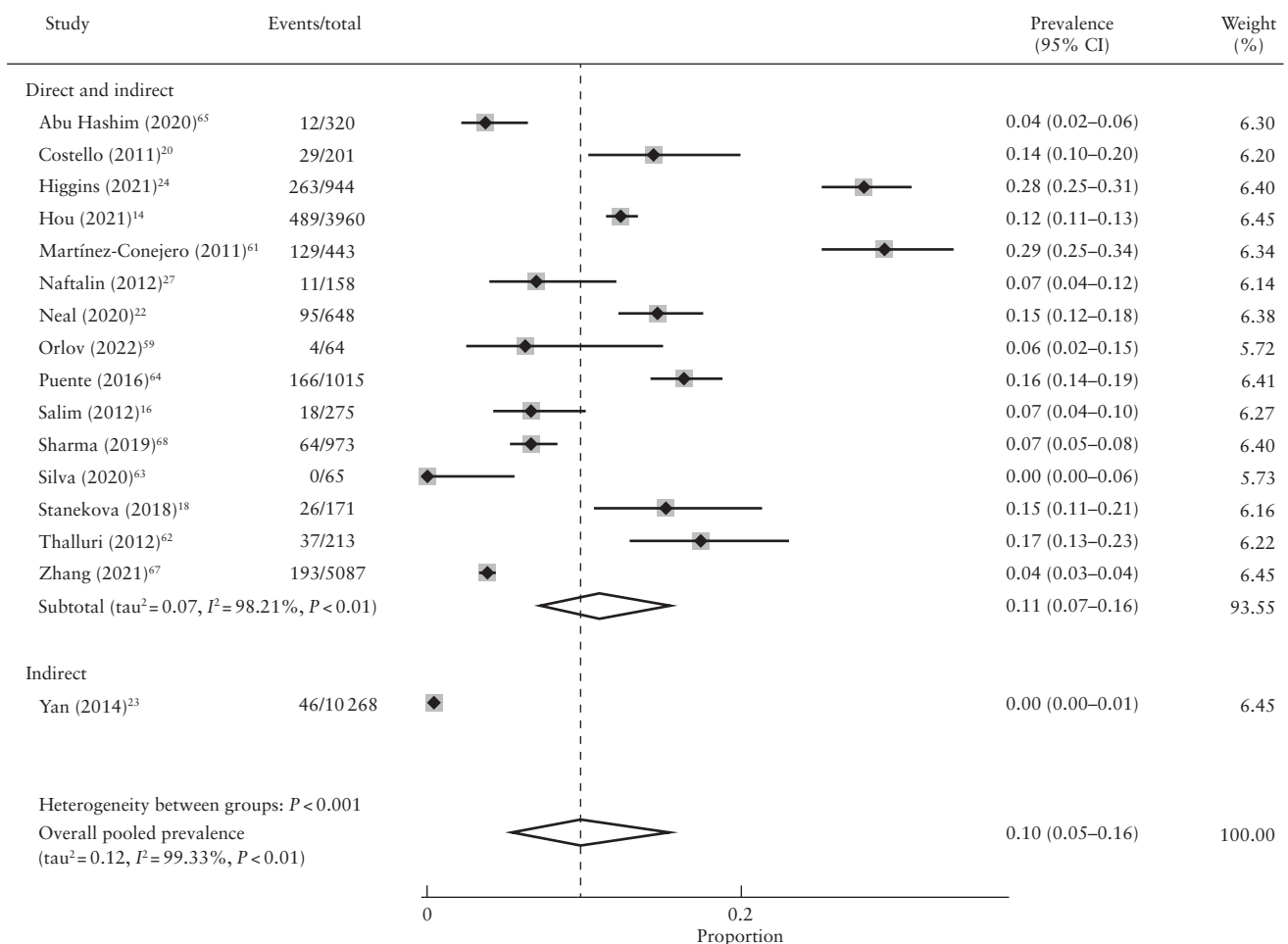
Five studies used MRI as the diagnostic modality of choice<sup>8,15,50,56,66</sup> and two studies used MRI in combination with ultrasound to confirm adenomyosis diagnosed on ultrasound<sup>65</sup> or in uncertain cases<sup>18</sup>. The MRI criteria used for the diagnosis of adenomyosis were uniform across four studies<sup>8,56,65,66</sup> and were based on previously published criteria<sup>71</sup>. Adenomyosis was diagnosed based on increased JZmax and JZmax-to-myometrial-thickness ratio, with or without high-signal-intensity myometrial spots. Focal adenomyosis was diagnosed based on the presence of a low-/mixed-signal-intensity mass with ill-defined margins. One study used MRI features of JZ thickness  $\geq 12$  mm and presence of subendometrial cysts for diagnosis of adenomyosis<sup>18</sup>. Importantly, the diagnostic criteria varied for studies conducted more than a decade ago, in which diagnosis was based on

the mean JZ thickness, defined as an average of three measurements of JZ in the midsagittal section of the uterus (anterior, posterior and fundal walls)<sup>15,50</sup>. This varied from  $> 7$  mm<sup>15</sup> to  $> 10$  mm<sup>50</sup>.

Of seven included MRI-based studies, the prevalence of isolated adenomyosis ranged from 4% to 19% across three studies in which MRI was performed by two radiologists with expertise in gynecological MRI<sup>8,50,56</sup>, and from 4% to 11% in two studies in which MRI was performed by one radiologist with expertise in gynecological imaging<sup>15,65</sup>. The prevalence was 14% in one study in which MRI data were rereviewed by the study investigator and three radiologists with expertise in pelvic MRI<sup>66</sup>. The operators were blinded to clinical data in three studies<sup>15,50,56</sup> and to previous imaging in three studies<sup>8,56,65</sup>. There was no operator information available for one study<sup>18</sup>.

### Geographical variation for isolated adenomyosis

In Australia, the prevalence of adenomyosis in women with subfertility ranged from 14% to 28%, with ultrasound used as the principal mode of diagnosis<sup>18,20,24,62</sup>. In Europe<sup>8,15,16,27,50,56,59,61,63,64,66</sup>, the



**Figure 8** Forest plot showing prevalence of isolated adenomyosis in women with subfertility according to ultrasound features of adenomyosis (indirect vs combination of direct and indirect signs). Only first author is given for each study. Random-effects model and Freeman–Tukey formula were used.

prevalence ranged from 0% to 29%. In Asia<sup>14,23,67,68</sup>, the prevalence ranged from 0.45% to 12%. Only one study reported on the prevalence of adenomyosis in Africa<sup>65</sup>, in which it was found to be 4%. In North America, the prevalence of adenomyosis was reported to be 15%<sup>22</sup>. Metaregression analysis including pooled prevalence estimates for subgroups based on geographical area suggested that adenomyosis was more prevalent in Australia compared with Asia ( $P = 0.01$ ) (Figure 9 and Table 3).

**Population variation for isolated adenomyosis**

The prevalence of adenomyosis ranged from 0.45% to 29% in women with subfertility undergoing ART<sup>14-16,18,20,22-24,61,62,64,66-68</sup>. The prevalence ranged from 0% to 19% in women with subfertility who were not undergoing ART<sup>8,27,50,56,59,63,65</sup>. Metaregression analysis including pooled prevalence estimates for subgroup based on population of women with subfertility suggested no difference in the prevalence in women with subfertility

undergoing ART compared with those not undergoing ART cycles ( $P = 0.17$ ) (Figure 10 and Table 3).

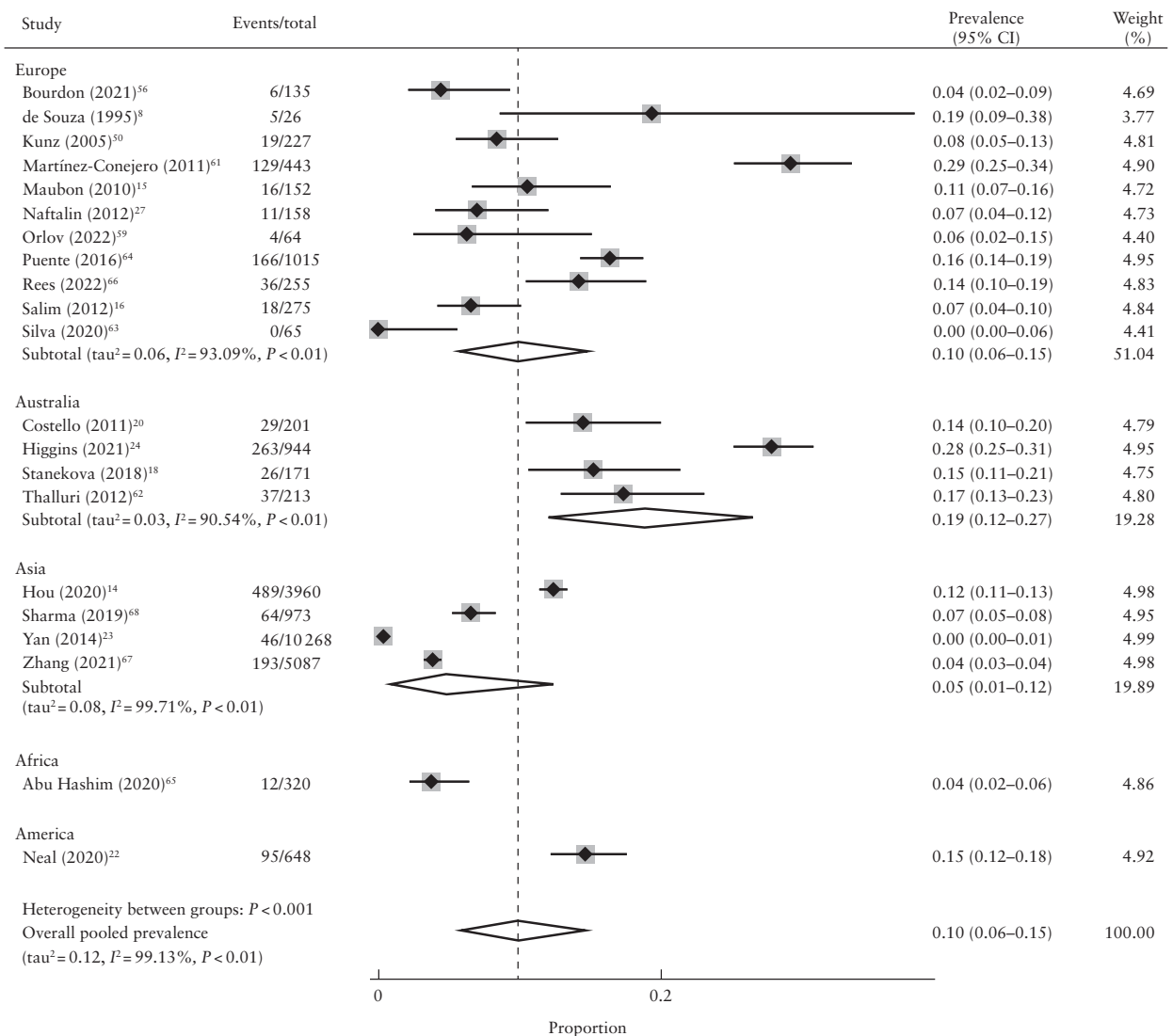
**Quality assessment of included studies**

All included studies were assessed for methodological quality using the CASP 2018 checklist. We judged all included studies to be of good quality. The summary of the quality assessment of 21 included studies can be found in Table S4.

**DISCUSSION**

**Main findings**

In this systematic review and meta-analysis of 21 cohort and cross-sectional studies including 25 600 participants, the prevalence of isolated adenomyosis in women with subfertility ranged between 0% to 29%. The prevalence ranged from 0% to 5% for adenomyosis with coexisting



**Figure 9** Forest plot showing prevalence of isolated adenomyosis in women with subfertility according to geographical area. Only first author is given for each study. Random-effects model and Freeman–Tukey formula were used.



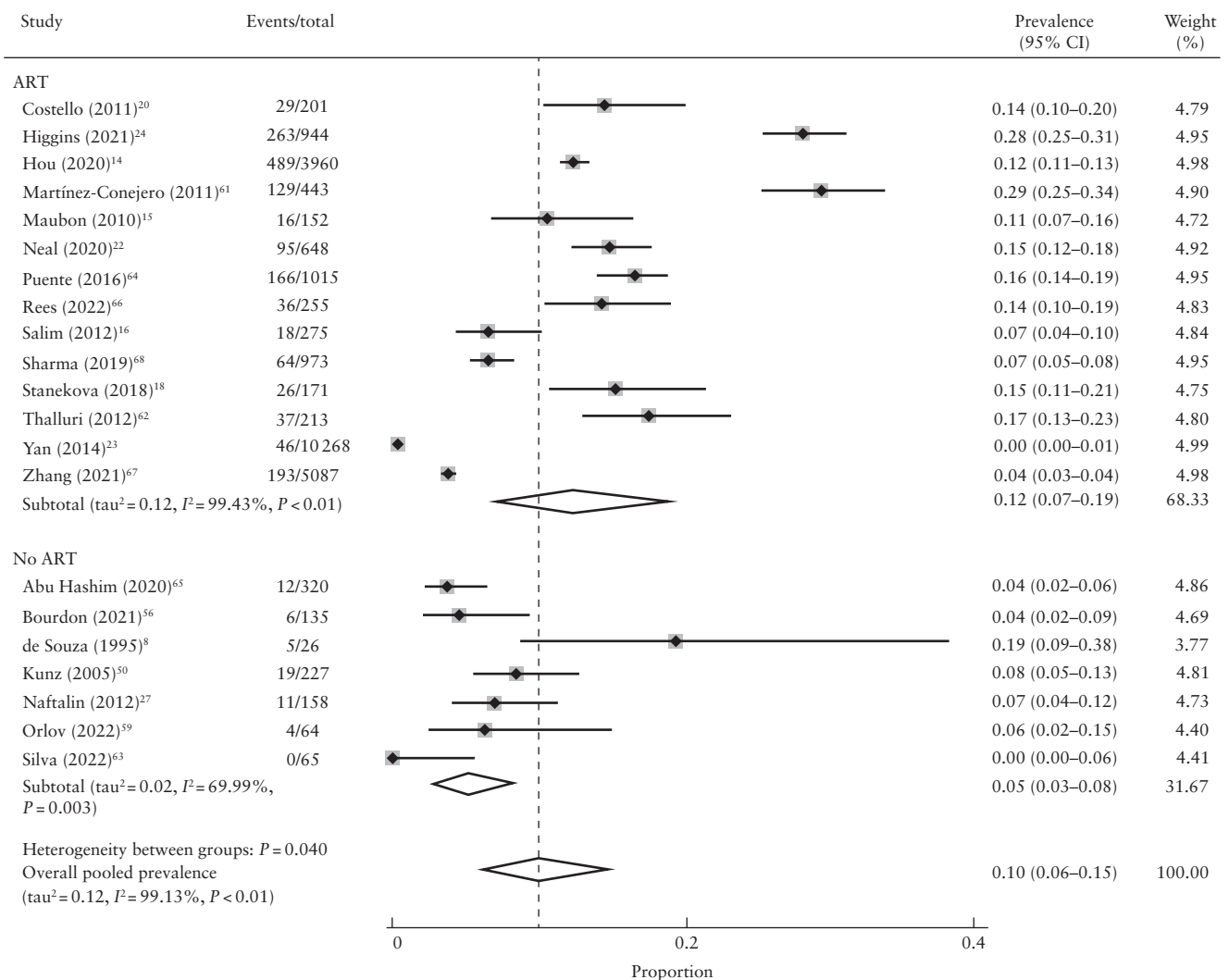
fibroids, from 0% to 56% for adenomyosis with coexisting endometriosis and from 0% to 35% for adenomyosis with coexisting endometriosis and/or fibroids. The pooled summary prevalence for all included studies was 10% for isolated adenomyosis, 1% for adenomyosis with coexisting fibroids, 6% for adenomyosis with coexisting endometriosis and 7% for adenomyosis with coexisting endometriosis and/or fibroids, with high heterogeneity between studies.

However, these findings may represent only the tip of the iceberg due to lack of appropriate use and awareness of standardized diagnostic criteria, leading to underdiagnosis. This is evident from the great difference noted in the prevalence of adenomyosis between the study using only one indirect sign<sup>23</sup>, in which the prevalence of isolated adenomyosis was 0.45%, and those using a combination of direct and indirect signs of adenomyosis, in which the pooled prevalence of isolated adenomyosis was 11% (95% CI, 7–16%) (Figure 8).

Furthermore, the prevalence of isolated adenomyosis varied across different geographical locations, with

Australia exhibiting the highest pooled prevalence of adenomyosis (19%), which was significantly higher compared with that in Asia (5%). This variation may be attributed to the following factors: a region-specific increase in adenomyosis in Australia, for unknown reasons; the use of a combination of multiple direct and indirect signs to diagnose adenomyosis; and the expertise of the operator performing the imaging assessment.

This systematic review confirms that transvaginal ultrasound remains the most widely available first-line diagnostic tool of choice for adenomyosis, followed by MRI<sup>2</sup>. The prevalence of isolated adenomyosis was 10% on both ultrasound and MRI and 7% using a combination of ultrasound and MRI. However, the diagnostic criteria varied across the included studies. The MUSA consensus published in 2015 provides a standardized terminology for describing ultrasound features associated with adenomyosis<sup>48</sup>. Although all included studies which started recruitment or analysis after the publication of MUSA guidelines adopted the MUSA criteria to diagnose adenomyosis, the number of features required to establish



**Figure 10** Forest plot showing prevalence of isolated adenomyosis in women with subfertility according to type of population (undergoing *vs* those not undergoing assisted reproductive technology (ART)). Only first author is given for each study. Random-effects model and Freeman–Tukey formula were used.

a diagnosis varied widely (Table 1)<sup>22,24,59,63,65,67</sup>. Though the MUSA criteria are based on a combination of 2D and 3D signs, two studies used only 2D features of MUSA criteria to diagnose adenomyosis<sup>59,65</sup>. All of this increases the risk of underdiagnosis.

In this review, variation was noted between the prevalence of isolated adenomyosis and that of adenomyosis with coexisting endometriosis and/or fibroids. Sonographic features of adenomyosis are highly prevalent in women with endometriosis<sup>28</sup>. Although there is a degree of pathophysiology and symptom overlap between the two conditions, they are different gynecological entities and often coexist<sup>27–29,72–74</sup>. However, this should be interpreted with caution because, in most of the included studies, it was difficult to gather information on whether endometriosis was confirmed histologically following surgical visualization.

### Comparison with existing literature

The prevalence of sonographic signs of adenomyosis in women attending a gynecology clinic has been estimated to be 20.9%<sup>27</sup>. In this systematic review, the pooled prevalence of isolated adenomyosis in women with subfertility was 10%. The different rate observed in this study may be attributed to a different population of interest (women with subfertility), inclusion of both symptomatic and asymptomatic women and exclusion of endometriosis and fibroids.

### Strengths and limitations

To our knowledge, this is the first systematic review to highlight the lack of cohesive data on the prevalence of adenomyosis in women with subfertility. We used a comprehensive search strategy of major bibliographic databases with no language restriction to maximize the global representativeness of data. This resulted in a large study population of 25 600 women across different continents. Furthermore, we employed robust methodology to analyze comprehensively our data. We determined the prevalence of adenomyosis in four clinically relevant groups and elaborated on the prevalence of isolated adenomyosis according to geographical location, diagnostic modality, diagnostic criteria, type of ultrasound, ultrasound features of adenomyosis and the use of ART.

One of the limitations of this review is the inherent heterogeneity of the included studies that were pooled in the meta-analysis of prevalence estimates. This stemmed from variation in participant characteristics, diagnostic modality and diagnostic criteria. Second, the quality assessment of the included studies was limited by the lack of a validated tool for assessing the methodological quality of prevalence studies. We used the CASP tool to reduce the subjectivity of the quality assessment<sup>51</sup>. The high heterogeneity of studies warrants caution when interpreting the pooled prevalence estimates.

**Table 3** Subgroup and metaregression analyses of prevalence of isolated adenomyosis according to geographical area, mode of diagnosis, type of ultrasound (US), diagnostic criteria, US features of adenomyosis and use of assisted reproductive technology (ART)

	Studies (n)	Prevalence of isolated adenomyosis (95% CI)	Tau <sup>2</sup>	I <sup>2</sup> (%)	P*
Overall	21	0.10 (0.06–0.15)	0.12	99.13	
Geographical area					
Australia	4	0.19 (0.12–0.27)	0.03	90.54	Reference
North America	1	0.15 (0.12–0.18)	—	—	0.47
Asia	4	0.05 (0.01–0.12)	0.08	99.71	0.01
Africa	1	0.04 (0.02–0.06)	—	—	0.08
Europe	11	0.10 (0.06–0.15)	0.06	93.09	0.14
Mode of diagnosis					
MRI	5	0.10 (0.06–0.14)	0.01	68.86	0.74
US and MRI	2	0.07 (0.05–0.09)	—	—	0.86
US	14	0.10 (0.05–0.16)	0.12	99.42	Reference
Type of US					
2D and 3D	8	0.11 (0.05–0.20)	0.12	98.77	0.49
2D	8	0.09 (0.03–0.18)	0.15	99.50	Reference
US diagnostic criteria					
MUSA	6	0.08 (0.01–0.18)	0.14	98.95	Reference
Non-MUSA	10	0.11 (0.05–0.20)	0.16	99.46	0.85
US signs of adenomyosis					
Direct and indirect	15	0.11 (0.07–0.16)	0.07	98.21	Reference
Indirect	1	0.00 (0.00–0.01)	—	—	0.13
Study population					
ART	14	0.12 (0.07–0.19)	0.12	99.43	Reference
No ART	7	0.05 (0.03–0.08)	0.02	69.99	0.17

\*Metaregression used to assess difference between subgroups and to determine *P*-values. *I*<sup>2</sup> and tau<sup>2</sup> were not generated for subgroups including fewer than four studies. 2D, two-dimensional; 3D, three-dimensional; MRI, magnetic resonance imaging; MUSA, morphological uterus sonographic assessment.

## Implications for clinical practice

The variation in the prevalence of adenomyosis in various subgroups and the high heterogeneity between studies reflects the lack of use of standardized criteria by studies conducted prior to publication of the MUSA criteria and inappropriate use after publication. The inappropriate use of MUSA criteria by the included studies, which is evident from the variation in the number of MUSA features required to establish the diagnosis of adenomyosis<sup>22,24,59,63,65,67</sup>, increases the risk of underdiagnosis due to potentially missed cases of mild adenomyosis. Appropriate training of clinicians and sonographers to diagnose adenomyosis using standardized criteria should be part of a basic gynecological ultrasound curriculum across the world. Identification of adenomyosis using a uniform ultrasound set of criteria would provide insight into the true burden of this condition.

## Implications for research

There is a need for future studies to use standardized and uniform diagnostic criteria (MUSA ultrasound consensus criteria) to diagnose adenomyosis. This would not only reduce interobserver variability, but also mitigate interstudy heterogeneity in future meta-analyses. It would also enable robust and uniform reporting of data on the burden of adenomyosis. The impact of adenomyosis on pregnancy outcome can be evaluated appropriately only if the disease is correctly and uniformly identified; otherwise, the evidence regarding this association may remain conflicting due to variation in the denominator.

## Conclusion

One in 10 women with subfertility have a diagnosis of isolated adenomyosis. The prevalence of adenomyosis varies according to the presence of concurrent endometriosis and/or fibroids.

## ACKNOWLEDGMENTS

The investigators thank Derick Yates for his assistance with the literature search strategy. In addition, the investigators acknowledge Angela Ward and Jay Grieves for their assistance in retrieving full-text articles and conference abstracts for a few studies. The authors thank the study investigators who had a key role in contributing to this review by providing us with additional information about their research, Dr I. F. Kozachenko, Dr J. Naftalin, Dr L. Jokubkiene, Dr M. Bourdon, R. Trinchant, M.Sc., Dr S. D. Reed, Dr V. Eisenberg, Dr Y. E. Şükür and Dr Z.-J. Chen. I.M. was supported by a doctoral research fellowship awarded by the Tommy's Charity and the University of Birmingham.

## REFERENCES

- Munro MG. Uterine polyps, adenomyosis, leiomyomas, and endometrial receptivity. *Fertil Steril* 2019; 111: 629–640.
- Chapron C, Vannuccini S, Santulli P, Abrão MS, Carmona F, Fraser IS, Gordts S, Guo S-W, Just P-A, Noël J-C, Pistofidis G, Bosch TVD, Petraglia F, Van den Bosch T. Diagnosing adenomyosis: an integrated clinical and imaging approach. *Hum Reprod Update* 2020; 26: 392–411.
- Li X, Liu X, Guo SW. Clinical profiles of 710 premenopausal women with adenomyosis who underwent hysterectomy. *J Obstet Gynaecol Res* 2014; 40: 485–494.
- Taran FA, Wallwiener M, Kabashi D, Rothmund R, Rall K, Kraemer B, Brucker SY. Clinical characteristics indicating adenomyosis at the time of hysterectomy: a retrospective study in 291 patients. *Arch Gynecol Obstet* 2012; 285: 1571–1576.
- Pinzauti S, Lazzeri L, Tosti C, Centini G, Orlandini C, Luisi S, Zupi E, Exacoustos C, Petraglia F. Transvaginal sonographic features of diffuse adenomyosis in 18–30-year-old nulligravid women without endometriosis: association with symptoms. *Ultrasound Obstet Gynecol* 2015; 46: 730–736.
- Abbott JA. Adenomyosis and Abnormal Uterine Bleeding (AUB-A): Pathogenesis, diagnosis, and management. *Best Pract Res Clin Obstet Gynaecol* 2017; 40: 68–81.
- Taran FA, Stewart EA, Brucker S. Adenomyosis: Epidemiology, Risk Factors, Clinical Phenotype and Surgical and Interventional Alternatives to Hysterectomy. *Geburtsilfe und Frauenheilkunde* 2013; 73: 924–931.
- de Souza NM, Brosens JJ, Schwieso JE, Paraschos T, Winston RM. The potential value of magnetic resonance imaging in infertility. *Clin Radiol* 1995; 50: 75–79.
- Maheshwari A, Gurunath S, Fatima F, Bhattacharya S. Adenomyosis and subfertility: a systematic review of prevalence, diagnosis, treatment and fertility outcomes. *Hum Reprod Update* 2012; 18: 374–392.
- Brosens JJ, de Souza NM, Barker FG. Uterine junctional zone: function and disease. *Lancet* 1995; 346: 558–560.
- Barrier BF, Malinowski MJ, Dick EJ, Jr., Hubbard GB, Bates GW. Adenomyosis in the baboon is associated with primary infertility. *Fertil Steril* 2003; 82 Suppl 3: 1091–1094.
- Harada T, Khine YM, Kaponis A, Nikellis T, Decavalas G, Taniguchi F. The Impact of Adenomyosis on Women's Fertility. *Obstet Gynecol Surv* 2016; 71: 557–568.
- Dueholm M. Uterine adenomyosis and infertility, review of reproductive outcome after *in-vitro* fertilization and surgery. *Acta Obstet Gynecol Scand* 2017; 96: 715–726.
- Hou X, Xing J, Shan H, Mei J, Sun Y, Yan G, Sun H, Wang J. The effect of adenomyosis on IVF after long or ultra-long GnRH agonist treatment. *Reprod Biomed Online* 2020; 41: 845–853.
- Maubon A, Faury A, Kapella M, Pouquet M, Piver P. Uterine junctional zone at magnetic resonance imaging: a predictor of *in vitro* fertilization implantation failure. *J Obstet Gynaecol Res* 2010; 36: 611–618.
- Salim R, Riris S, Saab W, Abramov B, Khadum I, Serhal P. Adenomyosis reduces pregnancy rates in infertile women undergoing IVF. *Reprod Biomed Online* 2012; 25: 273–277.
- Youm HS, Choi YS, Han HD. *In-vitro* fertilization and embryo transfer outcomes in relation to myometrial thickness. *J Assist Reprod Genet* 2011; 28: 1135–1140.
- Stanekova V, Woodman RJ, Tremellen K. The rate of euploid miscarriage is increased in the setting of adenomyosis. *Hum Reprod Open* 2018; 2018: hoy011.
- Benaglia L, Cardellicchio L, Leonardi M, Faulisi S, Vercellini P, Paffoni A, Somigliana E, Fedele L. Asymptomatic adenomyosis and embryo implantation in IVF cycles. *Reprod Biomed Online* 2014; 29: 606–611.
- Costello MF, Lindsay K, McNally G. The effect of adenomyosis on *in-vitro* fertilisation and intra-cytoplasmic sperm injection treatment outcome. *Eur J Obstet Gynecol Reprod Biol* 2011; 158: 229–234.
- Mijatovic V, Florijn E, Halim N, Schats R, Hompes P. Adenomyosis has no adverse effects on IVF/ICSI outcomes in women with endometriosis treated with long-term pituitary down-regulation before IVF/ICSI. *Eur J Obstet Gynecol Reprod Biol* 2010; 151: 62–65.
- Neal S, Morin S, Werner M, Gueye NA, Pirtea P, Patounakis G, Scott R Jr, Goodman L. Three-dimensional ultrasound diagnosis of adenomyosis is not associated with adverse pregnancy outcome following single thawed euploid blastocyst transfer: prospective cohort study. *Ultrasound Obstet Gynecol* 2020; 56: 611–617.
- Yan L, Ding L, Tang R, Chen ZJ. Effect of adenomyosis on *in-vitro* fertilization/intracytoplasmic sperm injection outcomes in infertile women: a retrospective cohort study. *Gynecol Obstet Invest* 2014; 77: 14–18.
- Higgins C, Fernandes H, Costa FD, Martins WP, Vollenhoven B, Healey M. The impact of adenomyosis on IVF outcomes: a prospective cohort study. *Hum Reprod Open* 2021; 2021: hoab015.
- Cozzolino M, Tartaglia S, Pellegrini L, Troiano G, Rizzo G, Petraglia F. The Effect of Uterine Adenomyosis on IVF Outcomes: a Systematic Review and Meta-analysis. *Reprod Sci* 2022; 29: 3177–3193.
- Nirgianakis K, Kalaitzopoulos DR, Schwartz ASK, Spaanderman M, Kramer BW, Mueller MD, Mueller M. Fertility, pregnancy and neonatal outcomes of patients with adenomyosis: a systematic review and meta-analysis. *Reprod Biomed Online* 2021; 42: 185–206.
- Naftalin J, Hoo W, Pateman K, Mavrelou D, Holland T, Jurkovic D. How common is adenomyosis? A prospective study of prevalence using transvaginal ultrasound in a gynaecology clinic. *Hum Reprod* 2012; 27: 3432–3439.
- Eisenberg VH, Arbib N, Schiff E, Goldenberg M, Seidman DS, Soriano D. Sonographic Signs of Adenomyosis Are Prevalent in Women Undergoing Surgery for Endometriosis and May Suggest a Higher Risk of Infertility. *Biomed Res Int* 2017; 2017: 8967803.
- Bromley B, Shipp TD, Benacerraf B. Adenomyosis: sonographic findings and diagnostic accuracy. *J Ultrasound Med* 2000; 19: 529–534.
- Wallwiener M, Taran FA, Rothmund R, Kasperkowiak A, Auwärter G, Ganz A, Kraemer B, Abele H, Schönfisch B, Isaacson KB, Brucker SY. Laparoscopic supracervical hysterectomy (LSH) versus total laparoscopic hysterectomy (TLH): an implementation study in 1,952 patients with an analysis of risk factors for

- conversion to laparotomy and complications, and of procedure-specific re-operations. *Arch Gynecol Obstet* 2013; **288**: 1329–1339.
31. Page MJ, McKenzie JE, Bossuyt PM, Boutron I, Hoffmann TC, Mulrow CD, Shamseer L, Tetzlaff JM, Akl EA, Brennan SE, Chou R, Glanville J, Grimshaw JM, Hróbjartsson A, Lalu MM, Li T, Loder EW, Mayo-Wilson E, McDonald S, McGuinness LA, Stewart LA, Thomas J, Tricco AC, Welch VA, Whiting P, Moher D. The PRISMA 2020 statement: an updated guideline for reporting systematic reviews. *BMJ* 2021; **372**: n71.
  32. Zegers-Hochschild F, Adamson GD, Dyer S, Racowsky C, de Mouzon J, Sokol R, Rienzi L, Sunde A, Schmidt L, Cooke ID, Simpson JL, van der Poel S. The International Glossary on Infertility and Fertility Care, 2017. *Hum Reprod* 2017; **32**: 1786–1801.
  33. Togashi K, Ozasa H, Konishi I, Itoh H, Nishimura K, Fujisawa I, Noma S, Sagoh T, Minami S, Yamashita K. Enlarged uterus: differentiation between adenomyosis and leiomyoma with MR imaging. *Radiology* 1989; **171**: 531–534.
  34. Sakhel K, Abuhamad A. Sonography of adenomyosis. *J Ultrasound Med* 2012; **31**: 805–808.
  35. Reinhold C, Tafazolli F, Wang L. Imaging features of adenomyosis. *Hum Reprod Update* 1998; **4**: 337–349.
  36. Reinhold C, McCarthy S, Bret PM, Mehio A, Atri M, Zakarian R, Glaude Y, Liang L, Seymour RJ. Diffuse adenomyosis: comparison of endovaginal US and MR imaging with histopathologic correlation. *Radiology* 1996; **199**: 151–158.
  37. Novellas S, Chassang N, Delotte J, Toullalan O, Chevallier A, Bouaziz J, Chevallier P. MRI characteristics of the uterine junctional zone: from normal to the diagnosis of adenomyosis. *AJR Am J Roentgenol* 2011; **196**: 1206–1213.
  38. Meredith SM, Sanchez-Ramos L, Kaunitz AM. Diagnostic accuracy of transvaginal sonography for the diagnosis of adenomyosis: systematic review and metaanalysis. *Am J Obstet Gynecol* 2009; **201**: 107.e1–6.
  39. Levy G, Dehaene A, Laurent N, Lernout M, Collinet P, Lucot JP, Lions C, Poncelet E. [Mise au point sur l'adenomyose]. *J Radiol Diagn Inter* 2013; **94**: 3–25.
  40. Kunz G, Beil D, Huppert P, Leyendecker G. Structural abnormalities of the uterine wall in women with endometriosis and infertility visualized by vaginal sonography and magnetic resonance imaging. *Hum Reprod* 2000; **15**: 76–82.
  41. Dueholm M. Transvaginal ultrasound for diagnosis of adenomyosis: a review. *Best Pract Res Clin Obstet Gynaecol* 2006; **20**: 569–582.
  42. Devlieger R, D'Hooghe T, Timmerman D. Uterine adenomyosis in the infertility clinic. *Hum Reprod Update* 2003; **9**: 139–147.
  43. Chapron C, Tosti C, Marcellin L, Bourdon M, Lafay-Pillet M-C, Millischer A-E, Streuli I, Borghese B, Petraglia F, Santulli P. Relationship between the magnetic resonance imaging appearance of adenomyosis and endometriosis phenotypes. *Hum Reprod* 2017; **32**: 1393–1401.
  44. Brosens JJ, de Souza NM, Barker FG, Paraschos T, Winston RM. Endovaginal ultrasonography in the diagnosis of adenomyosis uteri: identifying the predictive characteristics. *Br J Obstet Gynaecol* 1995; **102**: 471–474.
  45. Bazot M, Darai E. Role of transvaginal sonography and magnetic resonance imaging in the diagnosis of uterine adenomyosis. *Fertil Steril* 2018; **109**: 389–397.
  46. Bazot M, Cortez A, Darai E, Rouger J, Chopier J, Antoine JM, Uzan S. Ultrasonography compared with magnetic resonance imaging for the diagnosis of adenomyosis: correlation with histopathology. *Hum Reprod* 2001; **16**: 2427–2433.
  47. Arnold LL, Ascher SM, Schrufer JJ, Simon JA. The nonsurgical diagnosis of adenomyosis. *Obstet Gynecol* 1995; **86**: 461–465.
  48. Van den Bosch T, Dueholm M, Leone FP, Valentin L, Rasmussen CK, Votino A, Van Schoubroeck D, Landolfo C, Installé AJ, Guerriero S, Exacoustos C, Gordts S, Benacerraf B, D'Hooghe T, De Moor B, Brölmann H, Goldstein S, Epstein E, Bourne T, Timmerman D. Terms, definitions and measurements to describe sonographic features of myometrium and uterine masses: a consensus opinion from the Morphological Uterus Sonographic Assessment (MUSA) group. *Ultrasound Obstet Gynecol* 2015; **46**: 284–298.
  49. Van den Bosch T, de Buijn AM, de Leeuw RA, Dueholm M, Exacoustos C, Valentin L, Bourne T, Timmerman D, Huirne JAF. Sonographic classification and reporting system for diagnosing adenomyosis. *Ultrasound Obstet Gynecol* 2019; **53**: 576–582.
  50. Kunz G, Beil D, Huppert P, Noe M, Kissler S, Leyendecker G. Adenomyosis in endometriosis: prevalence and impact on fertility. Evidence from magnetic resonance imaging. *Hum Reprod* 2005; **20**: 2309–2316.
  51. Critical Appraisal Skills Programme (CASP) Cohort Study Checklist. <https://casp-uk.net/casp-tools-checklists/>.
  52. Barker TH, Migliavaca CB, Stein C, Colpani V, Falavigna M, Aromataris E, Munn Z. Conducting proportional meta-analysis in different types of systematic reviews: a guide for synthesisers of evidence. *BMC Med Res Methodol* 2021; **21**: 189.
  53. Nyaga VN, Arbyn M, Aerts M. Metaprop: a Stata command to perform meta-analysis of binomial data. *Arch Public Health* 2014; **72**: 39.
  54. Deeks JJ, Altman DG, Bradburn MJ. Statistical Methods for Examining Heterogeneity and Combining Results from Several Studies in Meta-Analysis. In *Systematic Reviews in Health Care*. 2001; 285–312. DOI: <https://doi.org/10.1002/9780470693926.ch15>.
  55. Atabekoglu CS, Şükür YE, Kalafat E, Özmen B, Berker B, Aytaç R, Sönmez M. The association between adenomyosis and recurrent miscarriage. *Eur J Obstet Gynecol Reprod Biol* 2020; **250**: 107–111.
  56. Bourdon M, Oliveira J, Marcellin L, Santulli P, Bordonne C, Maitrot Mantelet L, Millischer AE, Plu Bureau G, Chapron C. Adenomyosis of the inner and outer myometrium are associated with different clinical profiles. *Hum Reprod* 2021; **36**: 349–357.
  57. Yu O, Schulze-Rath R, Grafton J, Hansen K, Scholes D, Reed SD. Adenomyosis incidence, prevalence and treatment: United States population-based study 2006–2015. *Am J Obstet Gynecol* 2020; **223**: 94.e1–10.
  58. Loughlin AM, Chiuvè SE, Reznor G, Doherty M, Missmer SA, Chomistek AK, Enger C. Method used to identify adenomyosis and potentially undiagnosed adenomyosis in a large, U.S. electronic health record database. *Pharmacoepidemiol Drug Saf* 2021; **30**: 1675–1686.
  59. Orlov S, Jokubkiene L. Prevalence of endometriosis and adenomyosis at transvaginal ultrasound examination in symptomatic women. *Acta Obstet Gynecol Scand* 2022; **101**: 524–531.
  60. Trinchant R, Cruz M, Requena A. Adenomyosis decreases the live birth rate but may not affect perinatal outcomes in assisted reproductive cycles. *Int J Gynaecol Obstet* 2022; **159**: 918–922.
  61. Martínez-Conejero JA, Morgan M, Montesinos M, Fortuño S, Meseguer M, Simón C, Horcajadas JA, Pellicer A. Adenomyosis does not affect implantation, but is associated with miscarriage in patients undergoing oocyte donation. *Fertil Steril* 2011; **96**: 943–950.
  62. Thalluri V, Tremellen KP, Thalluri V, Tremellen KP. Ultrasound diagnosed adenomyosis has a negative impact on successful implantation following GnRH antagonist IVF treatment. *Hum Reprod* 2012; **27**: 3487–3492.
  63. Silva V, Ramos FF, Bras AFM, Santos RFS, Xavier M, Miguelote RFO. Junctional Zone in Infertile Women: A Three-dimensional Ultrasound Study. *Rev Bras Ginecol Obstet* 2020; **42**: 152–159.
  64. Puente JM, Fabris A, Patel J, Patel A, Cerrillo M, Requena A, Garcia-Velasco JA. Adenomyosis in infertile women: prevalence and the role of 3D ultrasound as a marker of severity of the disease. *Reprod Biol Endocrinol* 2016; **14**: 60.
  65. Abu Hashim H, Elaraby S, Fouda AA, El Rakhawy M. The prevalence of adenomyosis in an infertile population: a cross-sectional study. *Reprod Biomed Online* 2020; **40**: 842–850.
  66. Rees CO, Rupert IAM, Nederend J, Consten D, Mischi M, H AAMvV, Schoot BC. Women with combined adenomyosis and endometriosis on MRI have worse IVF/ICSI outcomes compared to adenomyosis and endometriosis alone: A matched retrospective cohort study. *Eur J Obstet Gynecol Reprod Biol* 2022; **271**: 223–234.
  67. Zhang XP, Zhang YF, Shi R, Zhang YJ, Zhang XL, Hu XM, Hu XY, Hu YJ. Pregnancy outcomes of infertile women with ultrasound-diagnosed adenomyosis for *in-vitro* fertilization and frozen-thawed embryo transfer. *Arch Gynecol Obstet* 2021; **304**: 1089–1096.
  68. Sharma S, Bathwal S, Agarwal N, Chattopadhyay R, Saha I, Chakravarty B. Does presence of adenomyosis affect reproductive outcome in IVF cycles? A retrospective analysis of 973 patients. *Reprod Biomed Online* 2019; **38**: 13–21.
  69. Paliawadana T, Wijesinghe P, Seneviratne H. Aetiology of infertility among females seeking treatment at a tertiary care hospital in Sri Lanka. *Ceylon Med J* 2012; **57**.
  70. Harmsen MJ, Van den Bosch T, de Leeuw RA, Dueholm M, Exacoustos C, Valentin L, Hehenkamp WJK, Groenman F, De Bruyn C, Rasmussen C, Lazzeri L, Jokubkiene L, Jurkovic D, Naftalin J, Tellum T, Bourne T, Timmerman D, Huirne JAF. Consensus on revised definitions of Morphological Uterus Sonographic Assessment (MUSA) features of adenomyosis: results of modified Delphi procedure. *Ultrasound Obstet Gynecol* 2022; **60**: 118–131.
  71. Bazot M, Cortez A, Darai E, Rouger J, Chopier J, Antoine J-M, Uzan S. Ultrasonography compared with magnetic resonance imaging for the diagnosis of adenomyosis: correlation with histopathology. *Hum Reprod* 2001; **16**: 2427–2433.
  72. Exacoustos C, Luciano D, Corbett B, De Felice G, Di Felicianantonio M, Luciano A, Zupi E. The uterine junctional zone: a 3-dimensional ultrasound study of patients with endometriosis. *Am J Obstet Gynecol* 2013; **209**: 248.e–7.
  73. Isaacson K, Loring M. Symptoms of Adenomyosis and Overlapping Diseases. *Semin Reprod Med* 2020; **38**: 144–150.
  74. Leyendecker G, Wildt L, Mall G. The pathophysiology of endometriosis and adenomyosis: tissue injury and repair. *Arch Gynecol Obstet* 2009; **280**: 529–538.

## SUPPORTING INFORMATION ON THE INTERNET

The following supporting information may be found in the online version of this article:



**Table S1** Search strategy

**Table S2** Characteristics of excluded studies

**Table S3** Correspondence with study authors

**Table S4** Quality assessment of included studies using Critical Appraisal Skills Program (CASP) 2018 checklist for cohort studies