

Adjunctive treatment in juvenile nasopharyngeal angiofibroma

Scholfield, Daniel W; Brundler, Marie-Anne; McDermott, Ann-Louise; Mussai, Francis; Kearns, Pamela

DOI:

[10.1097/MPH.0000000000000524](https://doi.org/10.1097/MPH.0000000000000524)

License:

None: All rights reserved

Document Version

Peer reviewed version

Citation for published version (Harvard):

Scholfield, DW, Brundler, M-A, McDermott, A-L, Mussai, F & Kearns, P 2016, 'Adjunctive treatment in juvenile nasopharyngeal angiofibroma: How should we approach recurrence?', *Journal of pediatric hematology/oncology*, vol. 38, no. 3, pp. 235-239. <https://doi.org/10.1097/MPH.0000000000000524>

[Link to publication on Research at Birmingham portal](#)

Publisher Rights Statement:

Final Version of Record published as detailed above.

Checked June 2016

General rights

Unless a licence is specified above, all rights (including copyright and moral rights) in this document are retained by the authors and/or the copyright holders. The express permission of the copyright holder must be obtained for any use of this material other than for purposes permitted by law.

- Users may freely distribute the URL that is used to identify this publication.
- Users may download and/or print one copy of the publication from the University of Birmingham research portal for the purpose of private study or non-commercial research.
- User may use extracts from the document in line with the concept of 'fair dealing' under the Copyright, Designs and Patents Act 1988 (?)
- Users may not further distribute the material nor use it for the purposes of commercial gain.

Where a licence is displayed above, please note the terms and conditions of the licence govern your use of this document.

When citing, please reference the published version.

Take down policy

While the University of Birmingham exercises care and attention in making items available there are rare occasions when an item has been uploaded in error or has been deemed to be commercially or otherwise sensitive.

If you believe that this is the case for this document, please contact UBIRA@lists.bham.ac.uk providing details and we will remove access to the work immediately and investigate.

Adjunctive Treatment In Juvenile Nasopharyngeal Angiofibroma: How Should We Approach Recurrence?

Daniel W Scholfield BSc (Hons) MBChB¹, Marie-Anne Brundler MD FRCPATH², Ann-Louise McDermott
FDS RCS FRCS³, Francis Mussai MA (Oxon) BM BCh DPhil MRCPCH^{1,4}, Pamela Kearns MBChB BSc
(Hons) PhD FRCPCH^{1,4}

¹Paediatric Oncology Department, Birmingham Children's Hospital

²Department of Pathology, Birmingham Children's Hospital, Birmingham UK

³ENT Department, Birmingham Children's Hospital, Birmingham UK

⁴School of Cancer Sciences, University of Birmingham, UK

Disclosures:

The authors have no conflicts of interest or funding to disclose.

Correspondence:

Daniel Scholfield

Whipps Cross Hospital

London, UK

E11 1NR

Email: danwscholfield@doctors.org.uk

Telephone: +44(0) 7817 262259

Key words:

Juvenile Nasopharyngeal Angiofibroma

Radiotherapy

Flutamide

Dexamethasone

Abstract

1
2 A recent case of advanced, recurrent Juvenile Nasopharyngeal Angiofibroma (JNA) at our institution
3
4 has highlighted the limited evidence regarding adjunctive treatment. We present the case of a ten
5
6 year old boy who is the first to undergo multiple staged surgical resections alongside vincristine
7
8 treatment. We performed a review of the literature analyzing the roles of radiation therapy,
9
10 cytotoxic drugs and novel targeted agents in JNA relapse. Small cohort studies suggest radiotherapy
11
12 and flutamide are the most rational treatment options for residual and recurrent JNA. Our review
13
14 highlights the need for further research into the management of primary and recurrent JNA.
15
16
17
18
19
20
21
22

Introduction

23
24
25
26 Juvenile nasopharyngeal angiofibroma (JNA) is a benign, highly vascular and locally invasive lesion
27
28 that develops almost exclusively in the nasopharynx of peripubertal boys. JNA represents 0.5% of all
29
30 head and neck tumors, with an incidence of approximately 1:150,000. Large cohort studies report
31
32 median ages of 15 years (range 10-24 years) and 18.5 years (range 18-35 years) (1).
33
34
35
36
37
38
39

40 Histologically JNA is pseudocapsulated, characterized by an irregular vascular component embedded
41
42 in a fibrous stroma, densely populated by collagen and fibroblasts. Mitotic figures are rare and the
43
44 vessels are organized in clusters, without elastic fibers in their walls or a muscular lining in smaller
45
46 vessels (2). Electron microscopy and immunohistological studies demonstrating morphological
47
48 irregularities such as focal lack of pericytes, discontinuous vascular basal laminae and irregularity of
49
50 smooth muscle layers, suggest that JNA is not a tumor, but a vascular malformation (3). JNA
51
52 originates from the first branchial arch artery and usually regresses between embryological day 22
53
54 and 24 to form a venous plexus in the sphenopalatine foramen, the typical site of JNA origin.
55
56
57
58
59 Incomplete regression of the vascular plexus leaves it vulnerable to growth stimulation at the time of
60
61
62
63
64
65

1 adolescence to form JNA (3). Predominance in adolescent males suggests a hormonal influence on
2 growth, supported by the presence of androgen receptors on JNA cell membranes (4). The male to
3
4 female ratio of patients in our review is 94:0.
5
6
7
8
9

10 JNA is locally destructive, often extending intracranially into the paranasal sinuses and along the
11 skull base (5). Patients present with nasal obstruction, facial numbness, headaches and visual
12
13 changes (6). Nasal endoscopy typically reveals a large hypervascularized, lobulated mass extending
14
15 into the nasopharynx and diagnosis is confirmed with computed tomography (CT), which usually
16
17 reveals widening of the sphenopalatine foramen and extension into surrounding areas (5). Contrast
18
19 enhanced magnetic resonance imaging (MRI) shows further characteristic features - "flow voids"
20
21 caused by the highly vascular nature of JNA. MRI is superior to CT for diagnosis and surgical planning
22
23 due to greater sensitivity in distinguishing JNA from retained mucous or inflammation, eliminating
24
25 other benign or malignant tumors and assessing intracranial extent (1).
26
27
28
29
30
31
32
33
34
35

36 Surgery remains the mainstay of treatment, preceded by intravascular embolization to reduce intra-
37
38 operative bleeding (5). Adjunctive radiotherapy and chemotherapy are uncommon, but may be the
39
40 only option in inoperable recurrence. A recent case at our institution has highlighted the
41
42 exceptionally limited evidence regarding adjunctive treatment and questions how best to approach
43
44 recurrence.
45
46
47
48
49
50
51
52

53 **Case**

54
55
56 A ten year old boy presented to our institution with a two month history of deteriorating vision and
57
58 proptosis of his right eye. He complained of nasal obstruction and sleep disordered breathing for
59
60
61
62
63
64
65

1 more than a year and examination revealed a large right-sided nasal mass, paraesthesia of his right
2 cheek, nose and teeth, a right middle ear effusion and displacement of the right tonsil. CT and MRI
3 exhibited features consistent with Stage 4 JNA (Fisch classification, see Table I) (Figure 1). The
4 patient underwent pre-operative embolization of the right internal maxillary artery and other
5 significant bilateral tumor feeding vessels with Onyx (Ethylene vinyl alcohol copolymer), followed by
6 the first stage of endoscopic transnasal resection. An extended endoscopic approach utilizing a
7 Denker's maxilotomy was performed, although extensive blood loss limited the procedure.
8
9
10
11
12
13
14
15
16
17
18
19
20

21 Histology of the resected specimen showed a spindle cell lesion containing numerous angulated and
22 circular vascular spaces (Figure 2a). Cells showed relatively plump nuclei with small indistinct
23 nucleoli and the background stroma was mainly composed of dense fibrous tissue.
24
25
26

27 Immunohistochemistry revealed the cells to be strongly positive for β -catenin (Figure 2b) and
28 vimentin (Figure 2c). CD31 and CD34 highlighted angulated and larger ectatic vessels.
29
30
31
32
33
34
35

36 Post-operative MRI scan confirmed a substantial residual tumor encasing the right internal carotid
37 artery (ICA), with extension between the pterygoid muscles down to the angle of the mandible. The
38 case was discussed by pediatric oncology, radiation oncology and otolaryngology teams at a multi-
39 disciplinary meeting, with particular focus on the problem of excessive blood loss despite
40 embolization.
41
42
43
44
45
46
47
48
49
50
51

52 No standard therapeutic approach exists for recurrent and unresectable JNA. Based on a small case
53 series the patient was treated with 1.5mg/m² of vincristine weekly for four weeks, with the aim of
54 assessing chemosensitivity prior to surgery.
55
56
57
58
59
60
61
62
63
64
65

1
2
3 Restaging MRI six weeks post-operatively showed the tumor had failed to respond and had
4
5 increased in size to 75 x 75 x 45 mm (anteroposterior x craniocaudal x transverse long axis),
6
7 categorized by Response Evaluation Criteria in Solid Tumors (RECIST) as progressive disease. Further
8
9 endoscopic resection with embolization took place, again limited by blood loss and the risk of
10
11 deranged clotting from repeated transfusions. Extensive resection via an expanded endonasal
12
13 approach (EEA) was subsequently achieved. Four months post-surgery, MRI scans revealed a
14
15 residuum adjacent to the internal carotid artery. The child has since made an excellent recovery and
16
17 is currently under surveillance. MRI scans show no disease progression 28 months post-surgery via
18
19 EEA.
20
21
22
23
24
25
26
27

28 This case raises the question of management options in the event of further growth. A review of
29
30 possible therapeutic options is outlined below and summary provided in Table II.
31
32
33
34
35
36

37 **Discussion and Review of Adjunctive Treatment**

38
39
40 Biopsy is contra-indicated in JNA due to its highly vascularized nature. Accurate diagnosis and
41
42 differentiation from parameningeal tumors relies on MRI imaging, whilst CT provides bony land
43
44 marks for surgery. Characteristic signs on MRI include signal voids that represent major intra-
45
46 lesional vessels, “finger-like” projections of JNA extension into soft tissue and submucosal invasion
47
48 of the basisphenoid (1). Combining these characteristics leads to the diagnosis of JNA. There have
49
50 been no reports in the literature of these characteristic signs being present in other lesions.
51
52
53
54
55
56
57
58
59
60
61
62
63
64
65

1 JNA is principally a surgical lesion that should initially be discussed with the otolaryngology team
2 after recurrence. Transnasal endoscopic resections are most effective in combination with pre-
3
4 operative embolization. The surgical approach involves extensive exposure of the tumor, utilizing
5
6 resection of the posterior third of the nasal septum and the posterior wall of the maxillary sinus.
7
8 Accurate subperiosteal dissection and extensive drilling of any bone adhered to by JNA completes
9
10 the procedure (2). Endoscopic excision of smaller tumors is the gold standard for surgical resection
11
12 due to significantly reduced blood loss. The EEA approach utilizes the same principles in tackling
13
14 larger lesions that extend intracranially and into the skull base, the key advantage being that it
15
16 provides access to more deeply seated lesions (1).
17
18
19
20
21
22
23
24

25 Control of bleeding is the most significant intraoperative challenge, whilst skull base infiltration or
26
27 encasement of the ICA provide further surgical hazards that may result in inoperability. In contrast to
28
29 malignancies of the nasopharynx, such as rhabdomyosarcoma, a “piecemeal” resection is acceptable
30
31 and often preferable when approaching difficult anatomical locations (1). Endoscopic surgery is
32
33 contraindicated in residual tumors involving critical areas and it is in these cases where adjuvant
34
35 therapy needs to be discussed.
36
37
38
39
40
41
42
43

44 Radiation therapy (RT) for JNA is a contentious topic due to the potential for malignant
45
46 transformation to fibrosarcoma, although only two cases are reported in the literature, occurring 18
47
48 and 20 years after radiation (7, 8). Other long term sequelae include growth impairment,
49
50 encephalopathy and secondary malignancies (1, 9). Nevertheless, adjuvant radiotherapy is
51
52 recommended by some authors after incomplete resection (5). McAfee et al used RT to treat 22
53
54 adolescent males with high stage JNA, with a total dose range of 30 to 36 Gy (9). Ten were for
55
56 primary treatment and 12 for recurrence, resulting in local control in 90% of patients, with a median
57
58
59
60
61
62
63
64
65

1 follow up of 12.7 years. However, late complications occurred in 32% of patients, including transient
2 ischemic vascular stroke and basal cell carcinoma. Long term complications also occurred in a study
3
4 of 27 patients, where RT was used as primary treatment (30-55 Gy) for advanced JNA (10). The
5
6 recurrence rate was 15% at 2 to 5 years and 15% suffered complications. Nevertheless, the authors
7
8 concluded that the risk of surgical intervention in advanced JNA is greater than the risk of fatal RT
9
10 complications. The concern for damage to surrounding structures by conventional RT may be
11
12 overcome by intensity-modulated radiation therapy (IMRT), offering superior target coverage and
13
14 lower risk to surrounding tissue (6). Chakraborty et al treated 8 patients with conformal RT, including
15
16 7 with IMRT, with a median age of 14 years (11). At last follow up 87.5% were free of disease
17
18 (median: 17 months), whilst one patient died a month after radiotherapy due to massive epistaxis.
19
20
21
22
23
24
25
26

27 There are few reports on the use of cytotoxic drugs for treatment of JNA. Goepfert et al described
28
29 tumor remission in five patients with recurrent disease using combinations of doxorubicin,
30
31 vincristine, dactinomycin and cyclophosphamide, none of which had further recurrence (12). Schick
32
33 et al reported a patient with advanced and unresectable disease who underwent palliative
34
35 treatment with adriamycin and decarbazine, which led to a partial response (RECIST) (13). Limited
36
37 evidence and lack of randomized control trials result in chemotherapy approaches that are not
38
39 uniform and remain experimental in nature.
40
41
42
43
44
45
46
47

48 The growth of JNA is highly influenced by hormonal levels, due to the presence of testosterone and
49
50 dihydrotestosterone receptors. Hwang et al provided immunocytochemical evidence for the
51
52 presence of androgen receptors (AR) on 75% of JNAs using antibodies to AR (4). The non-steroidal
53
54 androgen antagonist, flutamide, blocks androgen receptors without the side effects of estrogen
55
56 analogues. Gates et al conducted a pilot study of five male patients with Fisch stage I – III lesions
57
58
59
60
61
62
63
64
65

1 (Table I), treated pre-operatively with 500mg/day of flutamide for six weeks (14). CT showed tumor
2 volume reduction in four patients and increase in one, resulting in a mean volume reduction of 29%.
3
4 Flutamide was well tolerated and serum testosterone levels were normal 2 years post operatively,
5
6 although it is not clear whether the patients remained in remission. Labra et al investigated the
7
8 effect of flutamide on seven patients with advanced intracranial disease and a mean age of 15.6
9
10 years (Fisch stage IV; Table I) (15). 600mg/day of flutamide was administered for three weeks pre-
11
12 operatively resulting in a non-statistically significant mean volume reduction of 7.2%. The larger
13
14 tumor size (mean 202.45 cm³), stage or shorter course may have contributed to the ineffectiveness
15
16 of flutamide in this study. Thakar et al performed a phase II evaluation of activity and safety of
17
18 flutamide (16). Their study included 20 male patients with Fisch stage II – IV JNA (Table I) with a
19
20 mean age of 15.7 years. A six week course of 10mg/kg/day was chosen based on Gates et al's regime
21
22 and tumor volume was assessed by MRI (14). Pre-pubertal patients had a mean reduction of -2.3%
23
24 including two patients that had significant tumor progression. Conversely, post-pubertal patients
25
26 had a mean volume reduction of 16.5% (p=0.04). However, volume reduction was only partially
27
28 attributed to serum testosterone levels ($R^2 = 0.28$) and the study does not report data on event free
29
30 and overall survival. Three patients with tumor recurrence showed a reduction in JNA volume of 7%,
31
32 12% and 18%, suggesting flutamide may be a treatment option in post-excision residual or recurrent
33
34 intracranial and extracranial JNA. These pilot studies suggest that a six week course of flutamide
35
36 may have some activity in treating recurrent JNA, particularly in post-pubertal boys. Further
37
38 investigation into adjuvant or salvage flutamide treatment is warranted, as the current evidence on
39
40 flutamide efficacy is not entirely convincing.
41
42
43
44
45
46
47
48
49
50
51
52
53

54 The vascular endothelial growth factor (VEGF) pathway plays a key role in solid tumor angiogenesis.
55
56 Saylam et al found that 24 of 27 JNA samples were VEGF positive, including all cases of recurrence
57
58 tested (17). Bevacizumab is a humanized monoclonal antibody that inhibits VEGF-A and could be a
59
60
61
62
63
64
65

1 potential therapeutic option, although there are no reports of VEGF inhibitors being investigated as
2 treatment for JNA to date.
3

4
5
6
7
8 Schick et al found that estrogen receptor alpha mRNA is more significant in JNA cell lines than in the
9 stroma of nasal mucosa (18). The estrogen receptor antagonist tamoxifen was also demonstrated to
10 inhibit proliferation of cultured JNA mesenchymal cells. However, side-effects of tamoxifen limit its
11 clinical use for this indication. Selective estrogen antagonists are being developed, but other specific
12 molecular targets currently remain a more realistic option for experimental treatment of JNA.
13
14
15
16
17
18
19
20
21
22
23

24 Wendler et al demonstrated the greater anti-proliferative effects of glucocorticoids on 30 JNA tissue
25 samples compared to 20 nasal mucosa tissues in vitro (19). They also showed up-regulation of
26 glucocorticoid receptors in JNA tissue compared to nasal mucosa. Glucocorticoids are reported to
27 downregulate VEGF, reducing microvessel density and tumor volume (19). This is of particular
28 interest in JNA because of previously described overexpression of VEGF (17), making glucocorticoids
29 an intriguing but untested option for management of unresectable or recurrent JNA.
30
31
32
33
34
35
36
37
38
39
40
41
42

43 The mTOR (mammalian target of rapamycin) inhibitor sirolimus (rapamycin) and its analogues may
44 offer effective targeted treatment for JNA, due to its highly vascular nature. They are potent
45 inhibitors of serine/threonine kinase, which control cellular growth processes. Notably they appear
46 to have antiangiogenic activity and have led to partial response in a case series of six patients with
47 kaposiform hemangioendotheliomas (20).
48
49
50
51
52
53
54
55
56
57
58
59
60
61
62
63
64
65

1 Beta blockers are used in infantile hemangiomas to reduce the expression of VEGF and it has been
2 theorized that propranolol induces apoptosis due to involvement of β 1-adrenoreceptors in
3
4 angiogenesis (20). Both mTOR inhibitors and beta blockers are options for further research into JNA
5
6
7 treatment.
8
9
10

11 **Conclusion**

12
13
14
15
16 Managing recurrent and unresectable JNA remains a challenge. The absence of randomized control
17
18 trials for anti-neoplastic drugs and RT means the role of adjuvant therapy is not well established. The
19
20 greatest body of evidence surrounds radiation therapy or a six week course of flutamide, but both
21
22 are based on small cohorts. Dexamethasone is a possible therapeutic option due to its potential
23
24 impact on multiple pathways, but this is yet to be proven in a clinical setting. There is a biological
25
26 rationale for anti-angiogenic agents and trials on anti-endoglin monoclonal antibodies are on-going,
27
28 but VEGF-inhibitors such as bevacizumab have yet to be investigated. Should recurrence occur in the
29
30 patient described in this case, the evidence-base for effective treatment is limited, particularly as
31
32 being pre-pubertal reduces the potential benefit of flutamide. Radiotherapy is likely to remain the
33
34 next most rational course of therapy. It has been demonstrated to effectively reduce tumor volume
35
36 and is the best option for long term survival despite the potential side effects, until more targeted
37
38 therapeutic options are fully evaluated. JNA is a biologically rich tumor and there is a clear need for
39
40 clinical research to evaluate adjuvant treatments to improve the outcome for recurrent and
41
42 inoperable JNA.
43
44
45
46
47
48
49
50
51
52
53
54
55
56
57
58
59
60
61
62
63
64
65

Acknowledgements

The authors would like to thank Carl H. Snyderman C, Elizabeth C. Tyler-Kabara and Paul A. Gardner at the University Of Pittsburgh Medical Centre (UPMC) for their invaluable advice and surgical expertise in managing the case described.

References

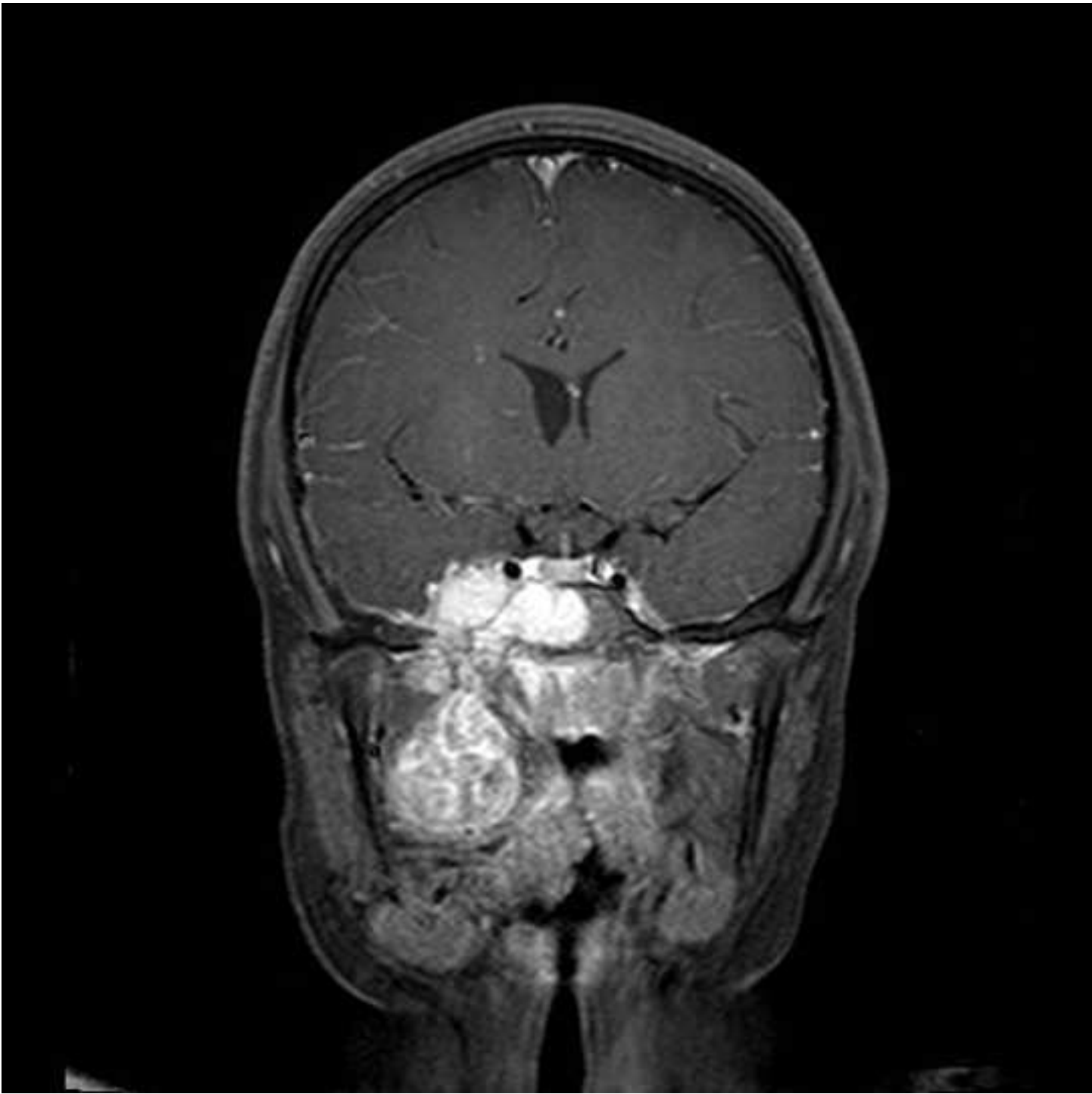
1. Lund VJ, Stammberger H, Nicolai P et al European Rhinologic Society Advisory Board on Endoscopic Techniques in the Management of Nose, Paranasal Sinus and Skull Base Tumours. European position paper on endoscopic management of tumours of the nose, paranasal sinuses and skull base. *Rhinol Suppl.* 2010 Jun 1;(22):1-143.
2. Nicolai P, Schreiber A, Bolzoni Villaret A. Juvenile angiofibroma: evolution of management. *Int J Pediatr.* 2012; 2012: 412545.
3. Schick B, Plinkert PK, Prescher A. [Aetiology of Angiofibromas: Reflection on their Specific Vascular Component]. *Laryngorhinootologie.* 2002 Apr;81(4):280-4.
4. Hwang HC, Mills SE, Patterson K, et al. Expression of androgen receptors in nasopharyngeal angiofibroma: an immunohistochemical study of 24 cases. *Mod Pathol.* 1998; 11: 1122–1126.
5. Wang JJ, Sun XC, Hu L, et al. Endoglin (CD105) expression on microvessel endothelial cells in juvenile nasopharyngeal angiofibroma: tissue microarray analysis and association with prognostic significance. *Head Neck.* 2013; 35(12): 1719-25.
6. Hodges JM, McDevitt AS, El-Sayed Ali AI, et al. Juvenile nasopharyngeal angiofibroma: current treatment modalities and future considerations. *Indian J Otolaryngol Head Neck Surg.* 2005; 62(3): 236-47.
7. Chen KT, Bauer FW. Sarcomatous transformation of nasopharyngeal angiofibroma. *Cancer.* 1982 Jan 15;49(2):369-71.
8. Makek MS, Andrews JC, Fisch U. Malignant transformation of a nasopharyngeal angiofibroma. *Laryngoscope.* 1989 Oct;99(10 Pt 1):1088-92.
9. McAfee WJ, Morris CG, Amdur RJ, et al. Definitive radiotherapy for juvenile nasopharyngeal angiofibroma. *Am J Clin Oncol.* 2006; 29(2): 168-70.
10. Lee JT, Chen P, Safa A, et al. The role of radiation in the treatment of advanced juvenile angiofibroma. *Laryngoscope.* 2002; 112: 1213-20.

- 1
2
3
4
5
6
7
8
9
10
11
12
13
14
15
16
17
18
19
20
21
22
23
24
25
26
27
28
29
30
31
32
33
34
35
36
37
38
39
40
41
42
43
44
45
46
47
48
49
50
51
52
53
54
55
56
57
58
59
60
61
62
63
64
65
11. Chakraborty S, Ghoshal S, Patil VM, et al. Conformal radiotherapy in the treatment of advanced juvenile nasopharyngeal angiofibroma with intracranial extension: an institutional experience. *Int J Radiat Oncol Biol Phys.* 2011; 80(5): 1398-404.
12. Goepfert H, Cangir A, Lee YY. Chemotherapy for aggressive juvenile nasopharyngeal angiofibroma. *Arch Otolaryngol.* 1985; 111(5): 285-9.
13. Schick B, Kahle G, Hässler R, et al. Chemotherapy of juvenile angiofibroma--an alternative? *HNO.* 1996; 44(3): 148-52.
14. Gates GA, Rice DH, Koopmann CF Jr, et al. Flutamide-induced regression of angiofibroma. *Laryngoscope.* 1992; 102(6):641-4.
15. Labra A, Chavolla-Magaña R, Lopez-Ugalde A, et al. Flutamide as a preoperative treatment in juvenile angiofibroma (JA) with intracranial invasion: report of 7 cases. *Otolaryngol Head Neck Surg.* 2004; 130(4): 466-9.
16. Thakar A, Gupta G, Bhalla AS, et al. Adjuvant therapy with flutamide for presurgical volume reduction in juvenile nasopharyngeal angiofibroma. *Head Neck.* 2011; 33(12): 1747-53.
17. Saylam G, Yücel OT, Sungur A, et al. Proliferation, angiogenesis and hormonal markers in juvenile nasopharyngeal angiofibroma. *Int J Pediatr Otorhinolaryngol.* 2006; 70(2): 227-34.
18. Schick B, Długaiczek J, Wendler O. Expression of sex hormone receptors in juvenile angiofibromas and antiproliferative effects of receptor modulators. *Head Neck.* 2014; 36(11): 1596-603
19. Wendler O, Długaiczek J, Birk S, et al. Anti-proliferative effect of glucocorticoids on mesenchymal cells in juvenile angiofibromas. *Head Neck.* 2012; 34(11): 1615-21.
20. Margolin JF, Soni HM, Pimpalwar S. Medical therapy for pediatric vascular anomalies. *Semin Plast Surg.* 2014 May;28(2):79-86.

Figures

Figure 1: Coronal MRI image showing an extensive JNA extending laterally into the pterygopalatine and masseter spaces and inferiorly into the infratemporal fossa. It extends into the right cavernous sinus and involves the right Meckel's cave.

Figure 2: Pathology micrographs of the JNA featured in the case: **2a)** Hematoxylin and eosin stain; **2b)** β -Catenin stain; **2c)** Vimentin stain.



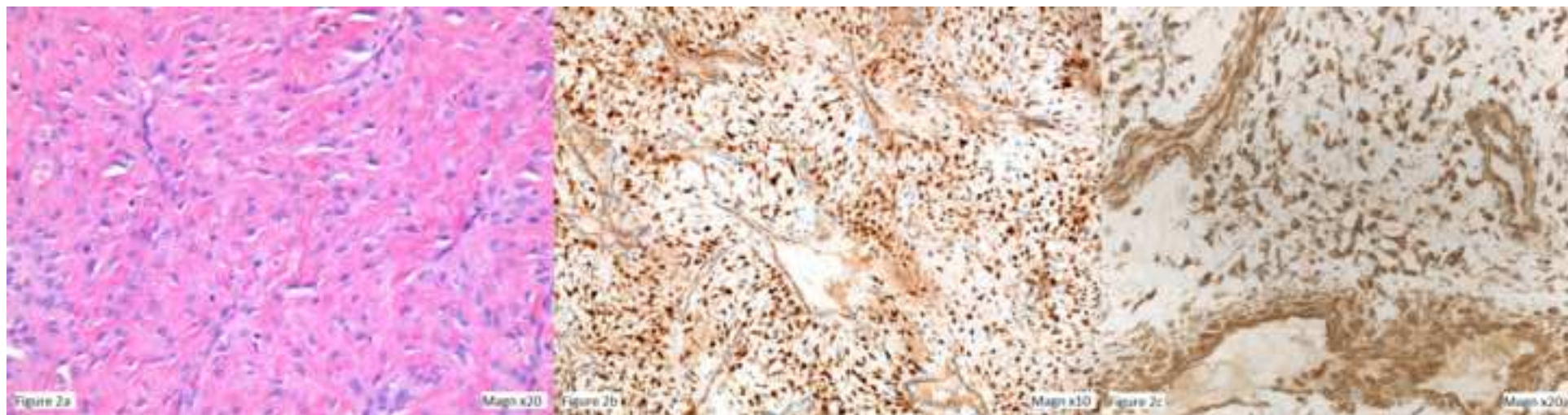


Table I: Fisch Classification of Juvenile Nasopharyngeal Angiofibroma

Stage	Characteristics
I	Limited to the nasopharynx and nasal cavity without bone destruction.
II	Invading the pterygomaxillary fossa and the maxillary, ethmoid and sphenoid sinus with bone destruction.
III	Invading the infratemporal fossa, orbit and parasellar region remaining lateral to the cavernous sinus.
IV	Massive invasion of cavernous sinus, the optic chiasmal region or pituitary fossa.

Table II: Summary of adjunctive treatment of JNA

Study [reference]	Patient number	Treatment	Outcome
Radiation Therapy			
McAfee et al (2006) [9]	22	30 – 36 Gy	Local control in 90% of patients, late complications in 32%
Lee et al (2002) [10]	27	30-55 Gy	Recurrence in 15% of patients, complications in 15%
Chakraborty et al (2011) [11]	7	Intensity modulated radiotherapy	88% of patients disease free at 17 months. 1 death from massive epistaxis.
Cytotoxic Drugs			
Goepfert et al (1985) [12]	5	Doxorubicin, vincristine, dactinomycin and cyclophosphamide	0% recurrence
Schick et al (1996) [13]	1	Adriamycin and decarbazine	Partial response (RECIST criteria)
Flutamide			
Gates et al (1992) [14]	5	500mg/day for 6 weeks pre-operatively	Mean volume reduction: 29%
Labra et al (2004) [15]	7	600mg/dag for 3 weeks pre-operatively	Mean volume reduction: 7.2%
Thakar et al (2011) [16]	20	10mg/kg/day for 6 weeks	Mean volume reduction: -2.3% in pre-pubertal, 16.5% in post-pubertal
Targeted therapies			
Saylam et al (2006) [17]	N/A – in vitro	89% of JNA samples VEGF positive	
Wendler et al (2012) [19]	N/A – in vitro	Glucocorticoids	Antiproliferative effects demonstrated

Adjunctive Treatment In Juvenile Nasopharyngeal Angiofibroma: How Should We Approach Recurrence?

Daniel W Scholfield BSc (Hons) MBChB¹, Marie-Anne Brundler MD FRCPATH², Ann-Louise McDermott
FDS RCS FRCS³, Francis Mussai MA (Oxon) BM BCh DPhil MRCPCH^{1,4}, Pamela Kearns MBChB BSc
(Hons) PhD FRCPCH^{1,4}

¹Paediatric Oncology Department, Birmingham Children's Hospital

²Department of Pathology, Birmingham Children's Hospital, Birmingham UK

³ENT Department, Birmingham Children's Hospital, Birmingham UK

⁴School of Cancer Sciences, University of Birmingham, UK

Disclosures:

The authors have no conflicts of interest or funding to disclose.

Correspondence:

Daniel Scholfield

Whipps Cross Hospital

London, UK

E11 1NR

Email: danwscholfield@doctors.org.uk

Telephone: +44(0) 7817 262259

Key words:

Juvenile Nasopharyngeal Angiofibroma

Radiotherapy

Flutamide

Dexamethasone

Abstract

1
2 A recent case of advanced, recurrent Juvenile Nasopharyngeal Angiofibroma (JNA) at our institution
3
4 has highlighted the limited evidence regarding adjunctive treatment. We present the case of a ten
5
6 year old boy who is the first to undergo multiple staged surgical resections alongside vincristine
7
8 treatment. We performed a review of the literature analyzing the roles of radiation therapy,
9
10 cytotoxic drugs and novel targeted agents in JNA relapse. Small cohort studies suggest radiotherapy
11
12 and flutamide are the most rational treatment options for residual and recurrent JNA. Our review
13
14 highlights the need for further research into the management of primary and recurrent JNA.
15
16
17
18
19
20
21
22

Introduction

23
24
25
26 Juvenile nasopharyngeal angiofibroma (JNA) is a benign, highly vascular and locally invasive lesion
27
28 that develops almost exclusively in the nasopharynx of peripubertal boys. JNA represents 0.5% of all
29
30 head and neck tumors, with an incidence of approximately 1:150,000. Large cohort studies report
31
32 median ages of 15 years (range 10-24 years) and 18.5 years (range 18-35 years) (1).
33
34
35
36
37
38
39

40 Histologically JNA is pseudocapsulated, characterized by an irregular vascular component embedded
41
42 in a fibrous stroma, densely populated by collagen and fibroblasts. Mitotic figures are rare and the
43
44 vessels are organized in clusters, without elastic fibers in their walls or a muscular lining in smaller
45
46 vessels (2). Electron microscopy and immunohistological studies demonstrating morphological
47
48 irregularities such as focal lack of pericytes, discontinuous vascular basal laminae and irregularity of
49
50 smooth muscle layers, suggest that JNA is not a tumor, but a vascular malformation (3). JNA
51
52 originates from the first branchial arch artery and usually regresses between embryological day 22
53
54 and 24 to form a venous plexus in the sphenopalatine foramen, the typical site of JNA origin.
55
56
57
58
59 Incomplete regression of the vascular plexus leaves it vulnerable to growth stimulation at the time of
60
61
62
63
64
65

1 adolescence to form JNA (3). Predominance in adolescent males suggests a hormonal influence on
2 growth, supported by the presence of androgen receptors on JNA cell membranes (4). **The male to**
3
4 **female ratio of patients in our review is 94:0.**
5
6
7

8
9
10 JNA is locally destructive, often extending intracranially into the paranasal sinuses and along the
11 skull base (5). Patients present with nasal obstruction, facial numbness, headaches and visual
12 changes (6). Nasal endoscopy typically reveals a large hypervascularized, lobulated mass extending
13 into the nasopharynx and diagnosis is confirmed with computed tomography (CT), which usually
14 reveals widening of the sphenopalatine foramen and extension into surrounding areas (5). Contrast
15 enhanced magnetic resonance imaging (MRI) shows further characteristic features - “flow voids”
16 caused by the highly vascular nature of JNA. MRI is superior to CT for diagnosis and surgical planning
17 due to greater sensitivity in distinguishing JNA from retained mucous or inflammation, eliminating
18 other benign or malignant tumors and assessing intracranial extent (1).
19
20
21
22
23
24
25
26
27
28
29
30
31
32
33
34
35

36 Surgery remains the mainstay of treatment, preceded by intravascular embolization to reduce intra-
37 operative bleeding (5). Adjunctive radiotherapy and chemotherapy are uncommon, but may be the
38 only option in inoperable recurrence. A recent case at our institution has highlighted the
39 exceptionally limited evidence regarding adjunctive treatment and questions how best to approach
40 recurrence.
41
42
43
44
45
46
47
48
49
50
51

52 **Case**

53
54
55 A ten year old boy presented to our institution with a two month history of deteriorating vision and
56 proptosis of his right eye. He complained of nasal obstruction and sleep disordered breathing for
57
58
59
60
61
62
63
64
65

1 more than a year and examination revealed a large right-sided nasal mass, paraesthesia of his right
2 cheek, nose and teeth, a right middle ear effusion and displacement of the right tonsil. CT and MRI
3 exhibited features consistent with Stage 4 JNA (Fisch classification, see Table I) (Figure 1). The
4 patient underwent pre-operative embolization of the right internal maxillary artery and other
5 significant bilateral tumor feeding vessels with Onyx (Ethylene vinyl alcohol copolymer), followed by
6 the first stage of endoscopic transnasal resection. An extended endoscopic approach utilizing a
7 Denker's maxilotomy was performed, although extensive blood loss limited the procedure.
8
9
10
11
12
13
14
15
16
17
18
19
20

21 Histology of the resected specimen showed a spindle cell lesion containing numerous angulated and
22 circular vascular spaces (Figure 2a). Cells showed relatively plump nuclei with small indistinct
23 nucleoli and the background stroma was mainly composed of dense fibrous tissue.
24
25
26

27 Immunohistochemistry revealed the cells to be strongly positive for β -catenin (Figure 2b) and
28 vimentin (Figure 2c). CD31 and CD34 highlighted angulated and larger ectatic vessels.
29
30
31
32
33
34
35

36 Post-operative MRI scan confirmed a substantial residual tumor encasing the right internal carotid
37 artery (ICA), with extension between the pterygoid muscles down to the angle of the mandible. The
38 case was discussed by pediatric oncology, radiation oncology and otolaryngology teams at a multi-
39 disciplinary meeting, with particular focus on the problem of excessive blood loss despite
40 embolization.
41
42
43
44
45
46
47
48
49
50
51

52 No standard therapeutic approach exists for recurrent and unresectable JNA. Based on a small case
53 series the patient was treated with 1.5mg/m² of vincristine weekly for four weeks, with the aim of
54 assessing chemosensitivity prior to surgery.
55
56
57
58
59
60
61
62
63
64
65

1
2
3 Restaging MRI six weeks post-operatively showed the tumor had failed to respond and had
4
5 increased in size to 75 x 75 x 45 mm (anteroposterior x craniocaudal x transverse long axis),
6
7 categorized by Response Evaluation Criteria in Solid Tumors (RECIST) as progressive disease. Further
8
9 endoscopic resection with embolization took place, again limited by blood loss and the risk of
10
11 deranged clotting from repeated transfusions. Extensive resection via an expanded endonasal
12
13 approach (EEA) was subsequently achieved. Four months post-surgery, MRI scans revealed a
14
15 residuum adjacent to the internal carotid artery. The child has since made an excellent recovery and
16
17 is currently under surveillance. MRI scans show no disease progression 28 months post-surgery via
18
19 EEA.
20
21
22
23
24
25
26
27

28
29 This case raises the question of management options in the event of further growth. A review of
30
31 possible therapeutic options is outlined below and summary provided in Table II.
32
33
34
35
36

37 **Discussion and Review of Adjunctive Treatment**

38
39
40 Biopsy is contra-indicated in JNA due to its highly vascularized nature. Accurate diagnosis and
41
42 differentiation from parameningeal tumors relies on MRI imaging, whilst CT provides bony land
43
44 marks for surgery. Characteristic signs on MRI include signal voids that represent major intra-
45
46 lesional vessels, “finger-like” projections of JNA extension into soft tissue and submucosal invasion
47
48 of the basisphenoid (1). Combining these characteristics leads to the diagnosis of JNA. There have
49
50 been no reports in the literature of these characteristic signs being present in other lesions.
51
52
53
54
55
56
57
58
59
60
61
62
63
64
65

1 JNA is principally a surgical lesion that should initially be discussed with the otolaryngology team
2 after recurrence. Transnasal endoscopic resections are most effective in combination with pre-
3
4 operative embolization. The surgical approach involves extensive exposure of the tumor, utilizing
5
6 resection of the posterior third of the nasal septum and the posterior wall of the maxillary sinus.
7
8 Accurate subperiosteal dissection and extensive drilling of any bone adhered to by JNA completes
9
10 the procedure (2). Endoscopic excision of smaller tumors is the gold standard for surgical resection
11
12 due to significantly reduced blood loss. The EEA approach utilizes the same principles in tackling
13
14 larger lesions that extend intracranially and into the skull base, the key advantage being that it
15
16 provides access to more deeply seated lesions (1).
17
18
19
20
21
22
23
24

25 Control of bleeding is the most significant intraoperative challenge, whilst skull base infiltration or
26
27 encasement of the ICA provide further surgical hazards that may result in inoperability. In contrast to
28
29 malignancies of the nasopharynx, such as rhabdomyosarcoma, a “piecemeal” resection is acceptable
30
31 and often preferable when approaching difficult anatomical locations (1). Endoscopic surgery is
32
33 contraindicated in residual tumors involving critical areas and it is in these cases where adjuvant
34
35 therapy needs to be discussed.
36
37
38
39
40
41
42
43

44 Radiation therapy (RT) for JNA is a contentious topic due to the potential for malignant
45
46 transformation to fibrosarcoma, although only two cases are reported in the literature, occurring 18
47
48 and 20 years after radiation (7, 8). Other long term sequelae include growth impairment,
49
50 encephalopathy and secondary malignancies (1, 9). Nevertheless, adjuvant radiotherapy is
51
52 recommended by some authors after incomplete resection (5). McAfee et al used RT to treat 22
53
54 adolescent males with high stage JNA, with a total dose range of 30 to 36 Gy (9). Ten were for
55
56 primary treatment and 12 for recurrence, resulting in local control in 90% of patients, with a median
57
58
59
60
61
62
63
64
65

1 follow up of 12.7 years. However, late complications occurred in 32% of patients, including transient
2 ischemic vascular stroke and basal cell carcinoma. Long term complications also occurred in a study
3 of 27 patients, where RT was used as primary treatment (30-55 Gy) for advanced JNA (10). The
4 recurrence rate was 15% at 2 to 5 years and 15% suffered complications. Nevertheless, the authors
5 concluded that the risk of surgical intervention in advanced JNA is greater than the risk of fatal RT
6 complications. The concern for damage to surrounding structures by conventional RT may be
7 overcome by intensity-modulated radiation therapy (IMRT), offering superior target coverage and
8 lower risk to surrounding tissue (6). Chakraborty et al treated 8 patients with conformal RT, including
9 7 with IMRT, with a median age of 14 years (11). At last follow up 87.5% were free of disease
10 (median: 17 months), whilst one patient died a month after radiotherapy due to massive epistaxis.
11
12
13
14
15
16
17
18
19
20
21
22
23
24
25
26

27 There are few reports on the use of cytotoxic drugs for treatment of JNA. Goepfert et al described
28 tumor remission in five patients with recurrent disease using combinations of doxorubicin,
29 vincristine, dactinomycin and cyclophosphamide, none of which had further recurrence (12). Schick
30 et al reported a patient with advanced and unresectable disease who underwent palliative
31 treatment with adriamycin and decarbazine, which led to a partial response (RECIST) (13). Limited
32 evidence and lack of randomized control trials result in chemotherapy approaches that are not
33 uniform and remain experimental in nature.
34
35
36
37
38
39
40
41
42
43
44
45
46
47

48 The growth of JNA is highly influenced by hormonal levels, due to the presence of testosterone and
49 dihydrotestosterone receptors. Hwang et al provided immunocytochemical evidence for the
50 presence of androgen receptors (AR) on 75% of JNAs using antibodies to AR (4). The non-steroidal
51 androgen antagonist, flutamide, blocks androgen receptors without the side effects of estrogen
52 analogues. Gates et al conducted a pilot study of five male patients with Fisch stage I – III lesions
53
54
55
56
57
58
59
60
61
62
63
64
65

1 (Table I), treated pre-operatively with 500mg/day of flutamide for six weeks (14). CT showed tumor
2 volume reduction in four patients and increase in one, resulting in a mean volume reduction of 29%.
3
4 Flutamide was well tolerated and serum testosterone levels were normal 2 years post operatively,
5
6 although it is not clear whether the patients remained in remission. Labra et al investigated the
7
8 effect of flutamide on seven patients with advanced intracranial disease and a mean age of 15.6
9
10 years (Fisch stage IV; Table I) (15). 600mg/day of flutamide was administered for three weeks pre-
11
12 operatively resulting in a non-statistically significant mean volume reduction of 7.2%. The larger
13
14 tumor size (mean 202.45 cm³), stage or shorter course may have contributed to the ineffectiveness
15
16 of flutamide in this study. Thakar et al performed a phase II evaluation of activity and safety of
17
18 flutamide (16). Their study included 20 male patients with Fisch stage II – IV JNA (Table I) with a
19
20 mean age of 15.7 years. A six week course of 10mg/kg/day was chosen based on Gates et al's regime
21
22 and tumor volume was assessed by MRI (14). Pre-pubertal patients had a mean reduction of -2.3%
23
24 including two patients that had significant tumor progression. Conversely, post-pubertal patients
25
26 had a mean volume reduction of 16.5% (p=0.04). However, volume reduction was only partially
27
28 attributed to serum testosterone levels (R² = 0.28) and the study does not report data on event free
29
30 and overall survival. Three patients with tumor recurrence showed a reduction in JNA volume of 7%,
31
32 12% and 18%, suggesting flutamide may be a treatment option in post-excision residual or recurrent
33
34 intracranial and extracranial JNA. These pilot studies suggest that a six week course of flutamide
35
36 may have some activity in treating recurrent JNA, particularly in post-pubertal boys. Further
37
38 investigation into adjuvant or salvage flutamide treatment is warranted, as the current evidence on
39
40 flutamide efficacy is not entirely convincing.
41
42
43
44
45
46
47
48
49
50
51
52
53

54 ~~Endoglin (CD105) is an accessory receptor for transforming growth factor beta (TGF-β). Its~~
55 ~~expression is up-regulated in actively proliferating endothelial cells and it is selectively expressed on~~
56 ~~vascular tumor tissue (3). Wang et al retrospectively examined endoglin expression on JNA in~~
57
58
59
60
61
62
63
64
65

1
2
3
4
5
6
7
8
9
10
11
12
13
14
15
16
17
18
19
20
21
22
23
24
25
26
27
28
29
30
31
32
33
34
35
36
37
38
39
40
41
42
43
44
45
46
47
48
49
50
51
52
53
54
55
56
57
58
59
60
61
62
63
64
65

seventy patients, with a median age of 17 years (5). Immunohistochemistry detected its expression on vascular endothelial cells (but not stromal cells) and revealed that the CD105-based microvessel density (MVD) correlated with JNA recurrence ($p=0.013$).

The vascular endothelial growth factor (VEGF) pathway plays a key role in solid tumor angiogenesis. Saylam et al found that 24 of 27 JNA samples were VEGF positive, including all cases of recurrence tested (17). Bevacizumab is a humanized monoclonal antibody that inhibits VEGF-A and could be a potential therapeutic option, although there are no reports of VEGF inhibitors being investigated as treatment for JNA to date.

Schick et al found that estrogen receptor alpha mRNA is more significant in JNA cell lines than in the stroma of nasal mucosa (18). The estrogen receptor antagonist tamoxifen was also demonstrated to inhibit proliferation of cultured JNA mesenchymal cells. However, side-effects of tamoxifen limit its clinical use for this indication. Selective estrogen antagonists are being developed, but other specific molecular targets currently remain a more realistic option for experimental treatment of JNA.

Wendler et al demonstrated the greater anti-proliferative effects of glucocorticoids on 30 JNA tissue samples compared to 20 nasal mucosa tissues in vitro (19). They also showed up-regulation of glucocorticoid receptors in JNA tissue compared to nasal mucosa. Glucocorticoids are reported to downregulate VEGF, reducing microvessel density and tumor volume (19). This is of particular interest in JNA because of previously described overexpression of VEGF (17), making glucocorticoids an intriguing but untested option for management of unresectable or recurrent JNA.

1 The mTOR (mammalian target of rapamycin) inhibitor sirolimus (rapamycin) and its analogues may
2 offer effective targeted treatment for JNA, due to its highly vascular nature. They are potent
3
4 inhibitors of serine/threonine kinase, which control cellular growth processes. Notably they appear
5
6 to have antiangiogenic activity and have led to partial response in a case series of six patients with
7
8 kaposiform hemangioendotheliomas (20).
9

10
11
12
13
14
15
16 Beta blockers are used in infantile hemangiomas to reduce the expression of VEGF and it has been
17
18 theorized that propranolol induces apoptosis due to involvement of β 1-adrenoreceptors in
19
20 angiogenesis (20). Both mTOR inhibitors and beta blockers are options for further research into JNA
21
22 treatment.
23
24
25
26
27
28

29 **Conclusion**

30
31
32
33 Managing recurrent and unresectable JNA remains a challenge. The absence of randomized control
34
35 trials for anti-neoplastic drugs and RT means the role of adjuvant therapy is not well established. The
36
37 greatest body of evidence surrounds radiation therapy or a six week course of flutamide, but both
38
39 are based on small cohorts. Dexamethasone is a possible therapeutic option due to its potential
40
41 impact on multiple pathways, but this is yet to be proven in a clinical setting. There is a biological
42
43 rationale for anti-angiogenic agents and trials on anti-endoglin monoclonal antibodies are on-going,
44
45 but VEGF-inhibitors such as bevacizumab have yet to be investigated. Should recurrence occur in the
46
47 patient described in this case, the evidence-base for effective treatment is limited, particularly as
48
49 being pre-pubertal reduces the potential benefit of flutamide. Radiotherapy is likely to remain the
50
51 next most rational course of therapy. It has been demonstrated to effectively reduce tumor volume
52
53 and is the best option for long term survival despite the potential side effects, until more targeted
54
55 therapeutic options are fully evaluated. JNA is a biologically rich tumor and there is a clear need for
56
57
58
59
60
61
62
63
64
65

1 clinical research to evaluate adjuvant treatments to improve the outcome for recurrent and
2 inoperable JNA.
3

4
5
6
7
8
9 **Acknowledgements**

10
11 The authors would like to thank Carl H. Snyderman C, Elizabeth C. Tyler-Kabara and Paul A. Gardner
12 at the University Of Pittsburgh Medical Centre (UPMC) for their invaluable advice and surgical
13 expertise in managing the case described.
14
15
16
17
18
19
20
21
22
23
24
25
26
27
28
29
30
31
32
33
34
35
36
37
38
39
40
41
42
43
44
45
46
47
48
49
50
51
52
53
54
55
56
57
58
59
60
61
62
63
64
65

References

1. Lund VJ, Stammberger H, Nicolai P et al European Rhinologic Society Advisory Board on Endoscopic Techniques in the Management of Nose, Paranasal Sinus and Skull Base Tumours. European position paper on endoscopic management of tumours of the nose, paranasal sinuses and skull base. *Rhinol Suppl.* 2010 Jun 1;(22):1-143.
2. Nicolai P, Schreiber A, Bolzoni Villaret A. Juvenile angiofibroma: evolution of management. *Int J Pediatr.* 2012; 2012: 412545.
3. Schick B, Plinkert PK, Prescher A. [Aetiology of Angiofibromas: Reflection on their Specific Vascular Component]. *Laryngorhinootologie.* 2002 Apr;81(4):280-4.
4. Hwang HC, Mills SE, Patterson K, et al. Expression of androgen receptors in nasopharyngeal angiofibroma: an immunohistochemical study of 24 cases. *Mod Pathol.* 1998; 11: 1122–1126.
5. Wang JJ, Sun XC, Hu L, et al. Endoglin (CD105) expression on microvessel endothelial cells in juvenile nasopharyngeal angiofibroma: tissue microarray analysis and association with prognostic significance. *Head Neck.* 2013; 35(12): 1719-25.
6. Hodges JM, McDevitt AS, El-Sayed Ali AI, et al. Juvenile nasopharyngeal angiofibroma: current treatment modalities and future considerations. *Indian J Otolaryngol Head Neck Surg.* 2005; 62(3): 236-47.
7. Chen KT, Bauer FW. Sarcomatous transformation of nasopharyngeal angiofibroma. *Cancer.* 1982 Jan 15;49(2):369-71.
8. Makek MS, Andrews JC, Fisch U. Malignant transformation of a nasopharyngeal angiofibroma. *Laryngoscope.* 1989 Oct;99(10 Pt 1):1088-92.
9. McAfee WJ, Morris CG, Amdur RJ, et al. Definitive radiotherapy for juvenile nasopharyngeal angiofibroma. *Am J Clin Oncol.* 2006; 29(2): 168-70.
10. Lee JT, Chen P, Safa A, et al. The role of radiation in the treatment of advanced juvenile angiofibroma. *Laryngoscope.* 2002; 112: 1213-20.

- 1
2
3
4
5
6
7
8
9
10
11
12
13
14
15
16
17
18
19
20
21
22
23
24
25
26
27
28
29
30
31
32
33
34
35
36
37
38
39
40
41
42
43
44
45
46
47
48
49
50
51
52
53
54
55
56
57
58
59
60
61
62
63
64
65
11. Chakraborty S, Ghoshal S, Patil VM, et al. Conformal radiotherapy in the treatment of advanced juvenile nasopharyngeal angiofibroma with intracranial extension: an institutional experience. *Int J Radiat Oncol Biol Phys.* 2011; 80(5): 1398-404.
12. Goepfert H, Cangir A, Lee YY. Chemotherapy for aggressive juvenile nasopharyngeal angiofibroma. *Arch Otolaryngol.* 1985; 111(5): 285-9.
13. Schick B, Kahle G, Hässler R, et al. Chemotherapy of juvenile angiofibroma--an alternative? *HNO.* 1996; 44(3): 148-52.
14. Gates GA, Rice DH, Koopmann CF Jr, et al. Flutamide-induced regression of angiofibroma. *Laryngoscope.* 1992; 102(6):641-4.
15. Labra A, Chavolla-Magaña R, Lopez-Ugalde A, et al. Flutamide as a preoperative treatment in juvenile angiofibroma (JA) with intracranial invasion: report of 7 cases. *Otolaryngol Head Neck Surg.* 2004; 130(4): 466-9.
16. Thakar A, Gupta G, Bhalla AS, et al. Adjuvant therapy with flutamide for presurgical volume reduction in juvenile nasopharyngeal angiofibroma. *Head Neck.* 2011; 33(12): 1747-53.
17. Saylam G, Yücel OT, Sungur A, et al. Proliferation, angiogenesis and hormonal markers in juvenile nasopharyngeal angiofibroma. *Int J Pediatr Otorhinolaryngol.* 2006; 70(2): 227-34.
18. Schick B, Długaiczek J, Wendler O. Expression of sex hormone receptors in juvenile angiofibromas and antiproliferative effects of receptor modulators. *Head Neck.* 2014; 36(11): 1596-603
19. Wendler O, Długaiczek J, Birk S, et al. Anti-proliferative effect of glucocorticoids on mesenchymal cells in juvenile angiofibromas. *Head Neck.* 2012; 34(11): 1615-21.
20. Margolin JF, Soni HM, Pimpalwar S. Medical therapy for pediatric vascular anomalies. *Semin Plast Surg.* 2014 May;28(2):79-86.

Figures

Figure 1: Coronal MRI image showing an extensive JNA extending laterally into the pterygopalatine and masseter spaces and inferiorly into the infratemporal fossa. It extends into the right cavernous sinus and involves the right Meckel's cave.

Figure 2: Pathology micrographs of the JNA featured in the case: **2a)** Hematoxylin and eosin stain; **2b)** β -Catenin stain; **2c)** Vimentin stain.