

# Routine postaccess-closure angiography to detect vascular complications following transfemoral TAVR

Savvoulidis, Panagiotis; Nadir, Adnan M; Mechery, Anthony; Lawton, Ewa; Khan, Kumail; Maqableh, Ghaith M; Raja, Waseem; Wong, Chun Wai; Radhakrishnan, Ashwin; Doshi, Sagar N

DOI:

[10.1002/ccd.30894](https://doi.org/10.1002/ccd.30894)

License:

Creative Commons: Attribution-NonCommercial (CC BY-NC)

*Document Version*

Publisher's PDF, also known as Version of record

*Citation for published version (Harvard):*

Savvoulidis, P, Nadir, AM, Mechery, A, Lawton, E, Khan, K, Maqableh, GM, Raja, W, Wong, CW, Radhakrishnan, A & Doshi, SN 2023, 'Routine postaccess-closure angiography to detect vascular complications following transfemoral TAVR', *Catheterization and Cardiovascular Interventions*.  
<https://doi.org/10.1002/ccd.30894>

[Link to publication on Research at Birmingham portal](#)

## General rights

Unless a licence is specified above, all rights (including copyright and moral rights) in this document are retained by the authors and/or the copyright holders. The express permission of the copyright holder must be obtained for any use of this material other than for purposes permitted by law.

- Users may freely distribute the URL that is used to identify this publication.
- Users may download and/or print one copy of the publication from the University of Birmingham research portal for the purpose of private study or non-commercial research.
- User may use extracts from the document in line with the concept of 'fair dealing' under the Copyright, Designs and Patents Act 1988 (?)
- Users may not further distribute the material nor use it for the purposes of commercial gain.

Where a licence is displayed above, please note the terms and conditions of the licence govern your use of this document.


When citing, please reference the published version.

## Take down policy

While the University of Birmingham exercises care and attention in making items available there are rare occasions when an item has been uploaded in error or has been deemed to be commercially or otherwise sensitive.

If you believe that this is the case for this document, please contact [UBIRA@lists.bham.ac.uk](mailto:UBIRA@lists.bham.ac.uk) providing details and we will remove access to the work immediately and investigate.

# Routine postaccess-closure angiography to detect vascular complications following transfemoral TAVR

Panagiotis Savvoulidis MD, PhD, FRCP, FESC<sup>1</sup>  | Adnan M. Nadir MD, FACC, MRCP<sup>1,2</sup> | Anthony Mechery MBBS, DM, MRCP<sup>1</sup> | Ewa Lawton RN<sup>1</sup> | Kumail Khan FCPS (Med), FCPS (Cardiology), FESC<sup>1</sup> | Ghaith M. Maqableh MD, MSc<sup>1,3</sup> | Waseem Raja MBBS, MRCP (UK)<sup>1</sup> | Chun Wai Wong MD<sup>1</sup> | Ashwin Radhakrishnan BMedSc, BM, MD<sup>1</sup> | Sagar N. Doshi MD, BSc (Hons), MBChB, FRCP<sup>1,2</sup>

<sup>1</sup>Department of Cardiology, Queen Elizabeth University Hospital, Birmingham, UK

<sup>2</sup>Institute for Cardiovascular Sciences, College of Medical & Dental Sciences, University of Birmingham, Birmingham, UK

<sup>3</sup>Cardiology Department, Faculty of Medicine, Al Balqa Applied University, Amman, Jordan

## Correspondence

Sagar N. Doshi, MD, BSc (Hons), MBChB, FRCP, Queen Elizabeth Hospital Birmingham, Edgbaston, Birmingham B15 2 TH, UK.  
Email: [Sagar.Doshi@uhb.nhs.uk](mailto:Sagar.Doshi@uhb.nhs.uk) and [S.N.Doshi@bham.ac.uk](mailto:S.N.Doshi@bham.ac.uk)

## Abstract

**Background:** Vascular complications following transfemoral TAVR are associated with increased morbidity and mortality. Measures that may mitigate this risk are important.

**Aim:** To evaluate the utility of routine, access-vessel angiography post sheath-removal in the detection and management of complications in patients undergoing transcatheter aortic valve replacement (TAVR).

**Methods:** This was a retrospective study of 512 consecutive patients who underwent transfemoral TAVR with routine post access-closure angiography from the radial artery. Rates of mild angiographically evident bleeding, bleeding requiring surgery/interventional-radiology, ischemia, 90-day access-site-related events, and major and minor vascular complications using Valve Academic Research Consortium 3 definitions were recorded.

**Results:** Of 512 patients, digital subtraction angiography (DSA) was undertaken via the radial artery in 467 patients (91%). In the remaining patients (9%) DSA was either not attempted, due to concerns regarding kidney disease and contrast volume, or failed due to anatomical factors (aortic tortuosity/calcification). Significant chronic kidney disease was present at baseline in 72.4% of this cohort (stages III–IV or dialysis). Ninety-four percent of cases underwent TAVR using a balloon-expandable platform. Mild iliofemoral extravasation was observed in 7.7% of the DSA cases. These cases were managed by manual compression with none requiring any vascular intervention subsequently. Valve Academic Research Consortium 3 major and minor access-site-related complications were observed in 0.4% and 12.2%, respectively. Access-site-related bleeding and ischemic events requiring interventional-radiology or vascular-surgery were observed in 0.9% and 1.7% of the DSA cases, respectively.

This is an open access article under the terms of the Creative Commons Attribution-NonCommercial License, which permits use, distribution and reproduction in any medium, provided the original work is properly cited and is not used for commercial purposes.

© 2023 The Authors. *Catheterization and Cardiovascular Interventions* published by Wiley Periodicals LLC.

No new renal replacement therapy was needed in any of the DSA cases. Discharge to 90-day access-related complications was 0.8%.

**Conclusions:** Routine post access-closure angiography is feasible via the radial artery in patients undergoing transfemoral TAVR and appears safe. It facilitates early identification of complications and mitigates risk by enabling prompt action to be taken. Larger studies are needed to confirm these findings.

#### KEYWORDS

access-site-related complications, TAVR, VARC-3, vascular complications

## 1 | INTRODUCTION

Transfemoral access is recognized as being the safest, most efficient route for transcatheter aortic valve replacement (TAVR). Since the first human TAVR in 2002, there has been tremendous and continuous refinement in equipment and the procedure.<sup>1</sup>

However, despite improvements of equipment, with lower profile sheaths and delivery devices and techniques, with routine use of micropuncture, ultrasound guidance, and percutaneous closure, vascular complications remain the most frequently encountered serious complication. Vascular access complications increase the hospital length-of-stay and both early and late morbidity and mortality.<sup>2</sup> Initial studies in high-risk patients reported major vascular complications up to 16% with more contemporary studies in lower risk cohorts reporting an incidence of 2% at 30 days.<sup>3,4</sup> The study aim was to evaluate the utility of routine, access vessel angiography post sheath-removal in the detection and management of complications in a contemporary cohort of patients undergoing minimalist transfemoral TAVR with routine use of radial access for aortography.

## 2 | METHODS

### 2.1 | Population and endpoints

We conducted a retrospective, single-center study in consecutive patients who underwent transfemoral percutaneous TAVR between January 2020 and May 2022 at Queen Elizabeth University Hospital, Birmingham. As this was a retrospective study informed consent was not required for study inclusion. All patients who underwent TAVR at our institution after January 2020 were identified via the UK NICOR TAVI registry. Patients who had TAVR via transfemoral access were isolated and demographic data and outcomes were extracted for the analysis.

Rates of mild angiographically evident bleeding, bleeding requiring surgery/interventional radiology, ischemia, discharge to 90-day access-site-related outcomes, access-site-related in-hospital mortality, new renal replacement therapy, major and minor vascular complications using Valve Academic Research Consortium 3 (VARC-3) definitions were recorded.

### 2.2 | Procedure details

TAVR procedures were undertaken in accordance with institutional, national, and international guidelines. The vascular access site was chosen after computerized tomography (CT) angiography in all patients. Evaluation of the vasculature and suitability for TAVR was made from multiplanar reconstruction of nongated CT scans of the aorta and peripheral vessels from the neck to the knees by experienced operators from the TAVR team.

Femoral arterial access for TAVR and femoral venous access were undertaken with micropuncture and ultrasound guidance. An angiogram was taken through the 4-F micropuncture sheath to confirm a satisfactory location and to record the arterial puncture site position. If the site of the puncture was satisfactory a 10-F femoral sheath was inserted after placing two Proglide/Prostyle suture-mediated devices (Abbott Laboratories) in a preclose fashion. A 14F-16F eSheath (Edwards Lifesciences) or a 14F-16F (Cook Medical) was then positioned in the abdominal aorta over an Amplatz super-stiff guidewire (Boston Scientific). For secondary arterial access, the radial artery (left or right) for a pigtail catheter was used as standard in all patients for aortography to guide valve implantation because of the better safety profile compared with femoral access.

All cases were undertaken with conscious sedation and transthoracic ultrasound monitoring.<sup>5</sup> In all cases valvuloplasty and transcatheter heart valve (THV) deployment were undertaken with rapid pacing via the 0.035" delivery catheter wire.<sup>6</sup> Activated clotting time (ACT) was maintained at 250–300 s throughout the procedure.

Following TAVR, anticoagulation was reversed with 50 mg intravenous protamine sulfate. The TAVR access site closure was standardized with routine use of two Perclose/Prostyle devices and a 6-F Angioseal (Terumo Interventional Systems). Following access site closure routine digital subtraction angiography (DSA) of the large bore femoral access site was undertaken with a 4-F 125 cm pigtail catheter or 4F 150 cm angled Glidecath hydrophilic catheter (Terumo Interventional Systems) from the radial artery access with 7 cc contrast.

In the case of satisfactory hemostasis and no complications, the case was considered completed. If there was evidence of mild extravasation, manual pressure was applied for 5 min and the access was reassessed with DSA or, in cases with very mild extravasation the

case was concluded at this stage. In cases of significant bleeding from the access site manual pressure was applied while awaiting review by the vascular surgical team and interventional radiologists. In these cases, bleeding was managed either by the implantation of covered stents or open surgery by the vascular surgical team. In cases of flow-limiting dissection additional intravenous unfractionated heparin was given to achieve an ACT of 200–250 s and opinions of the vascular surgical team and interventional radiologists was sought. Cases of non flow limiting dissection of the iliofemoral vasculature were closely monitored in the coronary care unit for signs of ischemia.

### 2.3 | Statistical analysis

Continuous data are presented as median and interquartile range and categorical data are presented as numbers (N) and frequencies (percentages). Statistical analyses were performed using R version 4.1.1 (R Foundation for Statistical Computing).

## 3 | RESULTS

A total of 512 consecutive patients who underwent TAVR at our institution via transfemoral access between January 2020 and May 2022 were identified. Demographics and baseline characteristics are presented in Table 1. Median age was 81 years, 56% were males, 27% were diabetic, 2.7% were receiving dialysis, 58% had chronic kidney disease (CKD) stage III, 12% CKD stage IV, 11% had prior cardiac surgery, and 11% had permanent pacemaker implants. Procedural characteristics are presented in Table 2. Preparatory balloon aortic valvuloplasty was performed in 18%. THV delivery success was 100%. 94% received an Edwards Sapien 3/Ultra (Edwards Lifesciences) and 6% a Medtronic Evolut Pro/Pro Plus (Medtronic).

The access-site-related events and discharge to 90-day outcomes are presented in Tables 3 and 4, respectively. DSA was performed in 91% of the cases. In the remaining 9% DSA was not undertaken either due to underlying severe CKD or was unsuccessful due to failure to advance catheters into the iliac vessels due to extreme tortuosity and/or calcification of the aorta. VARC-3 major access-related complication was 0.4% and VARC-3 minor access-related complication was 12.2%. Mild extravasation (Figure 1) was observed in 7.7% of cases and was managed successfully in all cases by 5 min manual compression with no patient requiring any form of vascular intervention to discharge or from discharge to 90 days.

Bleeding requiring vascular surgery/interventional radiology was observed in 0.9% of cases of whom 0.6% underwent stenting and 0.3% required open surgery. Ischemia was observed in 4.1%. Of these, 2.4% were managed successfully with anticoagulation alone. The remaining 1.7% required interventional radiology/vascular surgery. In the 1.5% requiring interventional radiology procedures (seven patients; four covered stents, three balloon angioplasty) for treatment of vascular access complications, all interventions were performed with fresh ipsilateral or contralateral femoral access. In

**TABLE 1** Demographics and baseline characteristics.

Variable	Cohort (N = 512)
Age	81 (75–86)
Logistic euroscore	10.2 (7–15.9)
Male sex	56 (286)
White origin	95 (485)
Diabetes mellitus	27 (137)
History of smoking	54 (279)
eGFR	46.0 (27.7–51.1)
Chronic kidney disease	
Stage III	58 (297)
Stage IV	11.7 (60)
Stage V	2.7 (14)
Dialysis	2.5 (13)
History of myocardial infarction	13 (68)
History of cerebrovascular accident/transient ischemic attack	17 (88)
History of cardiac surgery	11 (57)
Previous TAVR	0.3 (2)
History of PCI	13 (68)
Heart rhythm	
Sinus rhythm	63 (324)
Atrial fibrillation	59 (183)
Conduction disturbances	
1st degree atrioventricular block	16 (82)
RBBB	6 (33)
LBBB	13 (66)
Permanent pacemaker	11 (58)
CCS class	
0	88 (450)
I–II	10 (53)
III–IV	2 (9)
NYHA class	
I–II	18 (91)
III–IV	82 (421)
CSHA frailty score $\geq 3$	90 (459)
Left ventricular function	
>50%	75 (386)
30%–49%	16 (80)
<30%	9 (46)
Coronary artery disease	
None	78 (397)

(Continues)

**TABLE 1** (Continued)

Variable	Cohort (N = 512)
1-vessel disease	11 (55)
2-vessel disease	5 (24)
3-vessel disease	3 (13)
Left main stem disease	1.3 (7)
Mean pressure gradient, mmHg	42 (36–53)
Peak pressure gradient, mmHg	70 (61–86)
Aortic valve area, cm <sup>2</sup>	0.7 (0.59–0.85)
Mitral regurgitation	
None	41 (211)
Mild	47 (239)
Moderate	11.7 (60)
Severe	0.3 (2)

Note: Continuous variables expressed with median and 25th, 75th percentile. Categorical variables expressed with % and N.

Abbreviation: CCS, canadian cardiovascular society; LBBB, left bundle branch block; NYHA, New York Heart Association; PCI, percutaneous coronary intervention; RBBB, right bundle branch block; TAVR, transcatheter aortic valve replacement.

**TABLE 2** Procedural characteristics.

Variable	Cohort (N = 512)
Procedural time, min	65 (60–75)
Balloon aortic valvuloplasty	18 (91)
Transfemoral approach	100 (512)
TAVR platform	
Edwards Sapien 3/Sapien 3 ultra	94 (480)
Medtronic Evolut Pro/Pro+	6 (32)
TAVR delivery success	100 (512)
Valve malpositioning	
Ectopic deployment	0.2 (1)
TAVR valve balloon post-dilatation	19 (96)
Aortic regurgitation post-TAVR	
None/mild	99.2 (508)
Moderate/severe	0.8 (4)
Permanent pacemaker implantation	
Peri-procedural implantation	2 (11)
Postprocedural implantation	3 (16)
Cerebrovascular accident during index admission	0.8 (4)
Conversion to urgent/emergent sternotomy	0.6 (3)

Note: Continuous variables expressed with median and 25th, 75th percentile. Categorical variables expressed with % and N.

Abbreviation: TAVR, transcatheter aortic valve replacement.

**TABLE 3** Access-related events.

Variable	Cohort (N = 467)
VARC-3 major access-related complications	0.4 (2)
VARC-3 minor access-related complications	12.2 (57)
Final DSA performed	91 (467)
DSA performed via right radial artery	100 (467)
Bleeding complications	
Mild iliofemoral extravasation	7.7 (36)
Final DSA performed confirming no ongoing extravasation	6.2 (29)
Final DSA not performed due to very minor extravasation managed with manual pressure	1.5 (7)
Bleeding events requiring IR/surgery	0.9 (4)
Managed with covered stents implantation	0.6 (3)
Managed with surgery	0.2 (1)
Ischemic events	
Managed medically	2.4 (11)
Ischemic events requiring IR/surgery	1.7 (8)
Managed with balloon angioplasty	0.85 (4)
Managed with vascular surgery	0.85 (4)

Note: Continuous variables expressed with median and 25th,75th percentile. Categorical variables expressed with % and N.

Abbreviations: DSA, digital subtraction angiography; VARC-3, Valve Academic Research Consortium 3.

**TABLE 4** 3-month FU.

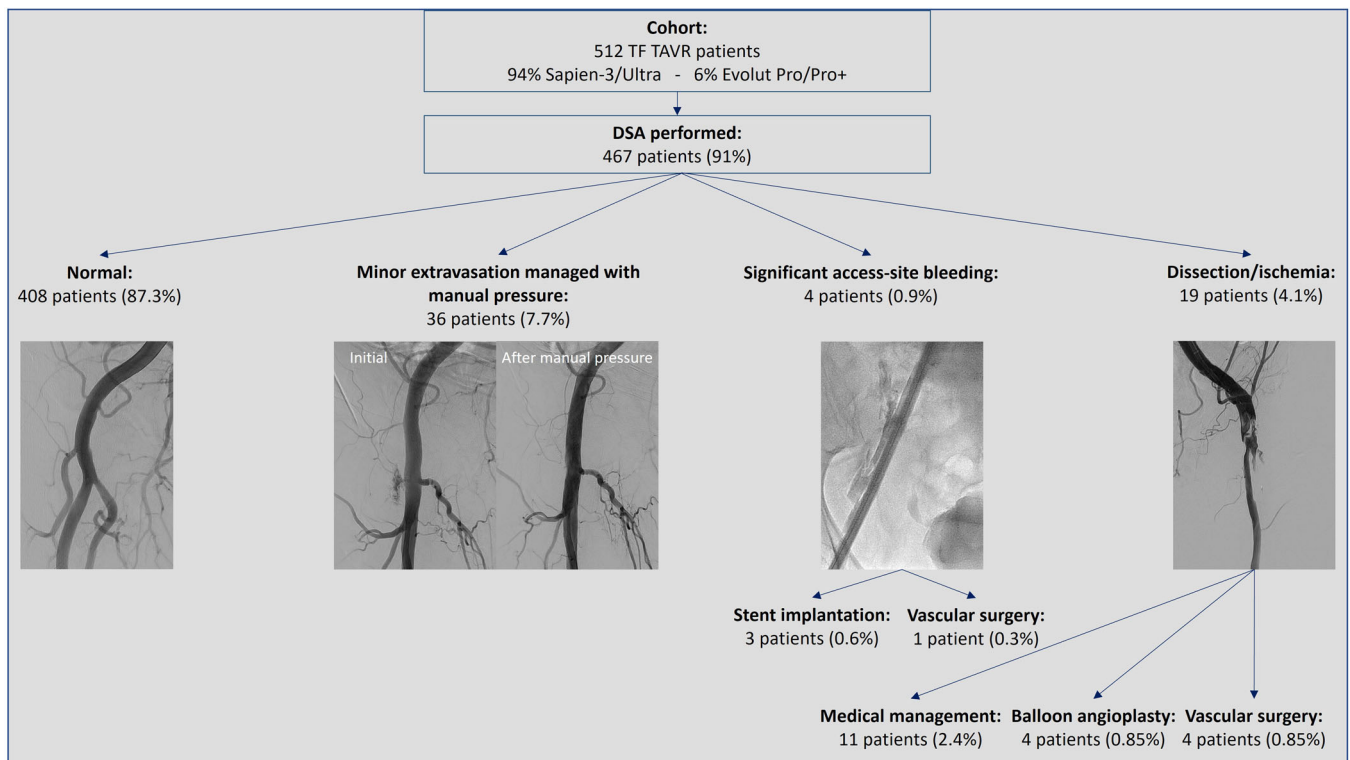
Variable	Cohort (N = 467)
Total in-hospital mortality	1.4 (7)
In-hospital mortality secondary to vascular complication	0.4 (2)
3-month mortality	1.8 (9)
New renal replacement therapy (discharge to 90 days)	0
Access-related outcomes (discharge to 90 days)	
Pseudo-aneurysm, nonactionable	0.4 (2)
Pseudo-aneurysm, treated with thrombin injection	0.2 (1)
Ischemic	0.2 (1)

Note: Continuous variables expressed with median and 25th,75th percentile. Categorical variables expressed with % and N.

Abbreviation: FU, follow up.

total, interventional radiology or vascular surgery intervention was needed in 2.6% of the cases.

In-hospital mortality due to access-site-related complications was 0.4%. No new renal replacement therapy was needed in any of



**FIGURE 1** Study flowchart and outcomes. DSA, digital subtraction angiography; TAVR, transcatheter aortic valve replacement. [Color figure can be viewed at [wileyonlinelibrary.com](https://onlinelibrary.wiley.com)]

the cases within 3 months post-TAVR. From discharge to 90 days there were two cases of pseudo-aneurysm (0.4%); one managed conservatively and the other with thrombin injection. One patient (0.2%) developed new, stable lower-limb ischemia and was managed conservatively. None of the 9% who did not undergo DSA suffered any vascular complications to discharge or from discharge to 90 days.

## 4 | DISCUSSION

The main findings of our study can be summarized as follows: (1) Final access site angiography following TAVR is feasible in over 90% via the radial artery, requires minimal contrast, and appears safe (no new renal replacement therapy in our study). (2) In-lab detection of access-site-related complications allows prompt detection and management that may avoid surgery/interventional radiology procedures. Mild bleeding occurred in 7.7% of patients which was successfully dealt with by manual compression in the lab and no further complication to 90 days. Of patients with ischemic complications (4.1%) over half (2.4%) were successfully managed conservatively with anticoagulation alone. Routine use of the radial artery for secondary arterial access (for the pigtail catheter) is an important step forward in simplifying TAVR procedures and has been associated with significant reductions in vascular complications and bleeding, when compared to femoral secondary arterial access, in large multicenter observational studies.<sup>7,8</sup> We have used the radial artery routinely for secondary arterial access

at our institution since 2018 in light of this evidence. However, we believe early detection of vascular complications and prompt reanticoagulation may have played a significant role in avoiding further invasive intervention in these patients. The low overall rate of VARC-3 major access-site-related complications (0.4%) and low need for vascular surgery/interventional radiology (2.6%) is, in part, attributable to routine post access-closure angiography in this study.

In total seven patients (1.5%) required interventional radiology procedures for access complications at the TAVR access site (covered stents four patients; angioplasty seven patients). These procedures were undertaken via new punctures to the ipsilateral or contralateral femoral artery. Although there is growing evidence supporting peripheral interventions via radial access to treat TAVR access complication<sup>9,10</sup> such interventions are limited by suitable experience, equipment range, and limitations on scope due to the larger size of peripheral vessels and the sheath size suitable for radial access.

Practice in TAVR procedures has substantially evolved since the first-in-man procedure in 2002. TAVR is supported by international guidelines across the entire risk spectrum from inoperable to low surgical risk patients.<sup>11,12</sup> Vascular access complications remain one of the most frequently encountered and serious complications. Rates of major vascular complications from initial experience with first iteration TAVR devices, bigger size sheaths, heavily co-morbid inoperable or high surgical risk patients is reported as high as 16% at 30 days.<sup>3</sup> However, with current TAVR iterations and smaller size sheaths, newer techniques, minimalist procedures, more comprehensive preprocedural planning,



decreasing surgical risk patients profile, and operators experience the rates of major vascular complications have dropped to as low as 2% at 1 month.<sup>4</sup> Nonetheless, although this rate is relatively low the clinical impact of such complications remains significant leading to substantial morbidity and mortality.

Major vascular complications are associated both with short and long-term risk for death with 1-year mortality as high as 39% (hazard ratio: 2.04, 95% confidence interval: 1.30–3.19, Log-rank  $p = 0.001$ ).<sup>2</sup> Additionally, 30-day major bleeding, transfusions, and renal failure requiring renal replacement therapy outcomes are significantly higher with major vascular complications. However, these observations were made in older cohort, high-risk and inoperable populations with severe aortic stenosis without the application and use of most modern techniques and TAVR iterations. Nonetheless, in more contemporary cohort of patients including all commercially available TAVR iterations, similar adverse outcomes were observed although the incidence of vascular complications has declined over time.<sup>13</sup> Vascular complications were associated with both 30-day (hazard ratio: 2.23, 95% confidence interval: 1.80–2.77) and 1-year (hazard ratio: 1.14, 95% confidence interval: 1.00–1.31) higher all-cause mortality and 1-year rehospitalizations (hazard ratio: 1.16, 95% confidence interval: 1.05–1.28).

The above data highlight the importance and the need for further improving and reducing the risk of vascular complications to lower the morbidity and mortality associated with these.

The routine undertaking of post closure DSA may mitigate the morbidity and mortality associated with vascular complications by enabling early identification and prompt interventions that may lower risk of harm to the patient.

#### 4.1 | Limitations

This study has several limitations. This is a single-center, retrospective study with all the inherent limitations this may carry. All procedures were undertaken by experienced operators in a high-volume center implementing minimalist TAVR techniques and hence the findings may not be generalizable.

## 5 | CONCLUSIONS

Postclosure angiography following transfemoral TAVR is feasible and appears safe in the vast majority of cases via radial access and enables prompt identification of access-related complications and early intervention that mitigate harm to the patient. Further studies should be undertaken to confirm these findings.

#### CONFLICT OF INTEREST STATEMENT

Professor Sagar N. Doshi is a proctor for Edwards Lifesciences and Boston Scientific and has received speaker fees from Boston Scientific, Medtronic, and Abiomed. The remaining authors declare no conflict of interest.

#### DATA AVAILABILITY STATEMENT

The data that support the findings of this study are available from the corresponding author upon reasonable request.

#### ORCID

Panagiotis Savvoulidis  <http://orcid.org/0000-0002-2266-8357>

#### REFERENCES

1. Cribier A, Eltchaninoff H, Bash A, et al. Percutaneous transcatheter implantation of an aortic valve prosthesis for calcific aortic stenosis: first human case description. *Circulation*. 2002;106(24):3006-3008.
2. Généreux P, Webb JG, Svensson LG, et al. Vascular complications after transcatheter aortic valve replacement. *J Am Coll Cardiol*. 2012;60(12):1043-1052.
3. Leon MB, Smith CR, Mack M, et al. Transcatheter aortic-valve implantation for aortic stenosis in patients who cannot undergo surgery. *N Engl J Med*. 2010;363(17):1597-1607.
4. Mack MJ, Leon MB, Thourani VH, et al. Transcatheter aortic-valve replacement with a balloon-expandable valve in low-risk patients. *N Engl J Med*. 2019;380(18):1695-1705.
5. Savvoulidis P, Moody WE, Steeds R, et al. A time-efficient protocol for transthoracic echocardiography during transfemoral transcatheter aortic valve implantation: early identification and effective management of intraprocedural complications. *Echo Res Pract*. 2022;9(1):3.
6. Savvoulidis P, Mechery A, Lawton E, et al. Comparison of left ventricular with right ventricular rapid pacing on tamponade during TAVI. *Int J Cardiol*. 2022;360:46-52.
7. Junquera L, Urena M, Latib A, et al. Comparison of transfemoral versus transradial secondary access in transcatheter aortic valve replacement. *Circ Cardiovasc Interv*. 2020;13(3):e008609.
8. Radhakrishnan SL, Ho KK. Transradial vs transfemoral secondary access outcomes in transcatheter aortic valve implantation: a systematic review and meta-analysis. *World J Cardiol*. 2020;12:571-583.
9. Fanaroff AC, Rao SV, Swaminathan RV. Radial access for peripheral interventions. *Interv Cardiol Clin*. 2020;9(1):53-61.
10. Mohapatra A, Saadeddin Z, Avgerinos ED, Al-Khoury GE, Hager ES, Eslami MH. Utilization and outcomes of radial artery access for lower extremity endovascular intervention. *Ann Vasc Surg*. 2021;77:94-100.
11. Vahanian A, Beyersdorf F, Praz F, et al. 2021 ESC/EACTS Guidelines for the management of valvular heart disease. *Eur Heart J*. 2022;43(7):561-632.
12. Otto CM, Nishimura RA, Bonow RO, et al. 2020 ACC/AHA Guideline for the management of patients with valvular heart disease. *J Am Coll Cardiol*. 2021;77(4):e25-e197.
13. Sherwood MW, Xiang K, Matsouaka R, et al. Incidence, temporal trends, and associated outcomes of vascular and bleeding complications in patients undergoing transfemoral transcatheter aortic valve replacement: insights from the Society of Thoracic Surgeons/American College of Cardiology Transcatheter Valve Therapies Registry. *Circ Cardiovasc Interv*. 2020;13(1):e008227.

**How to cite this article:** Savvoulidis P, Nadir AM, Mechery A, et al. Routine postaccess-closure angiography to detect vascular complications following transfemoral TAVR. *Catheter Cardiovasc Interv*. 2023;1-6. doi:10.1002/ccd.30894