

## Giant diverticulum- A rare complication of a common surgical condition

Cubas, Vanessa; Ward, Stephen T.; Dmitrewski, Jan

DOI:

[10.1002/ccr3.534](https://doi.org/10.1002/ccr3.534)

License:

Creative Commons: Attribution (CC BY)

*Document Version*

Publisher's PDF, also known as Version of record

*Citation for published version (Harvard):*

Cubas, V, Ward, ST & Dmitrewski, J 2016, 'Giant diverticulum- A rare complication of a common surgical condition', *Clinical Case Reports*, vol. 4, no. 5, pp. 531-532. <https://doi.org/10.1002/ccr3.534>

[Link to publication on Research at Birmingham portal](#)

### General rights

Unless a licence is specified above, all rights (including copyright and moral rights) in this document are retained by the authors and/or the copyright holders. The express permission of the copyright holder must be obtained for any use of this material other than for purposes permitted by law.

- Users may freely distribute the URL that is used to identify this publication.
- Users may download and/or print one copy of the publication from the University of Birmingham research portal for the purpose of private study or non-commercial research.
- User may use extracts from the document in line with the concept of 'fair dealing' under the Copyright, Designs and Patents Act 1988 (?)
- Users may not further distribute the material nor use it for the purposes of commercial gain.

Where a licence is displayed above, please note the terms and conditions of the licence govern your use of this document.

When citing, please reference the published version.

### Take down policy

While the University of Birmingham exercises care and attention in making items available there are rare occasions when an item has been uploaded in error or has been deemed to be commercially or otherwise sensitive.

If you believe that this is the case for this document, please contact [UBIRA@lists.bham.ac.uk](mailto:UBIRA@lists.bham.ac.uk) providing details and we will remove access to the work immediately and investigate.

## CLINICAL IMAGE

### Giant diverticulum- A rare complication of a common surgical condition

Vanessa Cubas<sup>1</sup>, Stephen T. Ward<sup>2</sup> & Jan Dmitrewski<sup>1</sup>

<sup>1</sup>Queen Elizabeth Hospital, Mindelsohn Way, Birmingham, B15 2TH, UK

<sup>2</sup>National Institute for Health Research (NIHR) Birmingham Liver Biomedical Research Unit (BRU), University of Birmingham, Vincent Drive, Birmingham, B15 2TT, UK

#### Correspondence

Vanessa Cubas, Queen Elizabeth Hospital, Mindelsohn Way, Birmingham, B15 2TH.  
Tel: 07729456671;  
Email: vanessacubas@nhs.net

#### Funding Information

This article has been funded by MRC (Medical Research Council).

Received: 11 August 2015; Revised: 5 November 2015; Accepted: 11 February 2016

*Clinical Case Reports* 2016; 4(5): 531–532

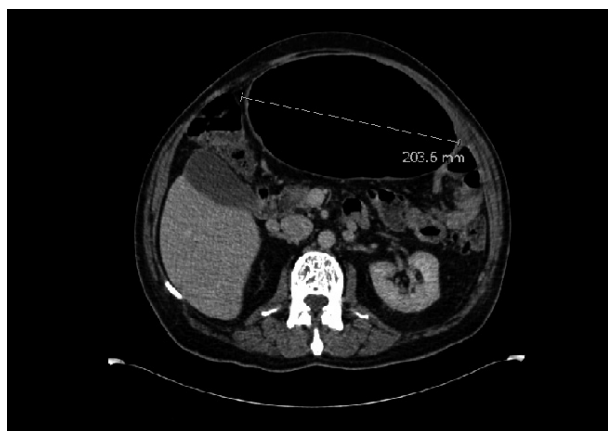doi: 10.1002/ccr3.534

## Introduction

### What is this condition?

#### Giant colonic diverticulum

A 65-year-old gentleman presented with abdominal distension and pain. CT confirmed a 20 cm sigmoid diver-



**Figure 1.** CT showing a 20.3 cm sigmoid mass in keeping with giant diverticulum.

#### Key Clinical Message

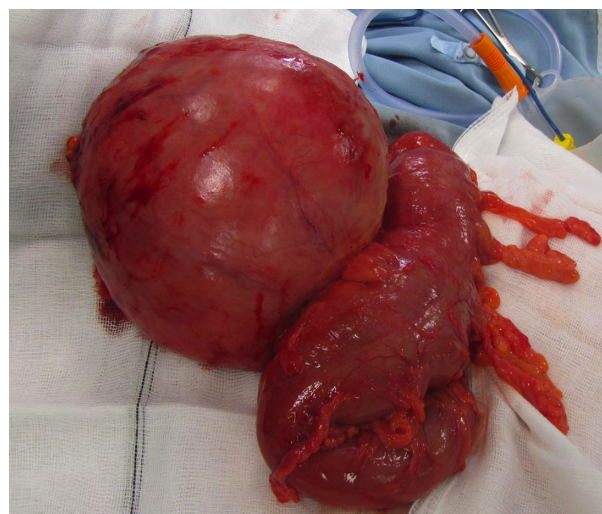
A gentleman presented with abdominal distension and pain. CT confirmed a 20 cm sigmoid diverticulum. A giant diverticulum, typified by diverticula greater than 4 cm, often requires colonic resection. Fewer than 200 cases have been reported, most measuring 7–15 cm. I present a rare complication of a common surgical condition with images.

#### Keywords

Diverticular disease, general surgery, giant diverticulum, sigmoid diverticulum.

ticulum (Fig. 1). Although he was clinically well a sigmoidectomy was performed due to the risk of perforation (Fig. 2). The patient was discharged 3 days later.

Giant diverticulum, typified by diverticula greater than 4 cm, is a rare manifestation of diverticular disease of the colon. It affects the sigmoid in 90% of cases [1]. Since it



**Figure 2.** Specimen following sigmoidectomy.

was first described by Hughes and Green in 1953, there have been fewer than 200 cases reported with most measuring between 7 and 15 cm. Although etiology is not clearly understood, it is believed that a one-way valve is created at the communication between the colon and the sac leading to air entrapment and a gradual distension of the sac [2]. Treatment usually entails surgery: colonic resection with a primary anastomosis.

### **Conflict of Interest**

None declared.

### **References**

1. Grover, H., S. Nair, and H. Herten. 1998. Giant true diverticulum of sigmoid colon. *Am. J. Gastroenterol.* 93:2267–2268.
2. Naber, A., A. M. Sliutz, and H. Freitas. 1995. Giant diverticulum of the sigmoid colon. *Int. J. Colorectal Dis.* 10:169–172.