

Assessment of atrial fibrosis for the rhythm control of atrial fibrillation

Begg, Gordon A.; Holden, Arun V.; Lip, Gregory Y.h.; Plein, Sven; Tayebjee, Muzahir H.

DOI:

[10.1016/j.ijcard.2016.06.144](https://doi.org/10.1016/j.ijcard.2016.06.144)

License:

Creative Commons: Attribution-NonCommercial-NoDerivs (CC BY-NC-ND)

Document Version

Peer reviewed version

Citation for published version (Harvard):

Begg, GA, Holden, AV, Lip, GYH, Plein, S & Tayebjee, MH 2016, 'Assessment of atrial fibrosis for the rhythm control of atrial fibrillation', *International Journal of Cardiology*, vol. 220, pp. 155-161.

<https://doi.org/10.1016/j.ijcard.2016.06.144>

[Link to publication on Research at Birmingham portal](#)

General rights

Unless a licence is specified above, all rights (including copyright and moral rights) in this document are retained by the authors and/or the copyright holders. The express permission of the copyright holder must be obtained for any use of this material other than for purposes permitted by law.

- Users may freely distribute the URL that is used to identify this publication.
- Users may download and/or print one copy of the publication from the University of Birmingham research portal for the purpose of private study or non-commercial research.
- User may use extracts from the document in line with the concept of 'fair dealing' under the Copyright, Designs and Patents Act 1988 (?)
- Users may not further distribute the material nor use it for the purposes of commercial gain.

Where a licence is displayed above, please note the terms and conditions of the licence govern your use of this document.

When citing, please reference the published version.

Take down policy

While the University of Birmingham exercises care and attention in making items available there are rare occasions when an item has been uploaded in error or has been deemed to be commercially or otherwise sensitive.

If you believe that this is the case for this document, please contact UBIRA@lists.bham.ac.uk providing details and we will remove access to the work immediately and investigate.

Accepted Manuscript

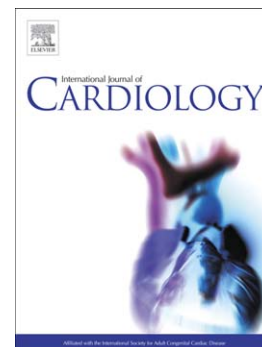
Assessment of Atrial Fibrosis for the Rhythm Control of Atrial Fibrillation

Gordon A. Begg, Arun V. Holden, Gregory Y.H. Lip, Sven Plein, Muzahir H. Tayebjee

PII: S0167-5273(16)31154-8
DOI: doi: [10.1016/j.ijcard.2016.06.144](https://doi.org/10.1016/j.ijcard.2016.06.144)
Reference: IJCA 22772

To appear in: *International Journal of Cardiology*

Received date: 22 March 2016
Revised date: 11 June 2016
Accepted date: 24 June 2016



Please cite this article as: Begg Gordon A., Holden Arun V., Lip Gregory Y.H., Plein Sven, Tayebjee Muzahir H., Assessment of Atrial Fibrosis for the Rhythm Control of Atrial Fibrillation, *International Journal of Cardiology* (2016), doi: [10.1016/j.ijcard.2016.06.144](https://doi.org/10.1016/j.ijcard.2016.06.144)

This is a PDF file of an unedited manuscript that has been accepted for publication. As a service to our customers we are providing this early version of the manuscript. The manuscript will undergo copyediting, typesetting, and review of the resulting proof before it is published in its final form. Please note that during the production process errors may be discovered which could affect the content, and all legal disclaimers that apply to the journal pertain.

Assessment of Atrial Fibrosis for the Rhythm Control of Atrial Fibrillation

Gordon A. Begg MBChB^{1,2} Arun V. Holden PhD² Gregory Y. H. Lip MD³ Sven Plein
MD PhD² Muzahir H. Tayebjee MD¹

¹Leeds General Infirmary, UK

²University of Leeds, UK

³University of Birmingham, UK

Address for Correspondence:

Dr. Gordon Begg, Ward X39 Offices, Leeds General Infirmary, Great George St,
Leeds, UK, LS1 3EX Email gordon.begg@nhs.net Tel: +447969138882

All authors take responsibility for all aspects of the reliability and freedom from bias of the data presented and their discussed interpretation.

Dr. Begg declares research fellowship funding from St. Jude Medical, St. Paul, MN.

Prof. Lip has served as a consultant for Bayer, Astellas, Merck, Sanofi, Bristol-

Myers Squibb/Pfizer, Biotronik, Medtronic, Portola, Boehringer Ingelheim,

Microlife, and Daiichi-Sankyo; and has been on the speakers bureau for Bayer,

Bristol-Myers Squibb/Pfizer, Medtronic, Boehringer Ingelheim, Microlife, and

Daiichi-Sankyo. The other authors report no relationships that could be construed as a

conflict of interest

Keywords: Atrial fibrillation, fibrosis, catheter ablation, cardioversion

Abstract

Rhythm control of atrial fibrillation (AF) remains challenging, with modest long term success rates. Atrial fibrosis has been associated with AF, but the clinical utility of assessment of this fibrosis has yet to be fully elucidated. In this paper we review the current state of understanding of the pathophysiology of atrial fibrosis in AF, and its impact upon the instigation and propagation of the arrhythmia. Fibrosis causes an increase in volume of dysfunctional extracellular matrix, and is associated with cellular alterations such as hypertrophy, apoptosis and membrane dysfunction within the atrial myocardium. In turn, these cause pathological alterations to atrial conduction, such as increased anisotropy, conduction block and re-entry, which can lead to AF. We review current methods of assessing atrial fibrosis and their impact upon the prediction of success of interventional rhythm control strategies such as ablation and cardioversion. We focus particularly on circulating biomarkers of fibrosis and scar formation; their role in the fibrotic process, and their value in the prediction of rhythm control success. We also review imaging and invasive electrocardiographic mapping techniques that may identify fibrosis, and again assess their potential predictive value. In this area there exist many unanswered questions, but further work will help to refine techniques to reliably identify and treat those patients who are most likely to benefit from rhythm control treatment strategies.

Introduction

Reliable prediction of treatment success for a rhythm control strategy for atrial fibrillation (AF) is highly desirable, to minimise unnecessary exposure to procedural risk and improve outcomes. Clinical factors favouring rhythm control strategies such as ablation include younger age, shorter duration of AF, paroxysmal AF, a structurally normal heart, and little comorbidity. Inflammatory disorders, valvular disease, left atrial dilatation, cardiomyopathy, and obesity are all considered clinical predictors of AF recurrence in individual trials, although a meta-analysis found no definitive clinical predictors of recurrent arrhythmia[1].

Circulating biomarkers may serve as surrogate indicators for advanced atrial pathology that may reduce the likelihood achieving rhythm control. If such markers could be identified and used in conjunction with clinical and imaging criteria, patient selection could be improved, leading to improved success rates from rhythm control.

Left atrial fibrosis has been associated with AF, and shown to be a poor prognostic marker for maintenance of sinus rhythm. Circulating markers of fibrosis may therefore be used as markers of left atrial remodelling.

This review focuses on the pathophysiology of atrial fibrosis, the use of serological, electrophysiological, and imaging methods to identify this fibrosis,

and the ability of such methods to predict or improve the success of rhythm control treatment of AF.

Selection criteria

We searched *Medline* (up to November 2015) using the terms “atrial fibrillation” and “fibrosis”. The abstracts were screened and full articles relevant to the review were selected. In total, 87 articles were selected for inclusion.

The extracellular matrix, collagen turnover, and fibrosis

Cardiac extra-cellular matrix (ECM) consists predominantly of type I (80%) and type III collagen and plays an important role in maintaining tissue architecture.[2] Furthermore, through interaction with fibroblasts and cardiomyocytes, involving TGF- β and angiotensin II paracrine signalling, the ECM has an important role in the detection of myocardial stretch.[3] Normal ECM is also important for intercellular signalling as well as electrical conduction.

Procollagen is synthesised in the fibroblast endoplasmic reticulum and then converted to collagen in the extracellular space by cleavage of the amino and carboxyl terminal groups.[4] The ECM is in a constant state of flux. A number of mechanisms regulate collagen turnover (*figure 1*), and involve transforming growth factor β (TGF- β), angiotensin II, platelet-derived growth factor, insulin-

like growth factor-1, growth hormone, and endothelins 1 and 3.[3, 5-8] . Matrix metalloproteinases (MMPs) are primarily responsible for collagen degradation and IL-1, prostaglandin, tumour necrosis factor α (TNF- α), and brain natriuretic peptide (BNP) up regulate MMP production.[8-10] Tissue inhibitors of MMPs (TIMPs) are the primary inhibitors of MMPs. MMPs 1, 2, 7, 8, 9, 10, and 13 have major roles in degrading type I and III collagen.

In AF, inflammatory changes in the ECM result in fibrosis.[11] Left atrial biopsy samples in patients with AF undergoing cardiac surgery have higher levels of collagen compared controls without AF with increased collagen crosslinking. [12, 13] In addition, fibroblast and lymphomononuclear cells proliferate and infiltrate atrial tissue. Fibroblasts differentiate into activated myofibroblasts and secrete paracrine factors and extracellular membrane proteins.[14, 15] This has been shown to cause cardiomyocyte de-differentiation into embryonic precursor cells.[16]_ Cardiomyocyte structure and function across the atrial myocardium become heterogenous, with varying levels of hypertrophy, necrosis, apoptosis and proliferation. This heterogeneity, in animal models, provides a substrate for AF initiation and perpetuation by interrupting cellular conduction and signalling.

Recent evidence suggests that epicardial adipose tissue may play a major role in cardiac inflammation and fibrosis potentially explaining why obesity is a risk factor for AF (although it is important to note that epicardial fat does not necessarily correlate with BMI).[17] Definitions of epicardial adipose tissue vary (many studies include fat in the pericardial space), but the largest such study in humans – involving the Framingham cohort – found a strong relationship

between pericardial fat (measured by CT) and AF.[18] Other studies have associated pericardial/epicardial fat with recurrent AF after ablation.[19, 20] Adipose tissue is known to stimulate the production of proinflammatory TNF- α , IL-6, TGF- β and MMPs. Thus, a paracrine effect on atrial myocardium, resulting in inflammation and fibrosis, has been postulated as a mechanism for the generation of AF substrate, as well as the direct effects of adipose infiltration into the myocardium.[21] Clinical assessment of these processes could help determine left atrial health and may serve as useful prognostic markers.

Fibrosis as a therapeutic target – is there any benefit?

Reducing left atrial fibrosis could have important clinical implications. A number of animal studies have shown the adverse effects of left atrial fibrosis. Li et al showed that angiotensin II signalling and atrial fibrosis were increased by ventricular tachypacing but this could be attenuated with enalapril.[22] In a rabbit model of heart failure, inhibition of angiotensin II with pioglitazone and candesartan reduced atrial fibrosis, conduction delay and levels of TGF- β 1 and TNF- α . [23] Clinical studies have shown similar promise. The TRACE study reported a reduction in AF incidence in patients with LV impairment treated with trandolopril after myocardial infarction – reduction in angiotensin signalling perhaps leading to a reduction in atrial fibrosis.[24] Furthermore, Vermes et al. showed that enalapril could prevent AF in heart failure patients.[25] Treatment with irbesartan in addition to amiodarone after electrical cardioversion appears to prevent AF recurrence in the absence of heart failure.[26] A potential anti-fibrotic role of ACE inhibition was supported in a study by Boldt et al. who showed a reduction collagen deposition in ACEI -

treated patients .[27] However, in meta analysis and in studies which used AF as a pre-determined endpoint, evidence was less convincing - particularly in patients without heart failure - that inhibition of the renin – angiotensin system prevents AF.[28, 29] The clinical utility of ACE inhibition for AF remains debatable.

Statins may exert anti-inflammatory, anti-oxidant and endothelium – stabilising effects that could reduce formation of fibrotic tissue. In animal histological experiments, statins have shown beneficial effects on atrial remodelling, and a reduction in fibrosis, likely as a result of reduced inflammation.[30, 31]

Subsequent trials in humans have been mixed, and the largest meta-analysis revealed no benefit of statins for primary or secondary prevention of AF.

Similarly, corticosteroids, which are anti-inflammatory, have not shown clinical benefit.

Predicting the success of treatment with circulating markers of fibrosis

There is a dearth of data on the role of circulating markers of fibrosis and maintenance of sinus rhythm in patients with AF(*table 1*). Neither atrial nor ventricular fibrosis is specific to AF and a specific of cardiac fibrosis has been identified. Two studies have attempted to correlate intracardiac marker levels with peripheral levels.[32, 33] In these studies, blood was obtained via catheterization of the left atrium and coronary sinus, but there were no

differences in circulating marker were found. Clinical studies have understandably excluded a large number of “real world” patients with AF because of confounding comorbidities. Positive associations between circulating fibrotic markers and rhythm outcome have only been found in small trials and subgroups of larger ones. As a result, odds or hazard ratio confidence interval lower limits are often close to 1. So far it seems that only markers of collagen types I and III turnover, e.g. PIIINP and C1P have shown promise. Conclusions about such biomarkers should be drawn very cautiously, however. As can be seen in the studies represented in *table 1*, the patient populations are heterogenous, particularly in terms of the character of AF. Duration, number of episodes, and previous treatment of AF are either poorly reported or not at all. The conventional AF classification (paroxysmal, persistent, permanent etc.) may not be sufficiently discriminative to describe the spectrum of pathology in AF patients – thus allowing for significant heterogeneity across study populations. It is perhaps unsurprising, therefore, that results frequently conflict.

Conduction in the fibrotic atrium

The mechanisms by which fibrosis may cause arrhythmia are not yet fully described, and are thought to be diverse (*Figure 2*).

Extracellular changes

The architecture of fibrotic myocardial tissue is heterogeneous, and this has a variable impact on intercellular conduction.[34, 35] In particular ‘interstitial’ and ‘patchy’ fibrosis, characterised by the presence of long strands of collagenous

material forming insulating septa between bundles of cardiomyocytes (perimysial fibrosis) as well as increasing the physical distance between cells (endomysial fibrosis).[36] Such extracellular structural alterations appear to be progressive and associated with the duration of AF.[37] In a persistent AF goat model, this pattern has been shown to increase electrical anisotropy.[38] Furthermore, optical mapping of human left atrial appendages in patients with AF have corroborates the findings of slower conduction, and structural and functional block, which are arrhythmogenic.[39, 40]

Cellular changes

Cardiomyocytes change structurally and physiologically, in effect entering into a hibernating state and displaying features usually associated with their embryological state.[41] As a result, contractility and excitability are reduced.[16] In addition, fibroblasts proliferate and differentiate into myofibroblasts.[42]

This is important as fibroblasts have modulating effects on conduction in cardiomyocytes, e.g. in response to mechanical stretch.[43]. Studies in rats have demonstrated how myofibroblasts can cause slow conduction.[44] The resting membrane potential in fibroblasts is less depolarised than cardiomyocytes, allowing them to act as a current 'sink', increasing the cardiomyocyte refractory period.[45] Depolarization of fibroblasts appears to stimulate them to increase production of ECM.[45]

The presence of these abnormal cell types is associated with abnormal conduction. [38, 46-48] For example, conduction velocity appears to be decreased by mechanical coupling and paracrine mediation between cardiomyocytes and fibroblasts. ⁵³[48] TGF-B1, angiotensin II, VEGF, TNF-A, endothelin-1 have been postulated as paracrine mediators.[49]

Normal functional communication between myocardial cells is achieved, in part, via gap junctions, expressed by fibroblasts, myofibroblasts, and cardiomyocytes.[50, 51]. Gap junctions are identified experimentally by labelling of their structural proteins, connexins (Cx). In animals, lower levels of Cx 40 seen in AF are thought to be a marker of abnormal gap junction function.[52] In human AF, connexin expression becomes heterogeneous and is increased along lateral borders of cardiomyocytes. This finding is supported by electron microscopy, and implies abnormal intercellular communication at sites outwith the intercalated disc. [36, 53]

Fibrosis and AF are associated with disordered electrotonic coupling, e.g. alteration of intracellular calcium concentration in the myofibroblast.[51] Such arrhythmogenic ion alterations have been well documented in AF.[54]

Phenomena such as automaticity and ectopy may occur, at least in part, due to this fibrosis - induced disordered electrotonic coupling, as demonstrated in computational modelling studies. [55][56, 57]

How, then, do these microscopic mechanisms translate to macroscopic electrical changes in the atrium? In a small study (n=6) of bi-atrial mapping in surgical

patients with AF, lines of conduction block were noted in the right atrium, around which multiple large wavefronts propagated. In the left atrium, multiple, high frequency, repetitive activity was documented - lending weight to the hypothesis that focal triggers and an arrhythmogenic substrate exist in humans.[58] In a sheep heart failure model, fibrosis coincided with enhanced endocardial breakthrough in the posterior LA, with intra-mural re-entry allowing maintenance of AF.[59] An earlier human study supported the heterogenous complexity of wavefronts.[52] Finally, there is significant longitudinal dissociation between muscle bundles (with higher levels of dissociation in persistent AF *cf.* acute AF). This results in transient, dynamic alterations in wave boundaries, but with fibrillation waves that correspond spatially to muscle bundle structure. The predominant feature of persistent AF in this study was longitudinal dissociation of conduction with lines of block running in parallel with the muscle fibres. More chaotic fusion and collision of wavefronts were seen in acute (induced) AF, suggesting a more organised AF substrate in long-standing AF.[60]

The identification of tissue displaying these properties, referred to clinically as electrophysiological substrate, has been attractive to clinicians for some time, hoping that targeting, or isolating, such areas during ablation procedures may increase procedural success. A number of clinical tools have been suggested as a means to identify such tissue. e.g. ablation of complex fractionated electrograms, however, recent randomised evidence suggests clinical outcomes may not be improved by such existing approaches in persistent AF.[61]

Identification of fibrosis and targeting of ablation with electro-anatomical mapping

The presence of areas of low voltage within the left atrium is independently associated with recurrence of atrial arrhythmia after percutaneous ablation, and regional structural remodelling (as seen in fibrotic atria) has been associated spatially with such low voltage areas.[62, 63] Pulmonary vein isolation remains the mainstay of AF ablation, but the identification and ablation or isolation of low-voltage areas is a possible therapeutic strategy with encouraging early indications in both paroxysmal and non-paroxysmal AF.[64, 65]

Electrophysiological AF substrate is thought, in some instances, to be manifest by complex fractionated electrocardiograms (CFAE), although the precise aetiology of CFAE is debated, and they are not unique to fibrotic tissue.[66] However, attempts have been made to relate CFAEs to atrial fibrosis in humans, after evidence that they relate to fibrosis and disordered connexin expression in animals.[67] Also, computational modelling suggests that fibroblasts may contribute to the presence of CFAE.[68] In the study in humans by Jadidi et al. however, CFAE did not relate to areas of fibrosis identified by MRI. Lower voltage did relate to these fibrotic areas.[69] In the past, CFAE ablation has been a widely - used strategy, but it appears from these results that CFAE does not equate sufficiently with substrate, perhaps explaining the limited overall success of this approach.[70] Operators must now consider whether targeted CFAE ablation can be justified at all, particularly in the light of the STAR-AF II trial

which showed no benefit over pulmonary vein isolation alone in persistent AF ablation.[61]

Focal impulse and rotor modulation (FIRM) is being explored as a novel method to isolate or ablate AF substrate and / or triggers.[71] The phenomena identified by FIRM (focal impulses and rotors) have been demonstrated in experimental models of AF, although evidence for their role in initiating and maintaining human AF is lacking.[72] No clear link with fibrosis has been identified. Recent long-term outcome data has been disappointing (in contrast to earlier studies), and randomized data is called for.[73]

It is therefore apparent that electrophysiological mapping has its limitations. Although identification of low voltage areas has some promise, voltage cut-offs for the identification of atrial fibrosis are not established, although a classification system has been suggested.[74] Accurate assessment of myocardial voltage requires adequate contact between the mapping catheter and the myocardium, but high-density mapping catheters with such an ability are unavailable. Similarly, the orientation of the catheter, the underlying rhythm, the electrode size and the distance between poles all have an impact on accurate voltage assessment. The inherent problem of spatial error and drift during a long AF case poses a challenge to the idea of targeting areas of fibrosis precisely. EP mapping is not suitable to aid the selection of ablation patients.

Pre-procedural imaging of fibrosis

Echocardiography remains the initial method of screening for underlying heart disease that may imply lower chances of success – such as left atrial dilatation, valvular heart disease, or left ventricular systolic impairment. Magnetic resonance imaging (MRI) and computed tomography (CT), have further advantages including more accurate analysis of cardiac chamber volume and function.[75]. Left atrial fibrosis can be detected by MRI (T1 mapping and delayed gadolinium enhancement) or echocardiographic integrated backscatter. The latter is not routinely used, but is widely available. It has been associated with an increased risk of arrhythmia recurrence after ablation.[76] The technique is semi-quantitative, and is subject to the limitations of any echocardiographic technique, principally inter-operator variation and the variability of image quality between patients. It also lacks the potential to provide information regarding the spatial location of fibrotic areas within the atrium.

Late gadolinium enhancement (LGE) MRI, on the other hand, can be used to quantify overall atrial burden of fibrosis and display it onto a 3-dimensional reconstruction. Gadolinium is taken up by cardiac tissue but remains within fibrotic tissue for longer than normal tissue. The technique is heavily dependent on accurate left atrial segmentation and takes time. The principal disadvantage of MRI, at least at present, hinges around limitations in spatial resolution; the smallest resolvable dimension may be similar to the thickness of the atrial wall itself, making both qualitative and quantitative assessment of gadolinium uptake

challenging. Also MRI is less readily available than echocardiography. Nevertheless, a number of studies, most notably the DECAAF study by Marrouche et al., have shown significant correlation between fibrosis and ablation outcome[77-79]. The group have proposed a classification of LA fibrosis from stages I (<10% of the LA wall) to IV (>30%), with recurrence rates of 15% and 51%, respectively.

The use of LGE-MRI to guide targeted ablation of discrete areas of fibrosis has not yet been studied in depth, although Oakes et al. showed a quantitative relationship between gadolinium enhancement and low voltage areas on EP mapping.[80] Improvement in MRI spatial resolution and the combination of MRI data with EP data may aid targeted ablation or isolation of AF substrate.

Conclusion

Fibrosis is important in the pathophysiology of AF. A number of methods of assessing the extent of fibrosis are available, but have not been validated for clinical use. How this data relates to successful restoration of sinus rhythm remains unclear. A clinical score to predict outcome based on data from multiple sources (e.g. MRI and biomarkers) may be what is needed to help guide clinicians as to which patients will maintain sinus rhythm in the long term, however, as we have discussed in this review, there are significant conflicts in existing data, such that any such scoring system seems a distant prospect. Further fundamental research is required, perhaps even redressing the manner in which AF is conventionally classified, in order to provide a stable platform for future therapeutic directions.

REFERENCES

- [1] Ganesan AN, Shipp NJ, Brooks AG, Kuklik P, Lau DH, Lim HS, et al. Long-term outcomes of catheter ablation of atrial fibrillation: a systematic review and meta-analysis. *J Am Heart Assoc.* 2013;2:e004549.
- [2] Lijnen PJ, Petrov VV, Fagard RH. Induction of cardiac fibrosis by transforming growth factor-beta(1). *Mol Genet Metab.* 2000;71:418-35.
- [3] Leask A. Potential therapeutic targets for cardiac fibrosis: TGFbeta, angiotensin, endothelin, CCN2, and PDGF, partners in fibroblast activation. *Circ Res.* 2010;106:1675-80.
- [4] Kivirikko KI, Risteli L. Biosynthesis of collagen and its alterations in pathological states. *Med Biol.* 1976;54:159-86.
- [5] Shi-Wen X, Denton CP, Dashwood MR, Holmes AM, Bou-Gharios G, Pearson JD, et al. Fibroblast matrix gene expression and connective tissue remodeling: role of endothelin-1. *J Invest Dermatol.* 2001;116:417-25.
- [6] Butt RP, Laurent GJ, Bishop JE. Collagen production and replication by cardiac fibroblasts is enhanced in response to diverse classes of growth factors. *Eur J Cell Biol.* 1995;68:330-5.
- [7] Guarda E, Katwa LC, Myers PR, Tyagi SC, Weber KT. Effects of endothelins on collagen turnover in cardiac fibroblasts. *Cardiovasc Res.* 1993;27:2130-4.
- [8] Brilla CG, Zhou G, Rupp H, Maisch B, Weber KT. Role of angiotensin II and prostaglandin E2 in regulating cardiac fibroblast collagen turnover. *Am J Cardiol.* 1995;76:8D-13D.

- [9] Siwik DA, Chang DL, Colucci WS. Interleukin-1beta and tumor necrosis factor-alpha decrease collagen synthesis and increase matrix metalloproteinase activity in cardiac fibroblasts in vitro. *Circ Res.* 2000;86:1259-65.
- [10] Tsuruda T, Boerrigter G, Huntley BK, Noser JA, Cataliotti A, Costello-Boerrigter LC, et al. Brain natriuretic Peptide is produced in cardiac fibroblasts and induces matrix metalloproteinases. *Circ Res.* 2002;91:1127-34.
- [11] Frustaci A, Chimenti C, Bellocci F, Morgante E, Russo MA, Maseri A. Histological substrate of atrial biopsies in patients with lone atrial fibrillation. *Circulation.* 1997;96:1180-4.
- [12] Luo MH, Li YS, Yang KP. Fibrosis of collagen I and remodeling of connexin 43 in atrial myocardium of patients with atrial fibrillation. *Cardiology.* 2007;107:248-53.
- [13] Adam O, Theobald K, Lavall D, Grube M, Kroemer HK, Ameling S, et al. Increased lysyl oxidase expression and collagen cross-linking during atrial fibrillation. *J Mol Cell Cardiol.* 2011;50:678-85.
- [14] Burstein B, Qi XY, Yeh YH, Calderone A, Nattel S. Atrial cardiomyocyte tachycardia alters cardiac fibroblast function: a novel consideration in atrial remodeling. *Cardiovasc Res.* 2007;76:442-52.
- [15] Powell DW, Mifflin RC, Valentich JD, Crowe SE, Saada JI, West AB. Myofibroblasts. I. Paracrine cells important in health and disease. *Am J Physiol.* 1999;277:C1-9.
- [16] Rucker-Martin C, Pecker F, Godreau D, Hatem SN. Dedifferentiation of atrial myocytes during atrial fibrillation: role of fibroblast proliferation in vitro. *Cardiovasc Res.* 2002;55:38-52.

- [17] Frost L, Hune LJ, Vestergaard P. Overweight and obesity as risk factors for atrial fibrillation or flutter: the Danish Diet, Cancer, and Health Study. *Am J Med.* 2005;118:489-95.
- [18] Thanassoulis G, Massaro JM, O'Donnell CJ, Hoffmann U, Levy D, Ellinor PT, et al. Pericardial fat is associated with prevalent atrial fibrillation: the Framingham Heart Study. *Circ Arrhythm Electrophysiol.* 2010;3:345-50.
- [19] Wong CX, Abed HS, Molaee P, Nelson AJ, Brooks AG, Sharma G, et al. Pericardial fat is associated with atrial fibrillation severity and ablation outcome. *J Am Coll Cardiol.* 2011;57:1745-51.
- [20] Tsao HM, Hu WC, Wu MH, Tai CT, Lin YJ, Chang SL, et al. Quantitative analysis of quantity and distribution of epicardial adipose tissue surrounding the left atrium in patients with atrial fibrillation and effect of recurrence after ablation. *Am J Cardiol.* 2011;107:1498-503.
- [21] Hatem SN, Sanders P. Epicardial adipose tissue and atrial fibrillation. *Cardiovasc Res.* 2014;102:205-13.
- [22] Li D, Shinagawa K, Pang L, Leung TK, Cardin S, Wang Z, et al. Effects of angiotensin-converting enzyme inhibition on the development of the atrial fibrillation substrate in dogs with ventricular tachypacing-induced congestive heart failure. *Circulation.* 2001;104:2608-14.
- [23] Shimano M, Tsuji Y, Inden Y, Kitamura K, Uchikawa T, Harata S, et al. Pioglitazone, a peroxisome proliferator-activated receptor-gamma activator, attenuates atrial fibrosis and atrial fibrillation promotion in rabbits with congestive heart failure. *Heart Rhythm.* 2008;5:451-9.

- [24] Pedersen OD, Bagger H, Kober L, Torp-Pedersen C. Trandolapril reduces the incidence of atrial fibrillation after acute myocardial infarction in patients with left ventricular dysfunction. *Circulation*. 1999;100:376-80.
- [25] Vermes E, Tardif JC, Bourassa MG, Racine N, Levesque S, White M, et al. Enalapril decreases the incidence of atrial fibrillation in patients with left ventricular dysfunction: insight from the Studies Of Left Ventricular Dysfunction (SOLVD) trials. *Circulation*. 2003;107:2926-31.
- [26] Madrid AH, Bueno MG, Rebollo JM, Marin I, Pena G, Bernal E, et al. Use of irbesartan to maintain sinus rhythm in patients with long-lasting persistent atrial fibrillation: a prospective and randomized study. *Circulation*. 2002;106:331-6.
- [27] Boldt A, Scholl A, Garbade J, Resetar ME, Mohr FW, Gummert JF, et al. ACE-inhibitor treatment attenuates atrial structural remodeling in patients with lone chronic atrial fibrillation. *Basic Res Cardiol*. 2006;101:261-7.
- [28] Schneider MP, Hua TA, Bohm M, Wachtell K, Kjeldsen SE, Schmieder RE. Prevention of atrial fibrillation by Renin-Angiotensin system inhibition a meta-analysis. *J Am Coll Cardiol*. 2010;55:2299-307.
- [29] Jibrini MB, Molnar J, Arora RR. Prevention of atrial fibrillation by way of abrogation of the renin-angiotensin system: a systematic review and meta-analysis. *Am J Ther*. 2008;15:36-43.
- [30] Kumagai K, Nakashima H, Saku K. The HMG-CoA reductase inhibitor atorvastatin prevents atrial fibrillation by inhibiting inflammation in a canine sterile pericarditis model. *Cardiovasc Res*. 2004;62:105-11.

- [31] Shiroshita-Takeshita A, Brundel BJ, Burstein B, Leung TK, Mitamura H, Ogawa S, et al. Effects of simvastatin on the development of the atrial fibrillation substrate in dogs with congestive heart failure. *Cardiovasc Res*. 2007;74:75-84.
- [32] Okumura Y, Watanabe I, Nakai T, Ohkubo K, Kofune T, Kofune M, et al. Impact of biomarkers of inflammation and extracellular matrix turnover on the outcome of atrial fibrillation ablation: importance of matrix metalloproteinase-2 as a predictor of atrial fibrillation recurrence. *J Cardiovasc Electrophysiol*. 2011;22:987-93.
- [33] Kornej J, Schmidl J, Ueberham L, John S, Daneschnejad S, Dinov B, et al. Galectin-3 in patients with atrial fibrillation undergoing radiofrequency catheter ablation. *PLoS One*. 2015;10:e0123574.
- [34] de Jong S, van Veen TA, van Rijen HV, de Bakker JM. Fibrosis and cardiac arrhythmias. *J Cardiovasc Pharmacol*. 2011;57:630-8.
- [35] Kawara T, Derksen R, de Groot JR, Coronel R, Tasseron S, Linnenbank AC, et al. Activation delay after premature stimulation in chronically diseased human myocardium relates to the architecture of interstitial fibrosis. *Circulation*. 2001;104:3069-75.
- [36] Spach MS, Heidlage JF, Dolber PC, Barr RC. Mechanism of origin of conduction disturbances in aging human atrial bundles: experimental and model study. *Heart Rhythm*. 2007;4:175-85.
- [37] Verheule S, Tuyls E, Gharaviri A, Hulsmans S, van Hunnik A, Kuiper M, et al. Loss of continuity in the thin epicardial layer because of endomysial fibrosis increases the complexity of atrial fibrillatory conduction. *Circ Arrhythm Electrophysiol*. 2013;6:202-11.

- [38] Angel N, Li LI, Macleod RS, Marrouche N, Ranjan R, Dossall DJ. Diverse Fibrosis Architecture and Premature Stimulation Facilitate Initiation of Reentrant Activity Following Chronic Atrial Fibrillation. *J Cardiovasc Electrophysiol.* 2015.
- [39] Krul SP, Berger WR, Smit NW, van Amersfoorth SC, Driessen AH, van Boven WJ, et al. Atrial fibrosis and conduction slowing in the left atrial appendage of patients undergoing thoracoscopic surgical pulmonary vein isolation for atrial fibrillation. *Circ Arrhythm Electrophysiol.* 2015;8:288-95.
- [40] de Bakker JM, van Capelle FJ, Janse MJ, Tasseron S, Vermeulen JT, de Jonge N, et al. Slow conduction in the infarcted human heart. 'Zigzag' course of activation. *Circulation.* 1993;88:915-26.
- [41] Ausma J, Wijffels M, van Eys G, Koide M, Ramaekers F, Allessie M, et al. Dedifferentiation of atrial cardiomyocytes as a result of chronic atrial fibrillation. *Am J Pathol.* 1997;151:985-97.
- [42] Park JH, Pak HN, Lee S, Park HK, Seo JW, Chang BC. The clinical significance of the atrial subendocardial smooth muscle layer and cardiac myofibroblasts in human atrial tissue with valvular atrial fibrillation. *Cardiovasc Pathol.* 2013;22:58-64.
- [43] Kohl P, Kamkin AG, Kiseleva IS, Noble D. Mechanosensitive fibroblasts in the sino-atrial node region of rat heart: interaction with cardiomyocytes and possible role. *Exp Physiol.* 1994;79:943-56.
- [44] Gaudesius G, Miragoli M, Thomas SP, Rohr S. Coupling of cardiac electrical activity over extended distances by fibroblasts of cardiac origin. *Circ Res.* 2003;93:421-8.

- [45] Chilton L, Ohya S, Freed D, George E, Drobic V, Shibukawa Y, et al. K⁺ currents regulate the resting membrane potential, proliferation, and contractile responses in ventricular fibroblasts and myofibroblasts. *Am J Physiol Heart Circ Physiol.* 2005;288:H2931-9.
- [46] Miragoli M, Gaudesius G, Rohr S. Electrotonic modulation of cardiac impulse conduction by myofibroblasts. *Circ Res.* 2006;98:801-10.
- [47] Thompson SA, Copeland CR, Reich DH, Tung L. Mechanical coupling between myofibroblasts and cardiomyocytes slows electric conduction in fibrotic cell monolayers. *Circulation.* 2011;123:2083-93.
- [48] Pedrotty DM, Klinger RY, Kirkton RD, Bursac N. Cardiac fibroblast paracrine factors alter impulse conduction and ion channel expression of neonatal rat cardiomyocytes. *Cardiovasc Res.* 2009;83:688-97.
- [49] Rohr S. Arrhythmogenic implications of fibroblast-myocyte interactions. *Circ Arrhythm Electrophysiol.* 2012;5:442-52.
- [50] Camelliti P, Green CR, LeGrice I, Kohl P. Fibroblast network in rabbit sinoatrial node: structural and functional identification of homogeneous and heterogeneous cell coupling. *Circ Res.* 2004;94:828-35.
- [51] Chilton L, Giles WR, Smith GL. Evidence of intercellular coupling between co-cultured adult rabbit ventricular myocytes and myofibroblasts. *J Physiol.* 2007;583:225-36.
- [52] Kanagaratnam P, Cherian A, Stanbridge RD, Glenville B, Severs NJ, Peters NS. Relationship between connexins and atrial activation during human atrial fibrillation. *J Cardiovasc Electrophysiol.* 2004;15:206-16.
- [53] Kostin S, Klein G, Szalay Z, Hein S, Bauer EP, Schaper J. Structural correlate of atrial fibrillation in human patients. *Cardiovasc Res.* 2002;54:361-79.

- [54] Nattel S, Maguy A, Le Bouter S, Yeh YH. Arrhythmogenic ion-channel remodeling in the heart: heart failure, myocardial infarction, and atrial fibrillation. *Physiol Rev.* 2007;87:425-56.
- [55] Miragoli M, Salvarani N, Rohr S. Myofibroblasts induce ectopic activity in cardiac tissue. *Circ Res.* 2007;101:755-8.
- [56] Jacquemet V, Henriquez CS. Modelling cardiac fibroblasts: interactions with myocytes and their impact on impulse propagation. *Europace.* 2007;9 Suppl 6:vi29-37.
- [57] Xie Y, Garfinkel A, Camelliti P, Kohl P, Weiss JN, Qu Z. Effects of fibroblast-myocyte coupling on cardiac conduction and vulnerability to reentry: A computational study. *Heart Rhythm.* 2009;6:1641-9.
- [58] Haissaguerre M, Jais P, Shah DC, Takahashi A, Hocini M, Quiniou G, et al. Spontaneous initiation of atrial fibrillation by ectopic beats originating in the pulmonary veins. *N Engl J Med.* 1998;339:659-66.
- [59] Tanaka K, Zlochiver S, Vikstrom KL, Yamazaki M, Moreno J, Klos M, et al. Spatial distribution of fibrosis governs fibrillation wave dynamics in the posterior left atrium during heart failure. *Circ Res.* 2007;101:839-47.
- [60] Allessie MA, de Groot NM, Houben RP, Schotten U, Boersma E, Smeets JL, et al. Electropathological substrate of long-standing persistent atrial fibrillation in patients with structural heart disease: longitudinal dissociation. *Circ Arrhythm Electrophysiol.* 2010;3:606-15.
- [61] Verma A, Jiang CY, Betts TR, Chen J, Deisenhofer I, Mantovan R, et al. Approaches to catheter ablation for persistent atrial fibrillation. *N Engl J Med.* 2015;372:1812-22.

- [62] Park JH, Pak HN, Choi EJ, Jang JK, Kim SK, Choi DH, et al. The relationship between endocardial voltage and regional volume in electroanatomical remodeled left atria in patients with atrial fibrillation: comparison of three-dimensional computed tomographic images and voltage mapping. *J Cardiovasc Electrophysiol.* 2009;20:1349-56.
- [63] Verma A, Wazni OM, Marrouche NF, Martin DO, Kilicaslan F, Minor S, et al. Pre-existent left atrial scarring in patients undergoing pulmonary vein antrum isolation: an independent predictor of procedural failure. *J Am Coll Cardiol.* 2005;45:285-92.
- [64] Wang H, Cai H, Ao L, Yan H, Zhao W, Qi L, et al. Individualized identification of disease-associated pathways with disrupted coordination of gene expression. *Brief Bioinform.* 2015.
- [65] Kottkamp H, Berg J, Bender R, Rieger A, Schreiber D. Box Isolation of Fibrotic Areas (BIFA): A Patient-Tailored Substrate Modification Approach for Ablation of Atrial Fibrillation. *J Cardiovasc Electrophysiol.* 2015.
- [66] Konings KT, Smeets JL, Penn OC, Wellens HJ, Allessie MA. Configuration of unipolar atrial electrograms during electrically induced atrial fibrillation in humans. *Circulation.* 1997;95:1231-41.
- [67] Liu X, Shi HF, Tan HW, Wang XH, Zhou L, Gu JN. Decreased connexin 43 and increased fibrosis in atrial regions susceptible to complex fractionated atrial electrograms. *Cardiology.* 2009;114:22-9.
- [68] Ashihara T, Haraguchi R, Nakazawa K, Namba T, Ikeda T, Nakazawa Y, et al. The role of fibroblasts in complex fractionated electrograms during persistent/permanent atrial fibrillation: implications for electrogram-based catheter ablation. *Circ Res.* 2012;110:275-84.

- [69] Jadidi AS, Cochet H, Shah AJ, Kim SJ, Duncan E, Miyazaki S, et al. Inverse relationship between fractionated electrograms and atrial fibrosis in persistent atrial fibrillation: combined magnetic resonance imaging and high-density mapping. *J Am Coll Cardiol*. 2013;62:802-12.
- [70] Nademanee K, McKenzie J, Kosar E, Schwab M, Sunsaneewitayakul B, Vasavakul T, et al. A new approach for catheter ablation of atrial fibrillation: mapping of the electrophysiologic substrate. *J Am Coll Cardiol*. 2004;43:2044-53.
- [71] Narayan SM, Krummen DE, Shivkumar K, Clopton P, Rappel WJ, Miller JM. Treatment of atrial fibrillation by the ablation of localized sources: CONFIRM (Conventional Ablation for Atrial Fibrillation With or Without Focal Impulse and Rotor Modulation) trial. *J Am Coll Cardiol*. 2012;60:628-36.
- [72] Vaquero M, Calvo D, Jalife J. Cardiac fibrillation: from ion channels to rotors in the human heart. *Heart Rhythm*. 2008;5:872-9.
- [73] Buch E, Share M, Tung R, Benharash P, Sharma P, Koneru J, et al. Long-term clinical outcomes of focal impulse and rotor modulation for treatment of atrial fibrillation: A multicenter experience. *Heart Rhythm*. 2016;13:636-41.
- [74] Kapa S, Desjardins B, Callans DJ, Marchlinski FE, Dixit S. Contact electroanatomic mapping derived voltage criteria for characterizing left atrial scar in patients undergoing ablation for atrial fibrillation. *J Cardiovasc Electrophysiol*. 2014;25:1044-52.
- [75] Bax JJ, Marsan NA, Delgado V. Non-invasive imaging in atrial fibrillation: focus on prognosis and catheter ablation. *Heart*. 2015;101:94-100.
- [76] den Uijl DW, Delgado V, Bertini M, Tops LF, Trines SA, van de Veire NR, et al. Impact of left atrial fibrosis and left atrial size on the outcome of catheter ablation for atrial fibrillation. *Heart*. 2011;97:1847-51.

- [77] Marrouche NF, Wilber D, Hindricks G, Jais P, Akoum N, Marchlinski F, et al. Association of atrial tissue fibrosis identified by delayed enhancement MRI and atrial fibrillation catheter ablation: the DECAAF study. *JAMA*. 2014;311:498-506.
- [78] Akoum N, Daccarett M, McGann C, Segerson N, Vergara G, Kuppahally S, et al. Atrial fibrosis helps select the appropriate patient and strategy in catheter ablation of atrial fibrillation: a DE-MRI guided approach. *J Cardiovasc Electrophysiol*. 2011;22:16-22.
- [79] McGann C, Akoum N, Patel A, Kholmovski E, Revelo P, Damal K, et al. Atrial fibrillation ablation outcome is predicted by left atrial remodeling on MRI. *Circ Arrhythm Electrophysiol*. 2014;7:23-30.
- [80] Oakes RS, Badger TJ, Kholmovski EG, Akoum N, Burgon NS, Fish EN, et al. Detection and quantification of left atrial structural remodeling with delayed-enhancement magnetic resonance imaging in patients with atrial fibrillation. *Circulation*. 2009;119:1758-67.
- [81] Kim SK, Pak HN, Park JH, Ko KJ, Lee JS, Choi JI, et al. Clinical and serological predictors for the recurrence of atrial fibrillation after electrical cardioversion. *Europace*. 2009;11:1632-8.
- [82] Kato K, Fujimaki T, Yoshida T, Oguri M, Yajima K, Hibino T, et al. Impact of matrix metalloproteinase-2 levels on long-term outcome following pharmacological or electrical cardioversion in patients with atrial fibrillation. *Europace*. 2009;11:332-7.
- [83] Lombardi F, Belletti S, Battezzati PM, Pacciolla R, Biondi ML. MMP-1 and MMP-3 polymorphism and arrhythmia recurrence after electrical cardioversion in patients with persistent atrial fibrillation. *J Cardiovasc Med (Hagerstown)*. 2011;12:37-42.

- [84] Kawamura M, Munetsugu Y, Kawasaki S, Onishi K, Onuma Y, Kikuchi M, et al. Type III procollagen-N-peptide as a predictor of persistent atrial fibrillation recurrence after cardioversion. *Europace*. 2012;14:1719-25.
- [85] Mukherjee R, Akar JG, Wharton JM, Adams DK, McClure CD, Stroud RE, et al. Plasma profiles of matrix metalloproteinases and tissue inhibitors of the metalloproteinases predict recurrence of atrial fibrillation following cardioversion. *J Cardiovasc Transl Res*. 2013;6:528-35.
- [86] Kallergis EM, Goudis CA, Kanoupakis EM, Mavrakis HE, Maliaraki NE, Tzanakis N, et al. Sinus rhythm restoration affects collagen turnover in patients with persistent atrial fibrillation. *Europace*. 2014;16:1726-30.
- [87] Kim SK, Park JH, Kim JY, Choi JI, Joung B, Lee MH, et al. High plasma concentrations of transforming growth factor-beta and tissue inhibitor of metalloproteinase-1: potential non-invasive predictors for electroanatomical remodeling of atrium in patients with non-valvular atrial fibrillation. *Circ J*. 2011;75:557-64.
- [88] Richter B, Gwechenberger M, Socas A, Zorn G, Albinni S, Marx M, et al. Time course of markers of tissue repair after ablation of atrial fibrillation and their relation to left atrial structural changes and clinical ablation outcome. *Int J Cardiol*. 2011;152:231-6.
- [89] Wu CH, Hu YF, Chou CY, Lin YJ, Chang SL, Lo LW, et al. Transforming growth factor- β 1 level and outcome after catheter ablation for nonparoxysmal atrial fibrillation. *Heart Rhythm*. 2013;10:10-5.
- [90] Kimura T, Takatsuki S, Inagawa K, Katsumata Y, Nishiyama T, Nishiyama N, et al. Serum inflammation markers predicting successful initial catheter ablation for atrial fibrillation. *Heart Lung Circ*. 2014;23:636-43.

- [91] Sasaki N, Okumura Y, Watanabe I, Mano H, Nagashima K, Sonoda K, et al. Increased levels of inflammatory and extracellular matrix turnover biomarkers persist despite reverse atrial structural remodeling during the first year after atrial fibrillation ablation. *J Interv Card Electrophysiol*. 2014;39:241-9.
- [92] Song ZP, Liu X, Zhang DD. Connective tissue growth factor: a predictor of recurrence after catheter ablation in patients with nonparoxysmal atrial fibrillation. *Pacing Clin Electrophysiol*. 2014;37:630-7.
- [93] Canpolat U, Oto A, Hazirolan T, Sunman H, Yorgun H, Sahiner L, et al. A prospective DE-MRI study evaluating the role of TGF-beta1 in left atrial fibrosis and implications for outcomes of cryoballoon-based catheter ablation: new insights into primary fibrotic atriacardiomyopathy. *J Cardiovasc Electrophysiol*. 2015;26:251-9.
- [94] Wu XY, Li SN, Wen SN, Nie JG, Deng WN, Bai R, et al. Plasma galectin-3 predicts clinical outcomes after catheter ablation in persistent atrial fibrillation patients without structural heart disease. *Europace*. 2015.

Table 1. Studies of relationship between circulating biomarkers of fibrosis and outcome of cardioversion and percutaneous ablation.

1 st Author	Ref	Sample	Fibrosis marker(s)		Study pop.	Controls	Follow up (months)	Comments
			Predictive of recurrence	Not predictive				
Cardioversion								
Kim	[81]	Plasma	TGF- β	MMP 9	81	-	13	Multivariate analysis. Length of follow up widely variable. TGF- β predicted DCCV failure but not recurrence of AF after successful DCCV.
Kato	[82]	Serum / plasma	MMP 2, TIMP 2	MMP 1, 9	102	-	28	Pharmacological cardioversion, DCCV if unsuccessful.
Lombardi	[83]	DNA (PCR)	MMP 1, 3	-	74	-	3 weeks	Analysis of gene polymorphism. Short follow up.
Kawamura	[84]	Serum	PIIINP	-	142	-	24	Pharmacological cardioversion, DCCV if unsuccessful. Excluded ACEI/ARB and BB. Short AF duration.
Mukherjee	[85]	Plasma	MMP 3, 9 TIMP 4	MMP 1, 2, 7, 8 TIMP 1-3	82	-	3	Open to type 1 error due to multiple markers. Short follow up.
Kallergis	[86]	Serum	CITP	CICP	164, Normal	-	2	Information on comorbidities not published. Short follow up. Population not representative - multiple exclusion criteria
Percutaneous ablation								
Kim	[87]	Serum	-	TGF- β , MMP 1,2,9	242 (mixed PAF and PeAF)	-	22	Aimed to show relationship between TGF- β 1, TIMP 1, and

				TIMP 1				LA remodelling rather than arrhythmia recurrence. TGF- β 1 was related to low LA voltage and high LA volume. TIMP-1 was related to low LA voltage.
Okamura	[32]	Serum. 25 samples from LA or mid CS	MMP 2, C1TP	TIMP 2	50 (Mixed PAF/ PeAF/ LSPeAF)	-	14	AADs stopped at 3 months. MMP 2 predicted recurrence irrespective of PAF/non PAF. No diff. between LA/CS and peripheral levels. Small sample size.
Richter	[88]	Serum / plasma	PIIINP, but only over course of follow up	MMP 9, TGF- β 1	30 (PAF)	-	6	Small sample size. Not aimed at determining predictive value of baseline levels, but the changes in levels over post-ablation time course.
Wu	[89]	Plasma	TGF- β 1 in non- PAF	-	200 (mixed PAF/non-PAF)	-	6	TGF- β 1 predicted recurrence in the 46 nonPAF patients; relatively small sample size for this positive association compared to overall number. 95% CI for odds ratio 1.01- 1.22.
Kimura	[90]	Serum	MMP 2	C1TP, PINP, TIMP 2, TGF- β	44 (mixed PAF/PeAF)	-	10	Multiple markers, open to type 1 error. Small sample size.
Sasaki	[91]	Serum	MMP 2, TIMP 2	TGF- β 1	60 (mixed PAF/PeAF)	-	12	AADs stopped at 2 months. Aimed at post – ablation changes in levels.
Song	[92]	Serum	CTGF in non-PAF	-	400 (mixed PAF/non-PAF)	-	20	AADs stopped at 3 months. Of 400 patients, 92 were non-

patients							PAF in whom the association was found. 95% CI for the hazard ratio was 1.074 to 1.436.	
Kornej	[33]	Plasma. 10 samples from CS and LA	-	Gal-3	105 (mixed PAF/PeAF)	14	6	AADs stopped at ablation. Higher levels of galectin-3 in AF patients related to higher BMI on multivariate analysis.
Canpolat	[93]	Plasma	-	TGF- β 1 (in multivariate analysis)	41 (PAF)		18	AADs stopped after 3 months. TGF- β 1 was not independently associated with recurrence, but did predict extent of fibrosis as assessed by LGE-MRI, which in turn predicted AF recurrence.
Wu	[94]	Plasma	Gal-3	-	50 (PeAF, lone)	46	17	AADs stopped 2-3 months after ablation. Extensive exclusion criteria. Small sample size.
For abbreviations, see main list.								

Figures

Figure 1 title – Biomarkers in fibrosis.

Figure 1 legend – green boxes indicate substances measurable in the circulation.

PICP-procollagen I C peptide, PINP-procollagen I N peptide, PIIICP-procollagen III C peptide, PIIINP-procollagen III N peptide, TGF-transforming growth factor, PDGF-platelet-derived growth factor, IGF-insulin-like growth factor, GH-growth hormone, ET-endothelin, Gal-galectin, CTGF-connective tissue growth factor, IL-interleukin, BNP-brain-type natriuretic peptide, TNF-tumour necrosis factor, AT-angiotensin, MMP-matrix metalloprotein, ICTP-collagen I C telopeptide, TIMP-tissue inhibitor of MMP, CV-conduction velocity

Figure 2 title – Conduction abnormalities in atrial fibrosis

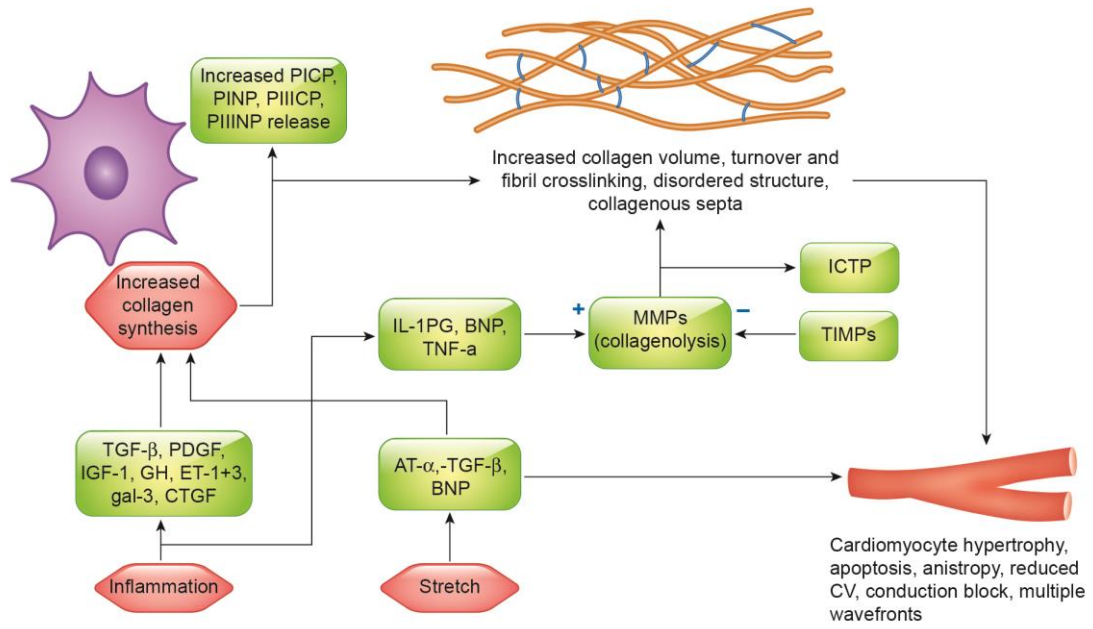


Fig. 1

ACCEPTED MANUSCRIPT

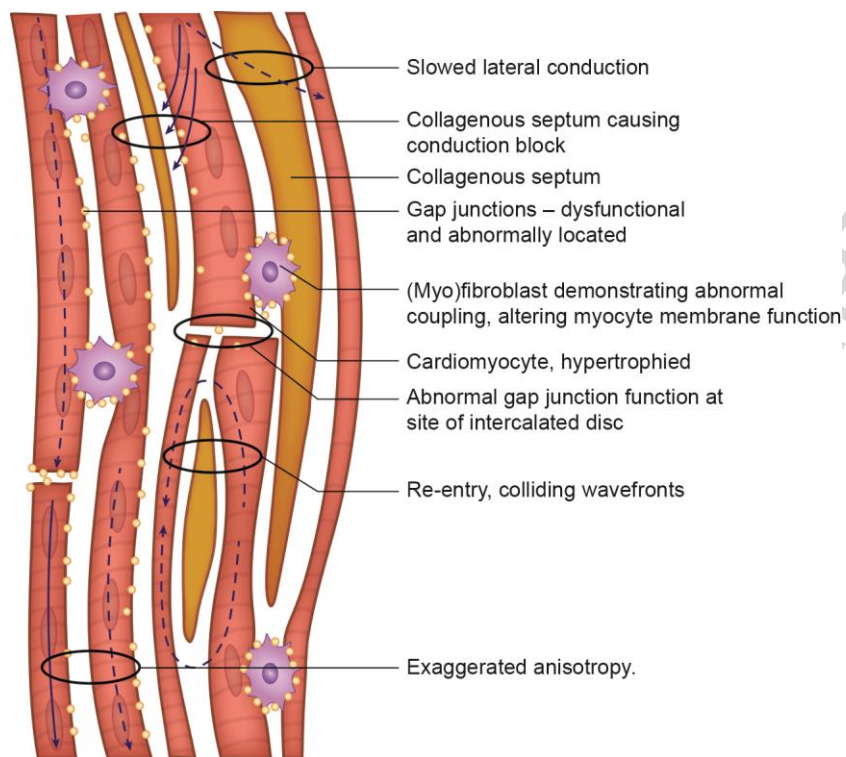


Fig. 2

Highlights

- Fibrosis and atrial fibrillation are associated, although causation remains unclear
- Myocardial changes caused by fibrosis result in diverse conduction abnormalities
- Assessment of fibrosis may aid selection of patients for rhythm control
- The strengths and weaknesses of these methods are discussed in this article

ACCEPTED MANUSCRIPT