

# Evaluation of treatment response and resistance in metastatic renal cell cancer (mRCC) using integrated $^{18}\text{F}$ -Fluorodeoxyglucose ( $^{18}\text{F}$ -FDG) positron emission tomography/magnetic resonance imaging (PET/MRI); The REMAP study

Chrisian, Kelly-Morland; Rudman, Sarah M; Nathan, Paul; Mallett, Susan; Montana, Giovanni; Cook, Gary J R; Goh, Vicky

DOI:

[10.1186/s12885-017-3371-9](https://doi.org/10.1186/s12885-017-3371-9)

License:

Creative Commons: Attribution (CC BY)

## Document Version

Publisher's PDF, also known as Version of record

## Citation for published version (Harvard):

Chrisian, K-M, Rudman, SM, Nathan, P, Mallett, S, Montana, G, Cook, GJR & Goh, V 2017, 'Evaluation of treatment response and resistance in metastatic renal cell cancer (mRCC) using integrated  $^{18}\text{F}$ -Fluorodeoxyglucose ( $^{18}\text{F}$ -FDG) positron emission tomography/magnetic resonance imaging (PET/MRI); The REMAP study', *BMC Cancer*, vol. 17, no. 1, 392. <https://doi.org/10.1186/s12885-017-3371-9>

[Link to publication on Research at Birmingham portal](#)

## General rights

Unless a licence is specified above, all rights (including copyright and moral rights) in this document are retained by the authors and/or the copyright holders. The express permission of the copyright holder must be obtained for any use of this material other than for purposes permitted by law.

- Users may freely distribute the URL that is used to identify this publication.
- Users may download and/or print one copy of the publication from the University of Birmingham research portal for the purpose of private study or non-commercial research.
- User may use extracts from the document in line with the concept of 'fair dealing' under the Copyright, Designs and Patents Act 1988 (?)
- Users may not further distribute the material nor use it for the purposes of commercial gain.

Where a licence is displayed above, please note the terms and conditions of the licence govern your use of this document.

When citing, please reference the published version.

## Take down policy

While the University of Birmingham exercises care and attention in making items available there are rare occasions when an item has been uploaded in error or has been deemed to be commercially or otherwise sensitive.

If you believe that this is the case for this document, please contact [UBIRA@lists.bham.ac.uk](mailto:UBIRA@lists.bham.ac.uk) providing details and we will remove access to the work immediately and investigate.


Download date: 15. Oct. 2024

STUDY PROTOCOL

Open Access



# Evaluation of treatment response and resistance in metastatic renal cell cancer (mRCC) using integrated $^{18}\text{F}$ -Fluorodeoxyglucose ( $^{18}\text{F}$ -FDG) positron emission tomography/magnetic resonance imaging (PET/MRI); The REMAP study

Christian Kelly-Morland<sup>1\*</sup> , Sarah Rudman<sup>2</sup>, Paul Nathan<sup>3</sup>, Susan Mallett<sup>4</sup>, Giovanni Montana<sup>5</sup>, Gary Cook<sup>1</sup> and Vicky Goh<sup>1</sup>

## Abstract

**Background:** Tyrosine kinase inhibitors are the first line standard of care for treatment of metastatic renal cell carcinoma (RCC). Accurate response assessment in the setting of antiangiogenic therapies remains suboptimal as standard size-related response criteria do not necessarily accurately reflect clinical benefit, as they may be less pronounced or occur later in therapy than devascularisation. The challenge for imaging is providing timely assessment of disease status allowing therapies to be tailored to ensure ongoing clinical benefit. We propose that combined assessment of morphological, physiological and metabolic imaging parameters using  $^{18}\text{F}$ -fluorodeoxyglucose positron emission tomography/magnetic resonance imaging ( $^{18}\text{F}$ -FDG PET/MRI) will better reflect disease behaviour, improving assessment of response/non-response/relapse.

**Methods/design:** The REMAP study is a single-centre prospective observational study. Eligible patients with metastatic renal cell carcinoma, planned for systemic therapy, with at least 2 lesions will undergo an integrated  $^{18}\text{F}$ -FDG PET and MRI whole body imaging with diffusion weighted and contrast-enhanced multiphasic as well as standard anatomical MRI sequences at baseline, 12 weeks and 24 weeks of systemic therapy allowing  $^{18}\text{F}$ -FDG standardised uptake value (SUV), apparent diffusion co-efficient (ADC) and normalised signal intensity (SI) parameters to be obtained. Standard of care contrast-enhanced computed tomography CT scans will be performed at equivalent time-points. CT response categorisation will be performed using RECIST 1.1 and alternative (modified) Choi and MASS criteria. The reference standard for disease status will be by consensus panel taking into account clinical, biochemical and conventional imaging parameters. Intra- and inter-tumoural heterogeneity in vascular, diffusion and metabolic response/non-response will be assessed by image texture analysis. Imaging will also inform the development of computational methods for automated disease status categorisation.

(Continued on next page)

\* Correspondence: christian.kellymorland@gmail.com

<sup>1</sup>Department of Cancer Imaging, King's College London Division of Imaging Sciences & Biomedical Engineering, St Thomas' Hospital, Westminster Bridge Road, London SE1 7EH, UK

Full list of author information is available at the end of the article



(Continued from previous page)

**Discussion:** The REMAP study will demonstrate the ability of integrated  $^{18}\text{F}$ -FDG PET-MRI to provide a more personalised approach to therapy. We suggest that  $^{18}\text{F}$ -FDG PET/MRI will provide superior sensitivity and specificity in early response/non-response categorisation when compared to standard CT (using RECIST 1.1 and alternative (modified)Choi or MASS criteria) thus facilitating more timely and better informed treatment decisions.

**Trial registration:** The trial is approved by the Southeast London Research Ethics Committee reference 16/LO/1499 and registered on the NIHR clinical research network portfolio ISRCTN12114913.

**Keywords:** Metastatic renal cell carcinoma, Magnetic resonance imaging, Positron emission tomography, Pet/MRI, Response assessment

## Background

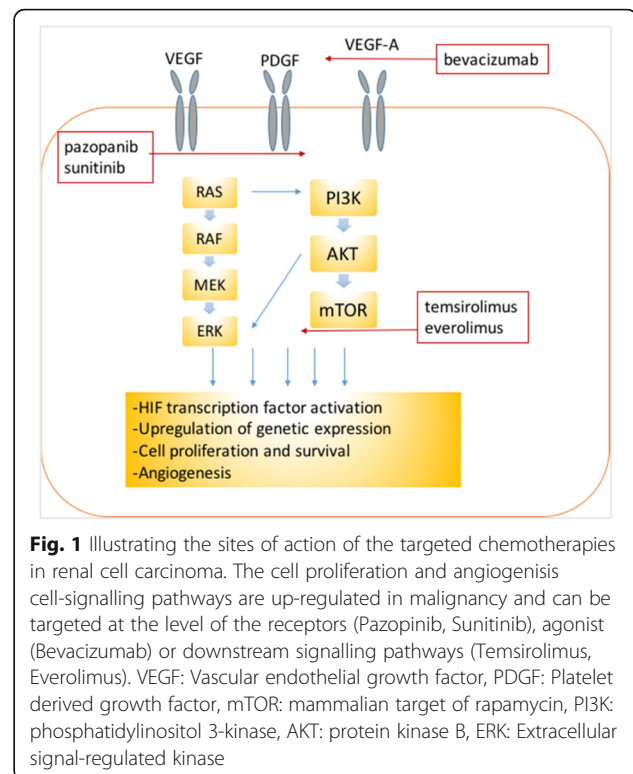
Renal cell carcinoma (RCC) is currently the ninth commonest cancer with a worldwide incidence of 2.4% in 2012 [1]. Usually presenting in the sixth and seventh decades of life, and commoner in men than women, the incidence of the disease has been rising steadily at approximately 1.1% per year over the last decade [2]. The commonest histological subtype of RCC is clear cell, accounting for 70% of cases with papillary RCC and the more indolent chromophobe subtype contributing to the remaining majority. Rarer entities such as the aggressive collecting duct carcinoma account for less than 5% of cases [3]. The five-year survival rate in metastatic RCC remains poor at less than 12% [4]. Metastatic disease is present in up to 30% of patients at the time of diagnosis with up to a further 30% of patients subsequently developing metastases in the ensuing two years despite resection of the primary tumour [5].

## Treatment options

Systemic treatment options for metastatic RCC have shifted to targeted therapies in the last decade following demonstration of improved progression free survival in Phase III clinical trials [6–12]. Renal cell carcinoma can be a highly vascular tumour, for example, related to Von-Hippel Lindau gene mutations and accumulation of hypoxia inducible factor (HIF). Transcriptional targets of HIF include vascular endothelial growth factor (VEGF) and platelet derived growth factor (PDGF), with upregulation of angiogenesis, hence why anti-angiogenic targeted therapies have been successful in metastatic RCC.

A number of targeted agents have received FDA approval for metastatic RCC. These include the small molecule multi-kinase inhibitors including pazopanib, sunitinib, sorafenib and axitinib, the mammalian target of rapamycin (mTOR) inhibitors everolimus and temsirolimus, and the monoclonal antibody Bevacizumab, an inhibitor of vascular endothelial growth factor A. These agents selectively inhibit neo-angiogenesis and cell proliferation respectively through a variety of signalling pathways [13] including the RAS-RAF-MEK-ERK and PI3K-AKT-mTOR pathways (Fig. 1). These agents have

been shown to positively impact survival with transient stabilisation of disease in 70% of patients as well as providing scope for several lines of treatment [6–12]. More recently clinical trials of immunotherapeutic agents have also shown promise. These agents stimulate the immune system to destroy cancer cells and the possibility of a synergistic effect between immunotherapy and targeted therapy is under investigation [4]. The CheckMate 025 phase III multicentre trial of 821 patients demonstrated that the programmed (T-cell) death-1 (PD-1) inhibitor, nivolumab, which potentiates the native T-cell response has demonstrated favourable an overall survival benefit with a 27% reduction in the risk of death as well as a greater response rate (25% versus 5%) when compared to treatment with everolimus [14].



### The need for alternative imaging response biomarkers

Our preliminary work in patients treated with multi-kinase inhibitors has shown that different clinical imaging patterns may be observed with treatment [15]. New metastases may appear even if pre-existing lesions remain stable. Changes in size and/or vascularisation of existing lesions may occur either rapidly or slowly. Proposed vascular mechanisms of resistance include: 1) Up-regulation of alternative pro-angiogenic pathways, allowing the development of new abnormal tumour vessels, restoring tumour angiogenesis to its pre-treatment level and allowing rapid tumour growth; 2) Development of alternative metabolic pathways independent of vascular supply, which may represent a more aggressive phenotype; 3) Recruitment of vascular progenitor cells, pro-angiogenic monocytes, pericytes, or co-option of normal vessels, thus reconstituting vessels which do not have the typical characteristics of tumour vessels. These pseudo-normal vessels are inefficient resulting in a slower tumour re-growth rate.

Assessing response to targeted therapies with the internationally accepted response evaluation criteria in solid tumours version 1.1 (RECIST 1.1) has been challenging in this setting. With RECIST 1.1 percentage changes in the sum of maximal unidirectional measurements of target visceral or short axis nodal metastatic lesions over time are used to categorise treatment response, disease stability or progression [16]. However targeted therapies do not necessarily lead to a concomitant size reduction [15, 17]. Indeed immunotherapies such as ipilimumab and pembrolizumab may also initially increase lesion size, in up to 15% of cases during successful therapy ('pseudoprogression') [18]. This may be due to the accumulation of inflammatory infiltrates secondary to the augmented immune response [19]. One such study of Pembrolizumab in 411 patients treated for metastatic melanoma found that 12% of patients demonstrated an initial increase in metastatic lesions that would have led to a classification of progressive disease by RECIST 1.1 despite a decline in overall tumour burden over time [20, 21]. In order to prevent premature cessation of efficacious treatment and conversely continued treatment with ineffective treatment there is a need to improve imaging response assessment. An example of preliminary work is the incorporation of changes in tumour density (Hounsfield unit attenuation) measured on contrast enhanced computed tomography (CT) with size change [22, 23] and immune response criteria [20].

We propose that in vivo imaging targeted at the mode of drug action, its downstream effects, and a better understanding of the mechanisms underlying tumour response and resistance will enable imaging to provide a better indication of therapeutic effect. Hybrid positron emission tomography/magnetic resonance imaging (PET/MRI) scanners enables PET tracers such as the glucose

analogue fluorine 18 ( $^{18}\text{F}$ ) fluorodeoxyglucose (FDG) to be combined with multi-parametric MRI including multi-phasic contrast enhanced and diffusion weighted sequences. Preliminary studies of  $^{18}\text{F}$ -FDG PET alone [24–30] or MRI alone [31–34] have suggested a role for these modalities as response biomarkers.  $^{18}\text{F}$ -FDG PET has a high sensitivity and specificity for extra-renal lesions with a sensitivity and specificity of up to 84% and 91% in detecting metastases, which appear hypermetabolic and a Phase II study of 44 patients has shown that reduction in the FDG metabolic activity and tumour size is associated with overall and progression free survival [24]. A high baseline FDG standardised uptake value (SUV) also correlates with disease aggressiveness [26, 35, 36].

The REMAP study will examine whether the performance of integrated FDG-PET/MRI is better than standard of care imaging for response categorisation in metastatic RCC patients undergoing targeted therapy. We hypothesise that integrated  $^{18}\text{F}$ -FDG PET/MRI combining anatomic, metabolic and physiological imaging will be able to detect response/resistance ahead of size change allowing non-responding patients to transition to alternative therapies more swiftly. An integrated whole body technique will also allow for the heterogeneity of response to be explored within and between lesions, building on existing work [37]. PET/MRI will also facilitate the assessment of potential effects of therapy e.g. angiogenesis inhibition or immune modulation on normal organ microvasculature, which underlie treatment co-morbidities, e.g. hypertension as suggested in our previous work [38].

## Methods/design

### Study design

The REMAP study is an investigator initiated single centre observational study. All participants will have to provide written informed consent, signed and dated before inclusion in the study. The study is registered on the NIHR CRN portfolio ISRCTN12114913.

### Study organisation

The sponsor is King's College London and Guy's & St Thomas' Hospitals NHS Trust, London. The study is funded by Cancer Research UK (CRUK award reference C42827/A20000) and will be carried out at the King's College London and Guy's and St Thomas' PET Centre, London.

### Ethical approval

The final protocol has been approved by the Southeast London Research Ethics Committee (ref: 16/LO/1499) and approved by the Administration of Radioactive Substances Advisory Committee of the Department of Health (ARSAC), UK.

### Study population

Thirty eight patients with proven metastatic renal cell carcinoma will be recruited into the study. Patient inclusion and exclusion criteria are summarised in Table 1. A staging CT is required. Study entry will be restricted to patients in whom there is at least one lesion 2 cm or greater in size in order to minimise partial volume effects in  $^{18}\text{F}$ -FDG PET/MRI.

### Study objectives & endpoints

The primary objective of the REMAP study is to compare integrated  $^{18}\text{F}$ -FDG PET/MRI with CT for response categorisation at 12 weeks and 24 weeks on treatment and to assess the sensitivity and specificity of integrated  $^{18}\text{F}$ -FDG PET/MRI metrics to predict for disease progression after 12 and 24 weeks on treatment (PET: FDG standardised uptake value ( $\text{SUL}_{\text{peak}}$ ); MRI: diffusion MRI apparent diffusion coefficient (ADC) and post-gadolinium contrast agent normalised tumour signal intensity ( $\text{SI}_{\text{norm}}$ ), (alone or in combination).

Secondary objectives are; 1) to compare  $^{18}\text{F}$ -FDG PET/MRI response categorisation versus RECIST 1.1 and exploratory combined size & enhancement criteria (e.g. Choi, modified Choi and MASS [39–41]); 2) to assess if whole body tumour burden is better than target lesions only for response categorisation (RECIST 1.1); 3) to assess and quantify the inter-lesional heterogeneity in responding/non-responding lesions by texture analysis and 4) to explore whether there is a consistent effect of therapy on normal organ physiology e.g. kidney, liver, spleen.

The primary endpoint is the number of responders/non-responders on  $^{18}\text{F}$ -FDG PET/MRI versus standard CT at 12 and 24 weeks and a consensus reference standard based on all patient information up to 36 weeks. Time to progression and progression free survival beyond 36 weeks will also be recorded in order to determine if  $^{18}\text{F}$ -FDG PET/MRI metrics can predict for disease progression.

**Table 1** Patient recruitment

Inclusion criteria
1. Adults (>18 years) capable of providing informed consent with metastatic renal cell cancer
2. Eastern cooperative oncology group (ECOG) performance status $\leq 2$
Exclusion criteria
1. Estimated prognosis < 12 weeks
2. Contraindications to contrast enhanced CT, MRI or FDG/PET
3. Women who are pregnant or lactating

### Imaging

#### Computed tomography (CT)

Contrast enhanced CT of the thorax, abdomen and pelvis (100–120kVp, dose modulated mA, matrix  $512 \times 512$ , field of view 35 cm,  $\leq 5$  mm reconstructed slice thickness, following intravenous administration of 100 ml of  $\geq 300$  mg/ml iodinated contrast agent at 3 mL/s) will be performed as part of the patient's standard clinical care at baseline and 12, 24 and 36 weeks  $\pm 21$  days post-commencement of systemic therapy.

#### $^{18}\text{F}$ FDG-pet/MRI

Up to 400 MBq of  $^{18}\text{F}$ -FDG will be administered intravenously. Following a  $60 \pm 5$  min uptake period simultaneous  $^{18}\text{F}$ -FDG PET/MRI will be undertaken.  $^{18}\text{F}$ -FDG PET with a 2-point Dixon based segmentation technique utilised for attenuation correction, T1-weighted, T2-weighted, diffusion weighted (b-values: 50, 900  $\text{s}/\text{mm}^2$ ) and multiphase post contrast T1-weighted sequences (arterial, portal venous and equilibrium) following intravenous administration of gadolinium (0.1 mmol/kg) will be obtained from vertex to mid-thigh.  $^{18}\text{F}$ -FDG PET/MRI will be performed within 2 weeks of the standard CT scans. Each  $^{18}\text{F}$ -FDG PET/MRI will incur a maximal estimated radiation dose of 7.3mSV compared to a maximal estimated 19mSV per CT of the thorax, abdomen and pelvis.

### Categorisation of response

#### RECIST 1.1

Categorisation of response, disease stability or disease progression will be by RECIST 1.1 at 12, 24 and 36 weeks for target and non-target lesions. This is summarised in Table 2. This will be performed for each CT.

#### Size & enhancement criteria

Categorisation of response, disease stability or disease progression will be by Choi, modified Choi (mCHOI) and MASS criteria at 12, 24 and 36 weeks for target and non-target lesions. This is summarised in Table 2. This will be performed for each CT.

#### $^{18}\text{F}$ FDG-PET/MRI metrics

Categorisation of response, disease stability or disease progression using  $^{18}\text{F}$ -FDG PET/MRI metrics are summarised in Table 3. For  $^{18}\text{F}$ -FDG PET alone this is as per PERCIST [42]. A measurable target lesion is defined as the single tumour lesion with highest uptake value.  $\text{SUL}_{\text{peak}}$  (maximal 1.2-cm diameter volume ROI in tumour) has to be at least 1.5-fold greater than liver  $\text{SUL}_{\text{mean}}$  in a 3-cm diameter ROI in normal right lobe of liver (or 2-fold greater than the  $\text{SUL}_{\text{mean}}$  of blood pool in 1-cm-diameter ROI in the descending thoracic aorta extended over 2-cm z-axis if the liver is abnormal).

**Table 2** Response assessment criteria

	RECIST	CHOI	mCHOI	MASS
Progressive disease (MASS unfavourable response)	Increase in sum of longest target lesion diameters >20%. or Development of new lesions. or Unequivocal non-target lesion progression.	Increase in lesion size <sup>a</sup> > 10%. or Development of new lesions. or New or enlarging intratumoral nodule.	Increase in lesion size <sup>a</sup> > 10%. or Development of new lesions. or New or enlarging intratumoral nodule.	Increase in lesion size <sup>a</sup> > 20% without central necrosis. or Development of new lesions. or New intratumoral enhancing components.
Partial response (MASS favourable response)	>30% decrease in sum of longest target lesion diameters.	Decrease in target lesion CT enhancement (Hounsfield units) >15% or size >10%	Decrease in target lesion CT enhancement (Hounsfield units) >15% and size >10%	Decrease in lesion size >20%, central necrosis or reduction in attenuation >40 Hounsfield units
Complete response	Disappearance of all target lesions and resolution of lymphadenopathy (<10 mm).	Disappearance of all target lesions	Disappearance of all target lesions	Disappearance of all target lesions
Stable disease (MASS indeterminate response)	None of the above	None of the above	None of the above	None of the above

<sup>a</sup>Lesion size refers to the sum of the longest diameter of up to 10 target lesions (two per organ)

**Reference standard for response categorisation:**

Disease status (PD/non-PD, per patient and per lesion) by consensus will be confirmed using clinical criteria and all conventional imaging up to 36 weeks on treatment. The time-point of PD up to 36 weeks defined by consensus will be recorded. This time point is based on previous data (Median TTP: 336 days [37]).

Additionally computational methods for predicting response/non-response will be developed using two complementary approaches: a) state-of-the-art machine learning models, e.g. boosting and support vector machines based on customised kernel functions; b) novel “deep” neural networks architectures that are capable of automatically extracting predictive features in a completely data-driven manner.

**Sample size and analysis**

This is a feasibility study with the sample size ( $n = 38$ ) based on estimating parameters needed to design a future efficacy study. Parameters estimated from this feasibility study will be (i) the sensitivity and specificity of <sup>18</sup>F–FDG PET/MRI (new test) to detect progressive disease after 12 & 24 weeks on treatment; (ii) the difference in sensitivity and correlation of <sup>18</sup>F–FDG PET/MRI compared to CT RECIST (standard test). Additional assumptions tested will be the prevalence of disease progression and the best timepoint for detection of disease progression. The sample size of 38 patients, 19 with disease progression, will allow for an estimation of sensitivity of <sup>18</sup>F–FDG PET/MRI with a 95% confidence intervals lower limit precision of within 20%. The

**Table 3** PET/MRI response categorisation

Category/Parameter	Complete Response (CR)	Partial Response (PR)	Stable Disease (SD)	Progressive Disease (PD)
<sup>18</sup> F FDG PET SUL <sub>peak</sub>	Resolution of target lesion activity: activity less than mean liver activity & indistinguishable from background blood-pool levels. Disappearance of all other lesions to background blood-pool levels.	≥30% reduction of target lesion SUL <sub>peak</sub> . Absolute decrease ≥0.8 SUL units. Measurement is commonly in same lesion as baseline but can be another lesion if this is now the most active lesion after treatment.	Does not fulfil criteria for response or progression	>30% increase of target lesion SUL <sub>peak</sub> . New <sup>18</sup> F FDG avid lesions.
DW-MRI ADC <sub>50–900</sub>	Resolution of DWI signal	Persistence of DWI signal; >30% increase in ADC <sub>mean</sub>	Does not fulfil criteria for response or progression	Persistence of DWI signal; >25% reduction in ADC <sub>mean</sub>
DCE-MRI S <sub>I</sub> <sub>normalised</sub>	Resolution of enhancement	Persistence of enhancement; >40% decrease in S <sub>I</sub> <sub>norm</sub>	Does not fulfil criteria for response or progression	Persistence of enhancement; >40% increase in S <sub>I</sub> <sub>norm</sub>

expectation is that 95% of patients from the same clinical population will have a sensitivity within these 95% confidence intervals (CI). The assumptions for this feasibility study are a prevalence of patients with PD of 50%;  $^{18}\text{F}$ -FDG PET/MRI 80% sensitivity per patient for PD; and 10% loss to follow up. Sensitivity and specificity per patient will be compared using paired comparison of proportions of (i)  $^{18}\text{F}$ -FDG PET/MRI & (ii) CT RECIST to detect PD.

## Discussion

Accurate and timely response assessment in metastatic RCC is important to facilitate changes in treatment, in particular discontinuing non-efficacious, costly treatment that may be associated with toxicity. It is well known that conventional response assessment based on size does not best reflect the clinical effectiveness of cytostatic targeted therapies as size changes lag behind actual response and relapse in the majority of cases [15]. Assessment of the downstream effects of therapy on tumour vascularisation, glucose metabolism and water diffusion with integrated hybrid imaging potentially provides a more personalised approach to therapeutic evaluation.

It is well known that tumour vascularisation is heterogeneous. During growth tumours either co-opt a vascular supply from adjacent normal vessels, incite new vessel growth *de novo* (vasculogenesis), or from existing vasculature (angiogenesis) [43, 44]. The resultant tumour vessel architecture is disorganised and dysfunctional. Areas of adequate or hyperperfusion may co-exist with areas of hypoperfusion or high permeability (leading to increased intra-lesional interstitial fluid pressure and hypoxia). This variation in haemodynamic status will influence therapy delivery and its effectiveness [43]. Assessment of CT Hounsfield units (enhancement characteristics) in addition to size has already been performed to augment response assessment [15]. Several varying response patterns have been described in the literature ranging from a correlative reduction in tumour CT density (enhancement) and size to a reduction in tumour CT density with stabilisation of disease, or conversely minimal change in tumour CT density with at best disease stabilisation or progression [15].

There is little specific data of FDG PET for response assessment in metastatic RCC [45] but small studies (10–30 patients) have found that FDG PET metabolic response may occur within 1 cycle of therapy [46] and possibly as early as 2 weeks into treatment [47] with sunitinib or sorafenib as first or second line therapy.

There is also evidence of a strong correlation between the number and  $^{18}\text{F}$ -FDG avidity of lesions and overall survival in patients on targeted therapy [24]. One study examined 243 metastatic lesions in 26 patients and demonstrated a significantly worse median survival time amongst patients in whom the maximum SUV of the

primary tumour was  $>8.8$  [48]. A subsequent larger study involving 60 patients also showed a higher mortality of 62.5% in those patients in whom the maximum SUV of the primary was  $>10$  versus 33.3% in cases where the maximum SUV measured 3–5.

Diffusion weighted MRI may also provide relevant biological information. Investigators have demonstrated that a positive correlation exists between primary tumour grade and ADC values in a group of 33 patients; there was a statistically significant downward trend in the ADC value of lesions as grade increased [49]. A further study of 47 patients with metastatic renal cell carcinoma did not find baseline whole tumour mean ADC to be a predictor of outcome prior to the commencement of targeted therapy but there was a positive correlation between overall survival and the proportion of tissue within the tumour below the 25th percentile point of the cumulative ADC histogram [33]. It has also been shown that diffusion weighted imaging and multiphasic contrast enhanced MRI signal intensity may alter in response to treatment in renal cell cancer [33].

There are few data correlating imaging with mechanisms of relapse. A number of potential mechanisms underlying varying responses have been proposed with preclinical studies demonstrating an up-regulation of the production of the pro-angiogenic cytokine IL-8 associated with the development of sunitinib resistance, the same study found that the tumours in murine models were subsequently re-sensitised to sunitinib following the administration of an IL-8 neutralising antibody and began to respond to therapy despite previous failure [50]. Another potential factor in the development of drug resistance is the upregulation of hypoxia inducible factor 1-alpha (HIF-1a) in response to the hypoxic microenvironment induced by anti-angiogenic therapy. The presence of HIF-1a can lead to upregulation of expression of the RTK MET genes leading to potentiation of the MAPK tumorigenesis pathways [51].

It is clear that further research is needed to add to the body of evidence supporting alternative imaging biomarkers of treatment response/non-response/relapse in this arena for which PET/MRI is ideally suited. Simultaneous acquisition of data relating to tumour metabolic activity, perfusion and diffusion in a single, streamlined, integrative examination will provide a more representative and comprehensive picture of underlying biological mechanisms of therapy. Data from this pilot study will also provide the necessary initial evidence to power a future multicentre study. This study will also explore the quantitation of heterogeneity of therapy response both within and between metastases and provide preliminary data for computational methods that are capable of automatically extracting predictive features in a completely data-driven manner.

## Conclusion

In conclusion, the REMAP study will provide initial evidence for the sensitivity and specificity of  $^{18}\text{F}$ -FDG PET/MRI to detect disease response/non-response in metastatic renal cell cancer treated with targeted therapies, and how its performance in response categorisation compares to standard CT RECIST 1.1.

## Abbreviation

ADC: Apparent diffusion coefficient; ARSAC: Administration of Radioactive Substances Advisory Committee; CR: Complete Response; CT: Computed Tomography; DCE: Dynamic contrast enhanced; DWI: Diffusion weighted imaging; DCE: Dynamic contrast enhancement; FDG: Fluorodeoxyglucose; GCP: Good Clinical Practice; Gd: Gadolinium; MRI: Magnetic Resonance Imaging; PD: Progressive Disease; PET: Positron Emission Tomography; PR: Partial Response; RECIST: Response evaluation criteria in solid tumours; rSI: Relative signal intensity; SD: Stable Disease; SUV / SUL: Standardised Uptake Value/Standardised Uptake value normalised to lean body mass; HIF-1 $\alpha$ : Hypoxia inducible factor 1-alpha; RTK MET: Receptor tyrosine kinase MET; MAPK: Mitogen activated protein kinase

## Acknowledgements

The authors wish to thank Cancer Research UK for the study funding. The granting body will not be involved in data collection or analysis. The authors acknowledge infrastructure financial support from the Department of Health via the National Institute of Health Research Biomedical Research Centre award to Guy's and St Thomas' NHS Foundation Trust in partnership with King's College London and King's College Hospital NHS Foundation Trust; and the Comprehensive Cancer Imaging Centre funded by the Cancer Research UK and Engineering and Physical Sciences Research Council in association with the Medical Research Council and Department of Health.

## Funding

The sponsor is King's College London and Guy's & St Thomas' Hospitals NHS Trust, London. The study is funded by Cancer Research UK (CRUK award reference C42827/A20000) and will be carried out at the King's College London and Guy's and St Thomas' PET Centre, London.

## Availability of data and materials

The datasets used and/or analysed during the current study will be available from the corresponding author on reasonable request.

## Authors' contributions

The principle investigator is VG who conceived the study. GC, GM, SR, PN, SM and CKM were also involved in study protocol design, research ethics approval submission and protocol development. Manuscript drafting, editing and approval was contributed to by all authors.

## Competing interests

The authors declare that they have no competing interests.

## Consent for publication

Not applicable.

## Ethics approval and consent to participate

The trial is approved by the Southeast London Research Ethics Committee reference 16/LO/1499 and registered on the NIHR clinical research network portfolio ISRCTN12114913. Informed written consent will be obtained from all participants.

## Publisher's Note

Springer Nature remains neutral with regard to jurisdictional claims in published maps and institutional affiliations.

## Author details

<sup>1</sup>Department of Cancer Imaging, King's College London Division of Imaging Sciences & Biomedical Engineering, St Thomas' Hospital, Westminster Bridge Road, London SE1 7EH, UK. <sup>2</sup>Department of Medical Oncology, Guy's Hospital, Great Maze Pond, London SE1 9RT, UK. <sup>3</sup>Department of Medical Oncology, Mount Vernon Cancer Centre, Rickmansworth Road, Northwood, Middlesex HA6 2RN, UK. <sup>4</sup>Birmingham Clinical Trials Unit, Institute of Applied Health Research, University of Birmingham, B15 2TT, Birmingham, UK. <sup>5</sup>Department of Biomedical Engineering, King's College London Division of Imaging Sciences & Biomedical Engineering, St Thomas' Hospital, Westminster Bridge Road, London SE1 7EH, UK.

Received: 19 December 2016 Accepted: 17 May 2017

Published online: 02 June 2017

## References

1. Cancer Research UK, "Cancer Research UK." [Online]. Available: <http://www.cancerresearchuk.org/health-professional/cancer-statistics/statistics-by-cancer-type/skin-cancer/survival>. Accessed 01 Nov 2015.
2. Howlader CK N, Noone AM, Krapcho M, Miller D, Bishop K, Altekruse SF, et al. "SEER Cancer Statistics Review, 1975–2013, National Cancer Institute. Bethesda, MD." [Online]. Available: [http://seer.cancer.gov/csr/1975\\_2013/](http://seer.cancer.gov/csr/1975_2013/).
3. Jonasch E, Gao J, Rathmell WK, "Renal cell carcinoma," *BMJ*, vol. 349, no. 9669, p. g4797, 2014.
4. Raman R, Vaena D. Immunotherapy in metastatic renal cell carcinoma. *Biomed Res Int*. 2015;1–8.
5. Motzer RJ. New perspectives on the treatment of metastatic renal cell carcinoma: an introduction and historical overview. *Oncologist*. 2011;16(Suppl 2):1–3.
6. Motzer RJ, Hutson TE, Tomczak P, Michaelson MD, Bukowski RM, Rixe O, et al. "Sunitinib versus Interferon Alfa in Metastatic Renal-Cell Carcinoma," *N. Engl. J. Med.*, vol. 356 (2), 2007.
7. Escudier B, Eisen T, Stadler WM, Szczylik C, Oudard S, Siebels M, et al. TARGET Study Group. Sunitinib in advanced clear-cell renal-cell carcinoma. *N Engl J Med*. 2007;356(2):125–34.
8. Motzer RJ, Hutson TE, Cella D, Reeves J, Hawkins R, Guo J, et al. Pazopanib versus sunitinib in metastatic renal-cell carcinoma. *N Engl J Med*. 2013;369(8):722–31.
9. Hudes MR, G, Carducci M, Tomczak P, Dutcher J, Figlin R, Kapoor A, et al. "Temozolomide, interferon alpha or both for advanced renal cell carcinoma", vol. 356, pp. 2271–2281, 2007.
10. Escudier B, Pluzanska A, Koralewski P, Ravaud A, Bracarda S, Szczylik C, et al. Bevacizumab plus interferon alfa-2a for treatment of metastatic renal cell carcinoma: a randomised, double-blind phase III trial. *Lancet*. 2016; 370(9605):2103–11.
11. Motzer RJ, Escudier B, Oudard S, Hutson TE, Porta C, Bracarda S, et al. Efficacy of everolimus in advanced renal cell carcinoma: a double-blind, randomised, placebo-controlled phase III trial. *Lancet*. 2008;372(9637):449–56.
12. Sternberg CN, Davis ID, Mardiak J, Szczylik C, Lee E, Wagstaff J, et al. Pazopanib in locally advanced or metastatic renal cell carcinoma: results of a randomized phase III trial. *J Clin Oncol*. Feb. 2010;28(6):1061–8.
13. Mattei J, Donalizio R, Silva D, Seht D, Molina WR, Kim FJ. Targeted therapy in metastatic renal carcinoma. *Cancer Lett*. 2014;343:156–60.
14. Motzer RJ, Escudier B, McDermott DF, George S, Hammers HJ, Srinivas S, et al. Nivolumab versus Everolimus in advanced renal-cell carcinoma. *N Engl J Med*. Nov. 2015;373(19):1803–13.
15. Vasudev NS, Goh V, Juttla JK, Thompson VL, Larkin JMG, Gore M, et al. Changes in tumour vessel density upon treatment with anti-angiogenic agents: relationship with response and resistance to therapy. *Br J Cancer*. 2013;109(5):1230–42.
16. Eisenhauer EAA, Therasse P, Bogaerts J, Schwartz LHH, Sargent D, Ford R, et al. New response evaluation criteria in solid tumours: revised RECIST guideline (version 1.1). *Eur J Cancer*. 2009;45(2):228–47.
17. Nathan PD, Vinayan A, Stott D, Juttla J, Goh V. CT response assessment combining reduction in both size and arterial phase density correlates with time to progression in metastatic renal cancer patients treated with targeted therapies. *Cancer Biol. Ther*. Jan. 2010;9(1):15–9.
18. Hodi FS, Hwu W-J, Kefford R, Weber JS, Daud A, Hamid O, et al. Evaluation of immune-related response criteria and RECIST v1.1 in patients with advanced melanoma treated with Pembrolizumab. *J Clin Oncol*. May 2016;34(13):1510–7.



19. V. L. Chiou and M. Burotto, "Pseudoprogression and immune-related response in solid tumors" *Journal of Clinical Oncology*. vol. 33, no. 31. American Society of Clinical Oncology, pp. 3541–3543, 01-Nov-2015.
20. Wolchok JD, Hoos A, O'Day S, Weber JS, Hamid O, Lebbé C, et al. Guidelines for the evaluation of immune therapy activity in solid tumors: immune-related response criteria. *Clin Cancer Res*. Dec. 2009;15(23):7412–20.
21. F. S. Hodi, A. Ribas, A. Daud, O. Hamid, C. Robert, R. Kefford, et al. "Evaluation of immune-related response criteria (irRC) in patients (pts) with advanced melanoma (MEL) treated with the anti-PD-1 monoclonal antibody MK-3475" ASCO Meet. Abstr. vol. 32, no. 15\_suppl. p. 3006-, 2014.
22. Choi H, Charnsangavej C, deCastro Faria S, Tamm EP, Benjamin RS, Johnson MM, et al. CT evaluation of the response of gastrointestinal stromal tumors after imatinib mesylate treatment: a quantitative analysis correlated with FDG PET findings. *Am J Roentgenol*. Dec. 2004;183(6):1619–28.
23. Folio LR, Turkbey EB, Steinberg SM, Apolo AB. Viable tumor volume: volume of interest within segmented metastatic lesions, a pilot study of proposed computed tomography response criteria for urothelial cancer. *Eur J Radiol*. 2015;84(9):1708–14.
24. Kayani I, Avril N, Bomanji J, Chowdhury S, Rockall A, Sahdev A, et al. Sequential FDG-PET/CT as a biomarker of response to sunitinib in metastatic clear cell renal cancer. *Clin Cancer Res*. 2011;17(18):6021–8.
25. Chen JL, Appelbaum DE, Kocherginsky M, Cowey CL, Rathmell WK, Mcdermott DF, et al. FDG-PET as a predictive biomarker for therapy with everolimus in metastatic renal cell cancer. *Cancer Med*. 2013;2(4):545–52.
26. Revheim ME, Winge-Main AK, Hagen G, Fjeld JG, Fosså SD, Lilleby W. Combined positron emission tomography/computed tomography in sunitinib therapy assessment of patients with metastatic renal cell carcinoma. *Clin Oncol (R Coll Radiol)*. Jun. 2011;23(5):339–43.
27. Aide N, Cappele O, Bottet P, Bensadoun H, Regeasse A, Comoz F, et al. Efficiency of [18F]FDG PET in characterising renal cancer and detecting distant metastases: a comparison with CT. *Eur J Nucl Med Mol Imaging*. Sep. 2003;30(9):1236–45.
28. Majhail NS, Urbain J-L, Albani JM, Kanvinde MH, Rice TW, Novick AC, et al. F-18 Fluorodeoxyglucose positron emission tomography in the evaluation of distant metastases from renal cell carcinoma. *J Clin Oncol*. Sep. 2003;21(21):3995–4000.
29. Flaherty KT, Rosen MA, Heitjan DF, Gallagher ML, Schwartz B, Schnall MD, et al. Pilot study of DCE-MRI to predict progression-free survival with sorafenib therapy in renal cell carcinoma. *Cancer Biol Ther*. Apr. 2008;7(4):496–501.
30. Hahn OM, Yang C, Medved M, Karczmar G, Kistner E, Karrison T, et al. Dynamic contrast-enhanced magnetic resonance imaging Pharmacodynamic biomarker study of Sorafenib in metastatic renal carcinoma. *J Clin Oncol*. Oct. 2008;26(28):4572–8.
31. Panebianco V, Iacovelli R, Barchetti F, Altavilla A, Forte V, Sciarra A, et al. Dynamic contrast-enhanced magnetic resonance imaging in the early evaluation of anti-angiogenic therapy in metastatic renal cell carcinoma. *Anticancer Res*. 2013;33(12):5663–6.
32. Taouli B, Thakur RK, Mannelli L, Babb JS, Kim S, Hecht EM, et al. Renal lesions: characterization with diffusion-weighted imaging versus contrast-enhanced MR imaging. *Radiology*. May 2009;251(2):398–407.
33. Bharwani N, Miquel ME, Powles T, Dilks P, Shawyer A, Sahdev A, et al. Diffusion-weighted and multiphase contrast-enhanced MRI as surrogate markers of response to neoadjuvant sunitinib in metastatic renal cell carcinoma. *Br J Cancer*. Feb. 2014;110(3):616–24.
34. M. A. Rosen M. D. Schnall, "Dynamic Contrast-Enhanced Magnetic Resonance Imaging for Assessing Tumor Vascularity and Vascular Effects of Targeted Therapies in Renal Cell Carcinoma" *Clin. Cancer Res*. vol. 13, no. 2, p. 770s–776s, Jan. 2007.
35. Ueno D, Yao M, Tateishi U, Minamimoto R, Makiyama K, Hayashi N, et al. Early assessment by FDG-PET/CT of patients with advanced renal cell carcinoma treated with tyrosine kinase inhibitors is predictive of disease course. *BMC Cancer*. 2012;12:162.
36. Minamimoto R, Nakaigawa N, Tateishi U, Suzuki A, Shizukuishi K, Kishida T, et al. Evaluation of response to Multikinase inhibitor in metastatic renal cell carcinoma by FDG PET/contrast-enhanced CT. *Clin Nucl Med*. Dec. 2010;35(12):918–23.
37. Goh V, Ganeshan B, Nathan P, Juttla JK, Vinayan A, Miles KA. Assessment of response to tyrosine kinase inhibitors in metastatic renal cell cancer: CT texture as a predictive biomarker. *Radiology*. Oct. 2011;261(1):165–71.
38. K. Yip, V. Goh, J. Gregory, I. Simcock, "The Acute Physiological Effects of the Vaso-Active Drug, L-NNA, a Nitric Oxide Synthase Inhibitor, on Renal and Tumour Perfusion in Human Subjects." *J. Cancer ...* vol. 2014, no. January, pp. 44–52, 2013.
39. Choi H, Charnsangavej C, Faria SC, Macapinlac HA, Burgess MA, Patel SR, et al. Correlation of computed tomography and positron emission tomography in patients with metastatic gastrointestinal stromal tumor treated at a single institution with imatinib mesylate: proposal of new computed tomography response criteria. *J Clin Oncol*. May 2007;25(13):1753–9.
40. Smith AD, Shah SN, Rini BI, Lieber ML, Remer EM. Morphology, attenuation, size, and structure (MASS) criteria: Assessing response and predicting clinical outcome in metastatic renal cell carcinoma on antiangiogenic targeted therapy. *Am J Roentgenol*. 2010;194(6):1470–8.
41. Benjamin RS, Choi H, Macapinlac HA, Burgess MA, Patel SR, Chen LL, et al. We should desist using RECIST, at least in GIST. *J Clin Oncol*. May 2007; 25(13):1760–4.
42. R. L. Wahl, H. Jacene, Y. Kasamon, M. A. Lodge, "From RECIST to PERCIST: Evolving Considerations for PET response criteria in solid tumors." *J. Nucl. Med*. vol. 50 Suppl 1, no. 5, p. 122S–50S, May 2009.
43. Jain RK. Normalization of tumor vasculature: an emerging concept in antiangiogenic therapy. *Science (80- )*. 2005;307(5706):58–62.
44. Jain RK. Antiangiogenesis strategies revisited: from starving tumors to alleviating hypoxia. *Cancer Cell*. Nov. 2014;26(5):605–22.
45. Caldarella C, Muoio B, Isgrò MA, Porfiri E, Treglia G, Giovannella L. The role of fluorine-18-fluorodeoxyglucose positron emission tomography in evaluating the response to tyrosine-kinase inhibitors in patients with metastatic primary renal cell carcinoma. *Radiol Oncol*. 2014;48(483):219–27.
46. Vercellino L, Bousquet G, Baillet G, Barré E, Mathieu O, Just P-A, et al. 18F-FDG PET/CT imaging for an early assessment of response to sunitinib in metastatic renal carcinoma: preliminary study. *Cancer Biother Radiopharm*. Feb. 2009;24(1):137–44.
47. Horn KP, Yap JT, Agarwal N, Morton KA, Kadmas DJ, Beardmore B, et al. FDG and FLT-PET for early measurement of response to 37.5 mg daily sunitinib therapy in metastatic renal cell carcinoma. *Cancer Imaging*. 2015;15:15.
48. Namura K, Minamimoto R, Yao M, Makiyama K, Murakami T, Sano F, Hayashi N, et al. "Impact of maximum standardized uptake value (SUV<sub>max</sub>) evaluated by 18-Fluoro-2-deoxy-D-glucose positron emission tomography/ computed tomography (18F-FDG-PET/CT) on survival for patients with advanced renal cell carcinoma: a preliminary report." *BMC Cancer* vol. 10, no. 1, p. 667, 2010.
49. Goyal A, Sharma R, Bhalla AS, Gamanagatti S, Seth A, Iyer VK, et al. Diffusion-weighted MRI in renal cell carcinoma: a surrogate marker for predicting nuclear grade and histological subtype. *Acta Radiol*. 2012;53(3):349–58.
50. Huang D, Ding Y, Zhou M, Rini BI, Petillo D, Qian CN, et al. Interleukin-8 mediates resistance to antiangiogenic agent sunitinib in renal cell carcinoma. *Cancer Res*. 2010;70(3):1063–71.
51. Pennacchietti S, Michieli P, Galluzzo M, Mazzzone M, Giordano S, Comoglio PM. Hypoxia promotes invasive growth by transcriptional activation of the met protooncogene. *Cancer Cell*. 2003;3(4):347–61.

Submit your next manuscript to BioMed Central and we will help you at every step:

- We accept pre-submission inquiries
- Our selector tool helps you to find the most relevant journal
- We provide round the clock customer support
- Convenient online submission
- Thorough peer review
- Inclusion in PubMed and all major indexing services
- Maximum visibility for your research

Submit your manuscript at  
[www.biomedcentral.com/submit](http://www.biomedcentral.com/submit)

