

Utility of surgeon-performed pre-operative ultrasound in the localisation of parathyroid adenomas

Thomas, Paul Rs; Beggs, Andrew D; Han, Thang S

DOI:

[10.1177/2048004019856949](https://doi.org/10.1177/2048004019856949)

License:

Creative Commons: Attribution-NonCommercial (CC BY-NC)

Document Version

Publisher's PDF, also known as Version of record

Citation for published version (Harvard):

Thomas, PR, Beggs, AD & Han, TS 2019, 'Utility of surgeon-performed pre-operative ultrasound in the localisation of parathyroid adenomas', *JRSM cardiovascular disease*, vol. 8.
<https://doi.org/10.1177/2048004019856949>

[Link to publication on Research at Birmingham portal](#)

Publisher Rights Statement:

Thomas, P. R., Beggs, A. D., & Han, T. S. (2019). Utility of surgeon-performed pre-operative ultrasound in the localisation of parathyroid adenomas. *JRSM Cardiovascular Disease*. <https://doi.org/10.1177/2048004019856949>

General rights

Unless a licence is specified above, all rights (including copyright and moral rights) in this document are retained by the authors and/or the copyright holders. The express permission of the copyright holder must be obtained for any use of this material other than for purposes permitted by law.

- Users may freely distribute the URL that is used to identify this publication.
- Users may download and/or print one copy of the publication from the University of Birmingham research portal for the purpose of private study or non-commercial research.
- User may use extracts from the document in line with the concept of 'fair dealing' under the Copyright, Designs and Patents Act 1988 (?)
- Users may not further distribute the material nor use it for the purposes of commercial gain.

Where a licence is displayed above, please note the terms and conditions of the licence govern your use of this document.

When citing, please reference the published version.

Take down policy

While the University of Birmingham exercises care and attention in making items available there are rare occasions when an item has been uploaded in error or has been deemed to be commercially or otherwise sensitive.

If you believe that this is the case for this document, please contact UBIRA@lists.bham.ac.uk providing details and we will remove access to the work immediately and investigate.

Utility of surgeon-performed pre-operative ultrasound in the localisation of parathyroid adenomas

JRSM Cardiovascular Disease

Volume 8: 1–7

© The Author(s) 2019

Article reuse guidelines:

sagepub.com/journals-permissions

DOI: 10.1177/2048004019856949

journals.sagepub.com/home/cvd

Paul RS Thomas¹, Andrew D Beggs^{2,3} and Thang S Han^{4,5} 

Abstract

Background: Primary hyperparathyroidism arising from parathyroid adenoma is one of the most common endocrine disorders treated by endocrine surgeons. The adenoma is commonly identified by imaging techniques. The present study evaluated the performance of a portable ultrasound machine (Sonosite MicroMaxx) operated by a surgeon, departmental ultrasound and ^{99m}Tc-sestamibi-SPECT/CT by a radiologist in the identification of parathyroid adenomas.

Methods: Patient case notes were retrieved from medical records and imaging from picture archiving and communication system over the period from 2006 to 2012. ^{99m}Tc-sestamibi-SPECT/CT and departmental ultrasound images were reported by a nuclear radiologist. The ability of each imaging technique in localising parathyroid adenomas was referenced against the actual adenomas identified from parathyroidectomy.

Results: With reference to the actual site of the lesion, surgeon-performed ultrasound accurately localised the site of the lesion in 30/33 (90.1%) of cases with a sensitivity of 86.7%, departmental ultrasound accurately localised the site of the lesion in 21/26 (80.1%) of cases with a sensitivity of 79.2%. In 6/75 patients where ^{99m}Tc-sestamibi-SPECT/CT did not localise the lesion, departmental ultrasound did not localise any lesions correctly, while surgeon-performed ultrasound successfully located the adenoma in three (50%) of these six patients. Patients whose parathyroid adenomas identified by the surgeon were more likely to have shorter length of stay in hospital: odds ratio = 0.53 (95% confidence interval = 0.30–0.92, $p = 0.025$).

Conclusions: Surgeon-performed ultrasound for immediately pre-operative localisation improves identification of parathyroid adenomas and reduces length of stay in hospital, lending support for the use of this technique by endocrine surgeons.

Keywords

Primary hyperparathyroidism, hypercalcaemia, radiography, ^{99m}Tc-sestamibi-SPECT/CT

Received 3 February 2019; Revised received 3 May 2019; accepted 13 May 2019

Introduction

Primary hyperparathyroidism, caused by a parathyroid adenoma secreting excessive amounts of parathyroid hormone (PTH), and thus hypercalcaemia, is one of the most common endocrine disorders seen by endocrine surgeons.¹ The estimated incidence of primary hyperparathyroidism is between 1 in 500 and 1 in 2000 people.² The underlying pathophysiology of the development of parathyroid adenomas remains unclear but certain genetic syndromes, such as multiple endocrine neoplasia type 1 and type 2 can cause primary

¹Department of Surgery, Epsom & St Helier Hospital NHS Trust, Surrey, UK

²Institute of Cancer & Genomic Sciences, University of Birmingham, Birmingham, UK

³Queen Elizabeth Hospital Birmingham, Birmingham, UK

⁴Department of Endocrinology, Ashford & St Peter's NHS Foundation Trust, Chertsey, UK

⁵Institute of Cardiovascular Research, Royal Holloway, University of London, Egham, UK

Corresponding author:

Paul RS Thomas, Epsom & St Helier Hospitals NHS Trust, Wrythe Lane, Carshalton, Surrey SM5 1AA, UK.

Email: paul.thomas11@nhs.net



hyperparathyroidism due to either parathyroid hyperplasia or a parathyroid adenoma.³

Conventional surgical techniques for excision and removal of parathyroid adenomas have relied on neck dissection,⁴ identification of all parathyroid glands and removal of those that appear to be adenomatous. This can be facilitated by the use of peri-operative frozen section to identify whether removed tissue is a parathyroid adenoma in cases of uncertainty. However, this can lead to over-enthusiastic removal of normal parathyroid tissue and consequential hypocalcaemia that requires lifelong treatment. This has led surgeons to search for methods that can precisely localise parathyroid tissue and consequently reduce the size of the neck incision leading to better cosmesis, reduced operative time and complications as well as improved patient satisfaction.⁵

Multiple pre-operative and peri-operative techniques have been used for identification of the presence and location of abnormal parathyroid tissue. Pre-operative investigations usually take the form of radiological investigations, and the three most common investigations are, in the order of utilisation, ^{99m}Tc-sestamibi scintigraphy,⁶ neck ultrasound⁷ and ¹¹C-methionine positron emission tomography.⁸ Combining ^{99m}Tc-sestamibi scintigraphy with single-photon emission computerised tomography (SPECT) camera and fused with computed tomography (CT) (^{99m}Tc-sestamibi SPECT/CT) increases the accuracy in anatomical localisation of parathyroid adenomas. Potential drawbacks with this system include the use of radioisotopes, slow scan time, poor anatomical localisation in the case of two glands in close proximity with each other and lack of availability of nuclear medicine departments in many hospitals.

This has led to the use of high-frequency ultrasound examination of the neck to identify parathyroid adenomas in B-mode images. Parathyroid adenomas can be seen as hypoechoic lesions situated posterior and either superior or inferior to the poles of the thyroid gland. Ultrasound has a number of advantages including the avoidance of ionising radiation, readily available in every hospital and accuracy in anatomical localisation.

A solution to the issue described above is to use of ^{99m}Tc-sestamibi SPECT/CT pre-operatively in all patients with peri-operative localisation of the parathyroid gland employing high-frequency ultrasound using a portable ultrasound machine.⁹ This allows precise localisation based on two imaging modalities as well as highly precise placement of the incision by the surgeon, minimising its size and reducing duration of operation. We have been performing this intervention since 2005 which enables us to perform a minimally invasive parathyroidectomy (MIP) and early discharge (within 23 h) in most patients.

In this study, we evaluated the performance of six years of a portable ultrasound machine operated by a surgeon compared to that by ^{99m}Tc-sestamibi-SPECT/CT or by ultrasound performed by a consultant radiologist.

Methods

Patients were reviewed retrospectively over the period from 2006 to 2012 as part of clinical audit. All patient case notes were retrieved from medical records and imaging from the picture archiving and communication system. All imaging was performed using standardised techniques. ^{99m}Tc-sestamibi scintigraphy utilises the gamma-emitting isotope Technetium-99m bound to the ligand methoxyisobutylisonitrile (MIBI) which is avidly taken up by the prolific oxyphil cells of parathyroid adenomas. Planar and SPECT images, acquired with static views of the neck and thorax to include the mediastinum, were taken at 10, 20 and 120 min. Reconstruction and co-registration planar images were taken with a CT scan and performed at the same visit.

Images were examined and reported by a consultant radiologist with an expertise in nuclear medicine. The diagnosis of parathyroid adenomas was based on early and delayed imaging and SPECT/CT to determine asymmetric foci of uptake in the thyroid bed region. Technetium-99m bound MIBI is taken up both by thyroid and parathyroid glands, but has a slower washout from the parathyroid, so on the later images the parathyroid becomes relatively more prominent than the thyroid, particularly the adenomas.

Departmental ultrasound was performed by the same consultant radiologist. Surgeon-performed ultrasound was carried out by a single operator (PRST) employing a portable ultrasound machine (Sonosite MicroMaxx, Soma Technology, Inc., Bloomfield, CT, USA) using a 5–10 MHz linear array transducer. Imaging was performed immediately prior to skin preparation with the patient positioned supine on the operating table, with a sand bag between the shoulder blades, the neck extended and head rested on a head ring. The neck was imaged both in the transverse and cranio-caudal plane to visualise parathyroid glands.

Site of parathyroid gland was recorded for ^{99m}Tc-sestamibi-SPECT/CT, departmental ultrasound scan and surgeon-performed ultrasound. If the adenoma was localised easily, an MIP was carried out. If the adenoma could not be visualised, or if at MIP the adenoma could not be found, an open exploration was performed. Frozen section was not routinely performed unless there was uncertainty about the diagnosis. All patients had ^{99m}Tc-sestamibi-SPECT/CT investigations and a proportion of these patients received

additional ultrasound scan performed by a radiologist or by an endocrine surgeon; therefore, the number of patients receiving ultrasound scan were smaller than those by ^{99m}Tc -sestamibi-SPECT/CT.

Histology reports were obtained from the electronic patient record (EPR) computer system and site of parathyroid gland and histology recorded. In the case of multiple parathyroid glands removed, all sites were recorded. Patients had serum PTH and Ca^{2+} measured six weeks after the operation, and the gland was said to have been successfully removed if serum Ca^{2+} /PTH levels were normalised.

Statistical analysis

Associations between investigative methods with the actual site of the lesion identified surgically (reference method) were assessed by Lin's correlation coefficient and accuracy of methods was tested by sensitivity and specificity. Logistic regression was conducted to (1) assess patient characteristics (age, sex, pre-operative Ca^{2+} and PTH levels and position of the parathyroid adenoma) that may influence the detection of parathyroid lesions and (2) examine the association of post-operative length of stay in hospital with parathyroid adenoma identified by surgeon-performed ultrasound, departmental ultrasound and by ^{99m}Tc -sestamibi-SPECT/CT. Analyses were conducted using STATA (StataCorp., 2015, Stata Statistical Software: Release 14, StataCorp LP, College Station, TX, US). The null hypothesis was rejected when $p < 0.05$.

Results

In the period January 2006–January 2011 a total of 75 patients (21 men and 54 women) underwent surgical neck exploration and parathyroidectomy. The median age of patients was 63 years (range 26–87). The median pre-operative calcium levels were 2.66 mmol/l (interquartile range = 2.53–2.79) and post-operative levels were 2.40 mmol/l (interquartile range = 2.24–2.45). The pre-operative PTH levels were 26.4 pmol/l (interquartile range = 14.5–72.85). Median length of stay in hospital was one day (interquartile range = 1–2 days) with 9/75 (12%) patients undergoing day-case parathyroidectomy.

A parathyroid adenoma lying posterior to the inferior pole of the left lobe of thyroid of a woman was identified by ultrasound scan (Figure 1) and by early and delayed phases of SPECT (Figure 2(a)) which is confirmed by fused ^{99m}Tc -sestamibi-SPECT/CT images (Figure 2(c) and (d)). Table 1 shows that ^{99m}Tc -sestamibi-SPECT/CT correctly identified 74% of those with parathyroid adenoma, while surgeon-performed ultrasound improved the identification further to 91%.

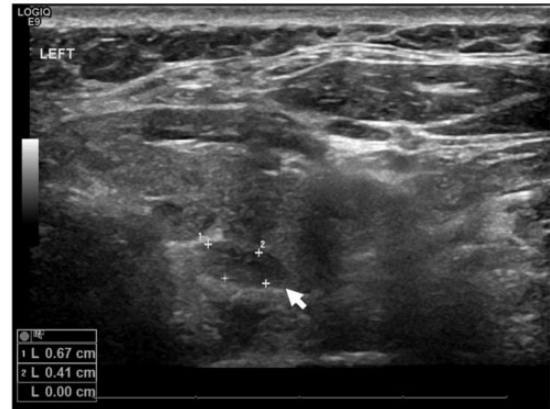


Figure 1. Parathyroid adenoma lying posterior to the inferior pole of left lobe of thyroid identified by ultrasound scan in a woman.

Both techniques had similar false positive rates. Department-performed ultrasound by a radiologist correctly identified 80% of those with parathyroid adenoma while incorrectly identified 15.4% of those without parathyroid adenoma as positive result. Surgeon-operated ultrasound did not result in any negative finding when the adenoma was present, while about 4% of patients with an adenoma were found to be negative by ^{99m}Tc -sestamibi-SPECT/CT or radiologist.

Table 2 shows that based on the data from ^{99m}Tc -sestamibi-SPECT/CT investigation, the majority of parathyroid adenomas were located inferiorly (46.5% right inferior and 38.0% left inferior) and more to the right (46.5% right inferior and 4.2% left inferior) than left (38.0% left inferior and 11.3% left superior) thyroid lobe. These numbers similarly occurred in ultrasound investigations.

The correlation between the actual site of the parathyroid adenoma identified by surgery and the site of the adenoma identified by ^{99m}Tc -sestamibi-SPECT/CT was 0.79 (95% confidence interval (CI) = 0.70–0.88), by surgeon-performed ultrasound was 0.87 (0.77–0.96) and by departmental ultrasound was 0.58 (0.30–0.85). ^{99m}Tc -sestamibi-SPECT/CT accurately localised the site of the lesion in 61/75 (81.3%) of cases with a sensitivity of 81.3%, while surgeon-performed ultrasound accurately localised the site of the lesion in 30/33 (90.1%) of cases with a sensitivity of 86.7% and the corresponding values for departmental-performed ultrasound were 21/26 (80.1%) and 79.2%, respectively.

In cases where ^{99m}Tc -sestamibi-SPECT/CT did not localise the lesion (6 out of 75 patients), surgeon-performed ultrasound correctly located the abnormal gland in three of them (50%). Departmental ultrasound did not identify any lesions that were not seen on ^{99m}Tc -sestamibi-SPECT/CT.

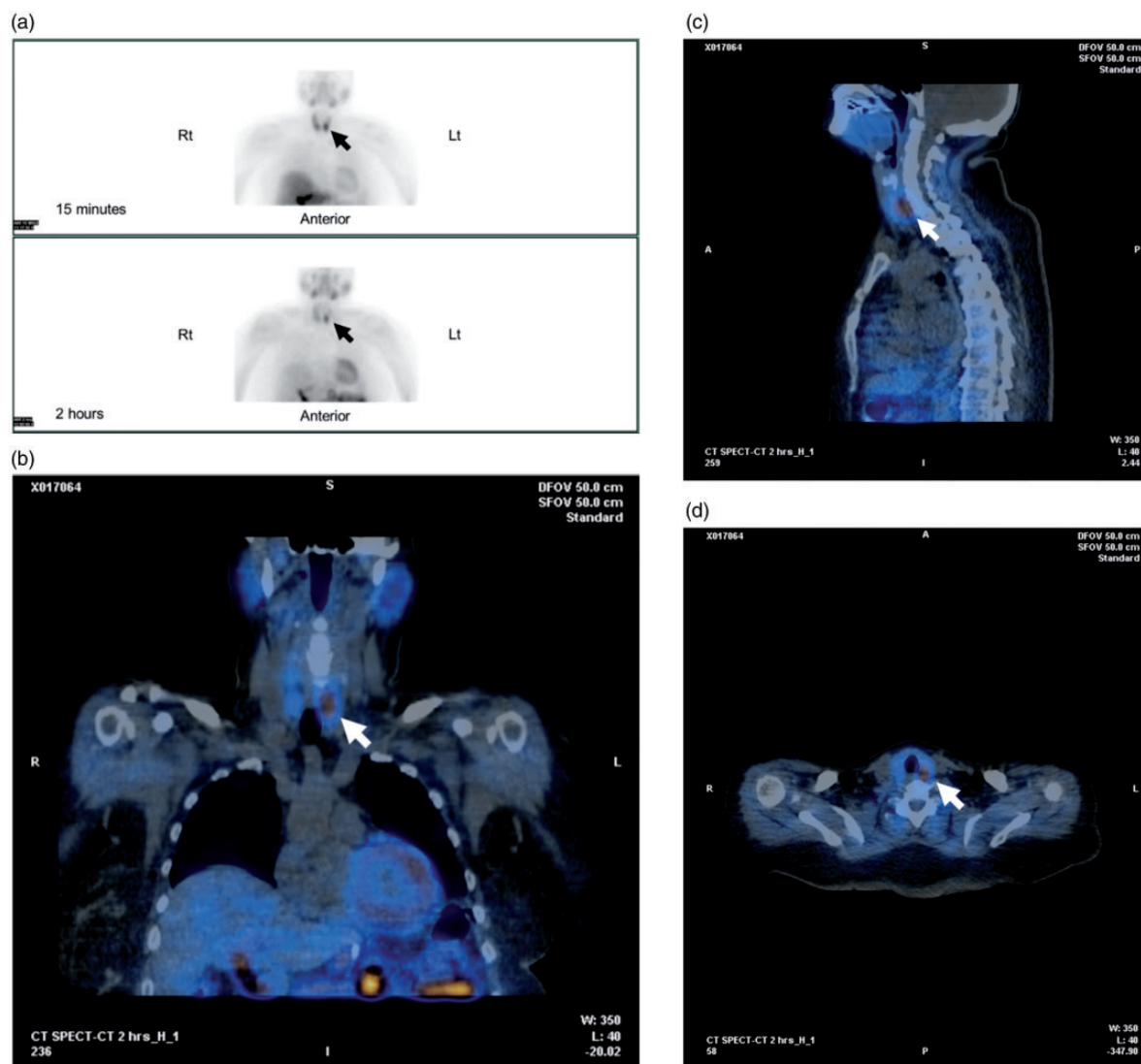


Figure 2. Anterior maximum intensity projection images from early (15 min) and delayed (2 h) phases of SPECT in the same woman undergoing ultrasound scan (Figure 1) showing delayed washout of radiotracer in the left inferior parathyroid adenoma (a). Delayed-phase coronal (b), sagittal (c) and axial (d) fused ^{99m}Tc -sestamibi-SPECT/CT images confirm this parathyroid adenoma localising posterior to the inferior pole of the left lobe of thyroid (c,d).

Table 1. Accuracy in the identification of parathyroid adenoma performed by different techniques.

	^{99m}Tc -sestamibi-SPECT/CT n = 74	Surgeon-performed ultrasound n = 33	Department-performed ultrasound n = 26
True positives	61 (74.0%)	30 (90.9%)	21 (80.8%)
False positives	10 (8.2%)	3 (9.1%)	4 (15.4%)
False negatives	3 (4.1%)	0	1 (3.8%)
True negatives	0	0	0

Univariable logistic regression (Table 3) showed that the age, pre-operative Ca^{2+} and PTH levels, sex and position of the lesion did not influence the identification of parathyroid adenoma by any of the three

techniques. Patients whose parathyroid adenomas identified by the surgeon were more likely to have shorter length of stay in hospital: unadjusted odds ratio (OR)=0.54 (95% CI=0.30–0.995, $p=0.035$).

Table 2. Comparison of site of lesion with scanning results for ^{99m}Tc -sestamibi-SPECT/CT, surgeon-performed ultrasound and department-performed ultrasound.

	Site of lesion				Total
	Left superior	Right superior	Left inferior	Right inferior	
^{99m}Tc -sestamibi-SPECT/CT					
Left superior	5 (7.0)	0	1 (1.4%)	0	6 (8.5%)
Right superior	0	2 (2.8%)	2 (2.8%)	2 (2.8%)	6 (8.5%)
Left inferior	3 (4.2)	0	23 (32.4)	0	26 (36.6%)
Right inferior	0	1 (1.4%)	1 (1.4%)	31 (43.7)	33 (46.5%)
Total	8 (11.3%)	3 (4.2%)	27 (38.0%)	33 (46.5%)	71 (100%)
Surgeon-performed ultrasound					
Left superior	2 (6.1%)	0	0	0	2 (6.1%)
Right superior	1 (3.0%)	2 (6.1%)	1 (3.0%)	1 (3.0%)	5 (15.2%)
Left inferior	0	0	10 (30.3%)	0	10 (30.3%)
Right inferior	0	0	1 (3.0%)	15 (45.5%)	16 (48.5%)
Total	3 (9.1%)	2 (6.1%)	12 (36.4%)	16 (48.5%)	33 (100%)
Department-performed ultrasound					
Left superior	2 (8.0%)	0	0	0	2 (8.0%)
Right superior	0	3 (12.0%)	1 (4.0%)	1 (4.0%)	5 (20.0%)
Left inferior	0	0	8 (32.0%)	1 (4.0%)	9 (36.0%)
Right inferior	1 (4.0%)	0	0	8 (32.0%)	9 (36.0%)
Total	3 (12.0%)	3 (12.0%)	9 (36.0%)	10 (40.0%)	25 (100%)

Table 3. Table of odds ratios, 95% confidence intervals and p-values for surgeon-performed ultrasound, department-performed ultrasound and ^{99m}Tc -sestamibi-SPECT/CT as determined by univariate logistic regression analysis.

Variable	Surgeon-performed ultrasound		Department-performed ultrasound		^{99m}Tc -sestamibi-SPECT/CT	
	OR (95% CI)	p	OR (95% CI)	p	OR (95% CI)	p
Length of stay in hospital	0.54 (0.30–0.96)	0.035	1.01 (0.68–1.51)	0.959	1.58 (0.50–4.92)	0.434
Pre-operative Ca^{++}	0.32 (0.02–4.15)	0.383	0.72 (0.06–8.22)	0.791	1.04 (0.03–39.0)	0.982
Post-operative Ca^{++}	9.40 (0.13–651)	0.300	9.57 (0.20–452)	0.251	0.50 (0.01–164)	0.814
PTH	0.98 (0.97–1.01)	0.167	0.99 (0.98–1.01)	0.898	1.01 (0.98–1.04)	0.514
Female (referent)	1	–	1	–	1	–
Male	0.22 (0.04–1.24)	0.087	0.44 (0.09–2.07)	0.297	1.31 (0.12–14.1)	0.825
Age	1.02 (0.97–1.07)	0.491	1.01 (0.97–1.06)	0.617	1.01 (0.94–1.09)	0.770
Left superior adenoma (referent)	1	–	1	–	1	–
Right superior adenoma	0.77 (0.02–27.6)	0.886	– ^a	–	0.02 (0.01–1.99)	0.089
Left inferior adenoma	1.40 (0.12–16.9)	0.788	1.18 (0.14–10.2)	0.881	0.48 (0.05–4.32)	0.514
Right inferior adenoma	0.42 (0.04–4.61)	0.478	0.78 (0.09–6.85)	0.819	1.24 (0.46–3.31)	0.666

PTH: parathyroid hormone; OR: odds ratio; CI: confidence interval.

^aNot enough data for analysis. Significant results are shown in bold.

This association continued to persist after confounding factors (age, sex, Ca^{2+} and PTH levels and site of parathyroid adenoma) were accounted for using multivariable model: adjusted OR = 0.53 (95% CI = 0.30–0.92, $p = 0.025$).

Discussion

We have demonstrated that surgeon-performed ultrasound in the immediate pre-operative period provides

additional identification of cases where ^{99m}Tc -sestamibi-SPECT/CT and departmental ultrasound did not localise the lesion. Patients whose parathyroid adenomas identified by surgeon were more likely to have shorter length of stay in hospital.

Findings of localisation of parathyroid adenoma by surgeon in our study are similar to those reported from previous studies. Soon et al.¹⁰ studied 87 cases and showed that peri-operative scan correctly localised 83% of patients, while the larger study by Untch

et al.¹¹ of 392 showed that scan in clinic setting correctly localised 87% of patients. Other studies have found similar results including those by van Ginhoven et al.¹² with reported accuracy of 85%. Solorzano et al.¹³ reported an accuracy of 67% in patients with non-localising ^{99m}Tc-sestamibi scans and Steward et al.¹⁴ reported a sensitivity of 87% by surgeon-performed scan and 58% by ^{99m}Tc-sestamibi. In a UK-based study, Aspinall et al.¹⁵ found that surgeon-performed ultrasound had an accuracy of 86% in detecting the position of parathyroid adenomas in outpatient clinics. It should be borne in mind that apart from its value in localising primary parathyroid adenomas, ^{99m}Tc-sestamibi-SPECT/CT is vital for identifying major parathyroid ectopias¹⁶ and parathyroid glands in secondary hyperparathyroidism.^{17,18} The present study found none of the patient had evidence of ectopic parathyroid glands.

There is considerable variability in the detection rates of adenomas when department ultrasound is performed by a radiologist. Sensitivity of 80.1% in our study is relatively higher than in other previously reported findings. Ultrasound scan technique is operator dependent but surgeons appears to perform better than radiologist which could be explained by factors such as experience of the surgeon who specialises in this area of expertise. Caution should be taken when interpreting our findings and should not be generalised to other populations since this study was conducted in a single centre and carried out by a single operator. Our surgeon operator (PRST) had a 100% repeatability record for ultrasound identification of parathyroid adenomas. We did not examine inter-observer variability for any of the modalities in the present study but a review by Wong et al.¹⁶ reported an inter-observer agreement of SPECT/CT to be high (κ value = 0.91). Another issue surrounds that of training; whereas training is available for surgeons to learn parathyroid ultrasonography in the US,¹⁹ there exists no such formal training programmes in the UK. Based on our findings and existing published results, formal training in parathyroid ultrasonography in the UK for surgeons specialising in parathyroid surgery would help improve standards in the identification of parathyroid adenomas. By necessity, a capital outlay associated with the set-up of this type of service would lead to savings in costs in terms of reduced negative exploration rates, more rapid recovery and reduction in use of unnecessary investigations.

The present study has its limitations in that the groups of patients examined by the three techniques were not the same; therefore, there might have been some differences in complexity of the patients' condition. However, we found patient characteristics including age, Ca²⁺ and PTH levels, and sex did not influence

the ability to locate abnormal parathyroid gland, with the exception of post-operative length of stay in hospital which was shorter for those whose parathyroid adenomas were identified by the surgeon. Other limitations from the present study include that certain patients did not undergo assessment by all three modalities, which is not ideal. However, this situation reflects clinical practice rather than research investigation; when a parathyroid adenoma is clearly identified by ^{99m}Tc-sestamibi-SPECT/CT, with strong support from biochemical investigations, it is justifiable not to subject patients to undergo further investigations. In a clinical setting, the surgeon also has access to previous results from department ultrasound and ^{99m}Tc-sestamibi-SPECT/CT (i.e. not blinded); therefore, there is a potential bias in favour of the surgeon in the identification of parathyroid adenomas.

Diagnostic criteria vary between centres which may have some bearing on our findings. We employed the commonly adopted technique based on delayed wash-out of Technetium-99m bound MIBI to identify parathyroid adenomas, which is principally a qualitative technique. Some authors have reported a semi-quantitative approach, based on the certainty of uptake foci, which is classified according to diagnostic confidence score from 1 to 4 (1 = definitely negative, 2 = doubtful but probably negative, 3 = probably positive, 4 = positive). Scores of 3 and 4 meet diagnostic criteria for parathyroid adenomas.²⁰

In conclusion, findings from our study indicate that surgeon-performed ultrasound for immediately pre-operative localisation improves identification of parathyroid adenomas and reduces length of stay in hospital, lending support for the use of this technique by endocrine surgeons.

Acknowledgements

We would like to thank the patients who underwent investigations and treatment of primary hyperparathyroidism in the present study and colleagues from the Department of Radiology, Epsom & St Helier Hospitals NHS Trust, who performed ^{99m}Tc-sestamibi-SPECT/CT and ultrasonography.

Contributorship

ADB and PRST co-wrote the first draft. ADB analysed the data. PRST and TSH edited the manuscript. All authors read and approved the final version of the manuscript.

Declaration of conflicting interests

The author(s) declared no potential conflicts of interest with respect to the research, authorship, and/or publication of this article.

Ethical approval

None.

Funding

The author(s) received no financial support for the research, authorship, and/or publication of this article.

Guarantor

PRST.

Provenance

Invited contribution.

ORCID iD

Thang S Han  <https://orcid.org/0000-0003-2570-0938>

References

- Rubin MR, Bilezikian JP, McMahon DJ, et al. The natural history of primary hyperparathyroidism with or without parathyroid surgery after 15 years. *J Clin Endocrinol Metab* 2008; 93: 3462–3470.
- Miller BS, Dimick J, Wainess R, et al. Age- and sex-related incidence of surgically treated primary hyperparathyroidism. *World J Surg* 2008; 32: 795–799.
- Brandi ML, Gagel RF, Angelini A, et al. Consensus: guidelines for diagnosis and therapy of MEN type 1 and type 2. *J Clin Endocrinol Metab* 2001; 86: 5658–5671.
- Bergenfels A, Lindblom P, Tibblin S, et al. Unilateral versus bilateral neck exploration for primary hyperparathyroidism: a prospective randomized controlled trial. *Ann Surg* 2002; 236: 543–551.
- Palazzo FF and Delbridge LW. Minimal-access/minimally invasive parathyroidectomy for primary hyperparathyroidism. *Surg Clin North Am* 2004; 84: 717–734.
- Glynn N, Lynn N, Donagh C, et al. The utility of ^{99m}Tc-sestamibi scintigraphy in the localisation of parathyroid adenomas in primary hyperparathyroidism. *Ir J Med Sci* 2011; 180: 191–194.
- Adler JT, Chen H, Schaefer S, et al. What is the added benefit of cervical ultrasound to ^{99m}Tc-sestamibi scanning in primary hyperparathyroidism? *Ann Surg Oncol* 2011; 18: 2907–2911.
- Beggs AD and Hain SF. Localization of parathyroid adenomas using ¹¹C-methionine positron emission tomography. *Nucl Med Commun* 2005; 26: 133–136.
- Arora S, Balash PR, Yoo J, et al. Benefits of surgeon-performed ultrasound for primary hyperparathyroidism. *Langenbecks Arch Surg* 2009; 394: 861–810.
- Soon PS, Delbridge LW, Sywak MS, et al. Surgeon performed ultrasound facilitates minimally invasive parathyroidectomy by the focused lateral mini-incision approach. *World J Surg* 2008; 32: 766–771.
- Untch BR, Adam MA, Scheri RP, et al. Surgeon-performed ultrasound is superior to ^{99m}Tc-sestamibi scanning to localize parathyroid adenomas in patients with primary hyperparathyroidism: results in 516 patients over 10 years. *J Am Coll Surg* 2011; 212: 522–529.
- van Ginhoven TM, Morks AN, Schepers T, et al. Surgeon-performed ultrasound as preoperative localization study in patients with primary hyperparathyroidism. *Eur Surg Res* 2011; 47: 70–74.
- Solorzano CC, Lee TM, Ramirez MC, et al. Surgeon-performed ultrasound improves localization of abnormal parathyroid glands. *Am Surg* 2005; 71: 557–562.
- Steward DL, Danielson GP, Afman CE, et al. Parathyroid adenoma localization: surgeon-performed ultrasound versus sestamibi. *Laryngoscope* 2006; 116: 1380–1384.
- Aspinall SR, Nicholson S, Bliss RD, et al. The impact of surgeon-based ultrasonography for parathyroid disease on a British endocrine surgical practice. *Annals* 2012; 94: 17–22.
- Wong KK, Fig LM, Youssef E, et al. Endocrine scintigraphy with hybrid SPECT/CT. *Endocr Rev* 2014; 35: 717–746.
- Zhen L, Li H, Liu X, et al. The application of SPECT/CT for preoperative planning in patients with secondary hyperparathyroidism. *Nucl Med Commun* 2013; 34: 439–444.
- Yang J, Hao R, Yuan L, et al. Value of dual-phase (^{99m}Tc-sestamibi scintigraphy with neck and thoracic SPECT/CT in secondary hyperparathyroidism. *Am J Roentgenol* 2014; 202: 180–184.
- Miller BS, Gauger PG, Broome JT, et al. An international perspective on ultrasound training and use for thyroid and parathyroid disease. *World J Surg* 2010; 34: 1157–1163.
- Asseeva P, Paladino NC, Guerin C, et al. Value of ¹²³I/^{99m}Tc-sestamibi parathyroid scintigraphy with subtraction SPECT/CT in primary hyperparathyroidism for directing minimally invasive parathyroidectomy. *Am J Surg* 2019; 217: 108–113.